

## Classification of Odontogenic cysts

### Developmental

### Inflammatory

- Primordial
- Gingival
- Odontogenic keratocyst
- Eruption

- Radicular cyst
- Residual cyst
- Paradental cyst

## Introduction

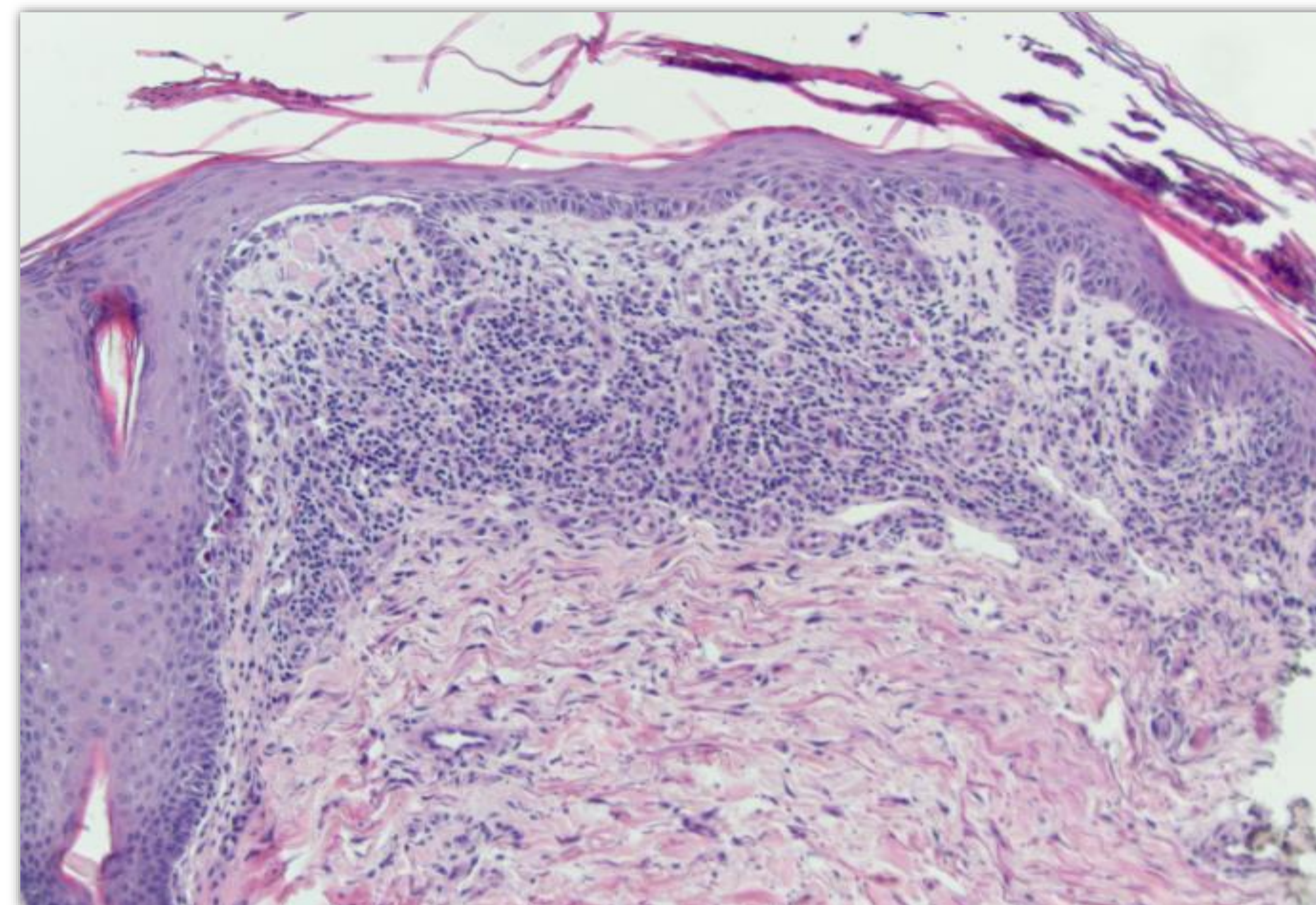
Eruption Cyst, or Eruption Hematoma, is a Bluish Swelling That Occurs on The Soft Tissue Over an Erupting Tooth. It is Usually Found in Children . The Fluid in The Cyst is Sometimes Clear Creating Pale-coloured Cyst although Often They are Blue. An Eruption cyst is a Developmental Soft-tissue cyst of odontogenic origin that forms over an erupting tooth

## Clinical features

- It is a soft Gingival swelling
- Age :- Children Below The Age Of 10
- Color :- Blue to Purplish – Brown color
- Cystic fluid contains blood hence the color appearance which is mostly seen due to surface trauma caused by opposing tooth to the lesion

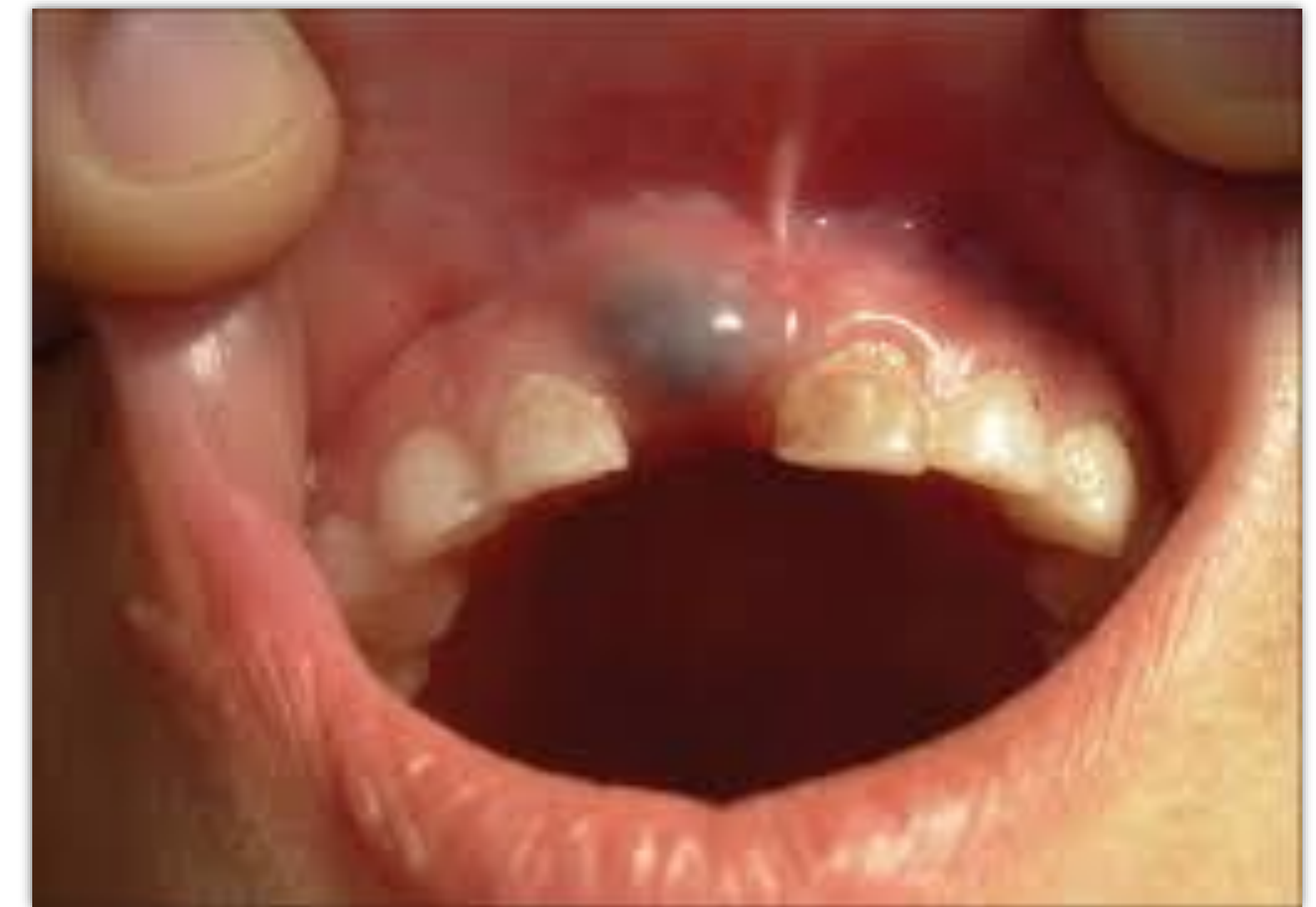## Histopathological features

- Epithelial lining (non - Keratinized stratified squamous epithelium)
- The fibrous capsule shows inflammatory cells
- The epithelial lining of the cyst is separated from the alveolar mucosa by a thin layer of fibrous tissue with the epithelial tags of cystic epithelium facing those of the alveolar mucosa.
- The cystic cavity may contain blood in addition to the yellowish protein fluid as a result of trauma



## Management

- The cyst roof may be removed to allow the tooth to erupt although most of them burst spontaneously
- Antibiotics if septic
- If Apical damage may require extraction



## Conclusion

Eruption cysts are benign cysts that appear on the mucosa of a tooth shortly before its eruption. They may disappear by themselves but if they hurt, bleed or are infected they may require surgical treatment to expose the tooth and drain the contents

## References

- Varun, K. (2014). Eruption Cyst or Hematoma Clinical Features, Diagnosis and Treatment. [online] Juniordentist.com. Available at: <http://www.juniordentist.com/eruption-cyst-or-hematoma-clinical-features-diagnosis-treatment.html>
- Dhawan, P., Kochhar, G. K., Chachra, S., & Advani, S. (2012). Eruption cysts: A series of two cases. Dental Research Journal, 9(5), 647–650.