

Breast CA

* RF

① FH

BRCA 1/2

+ Ovarian Tumor

② hormonal

nullipara

late pregnancy

replacement therapy

early menarch late menopause

hyperplasia

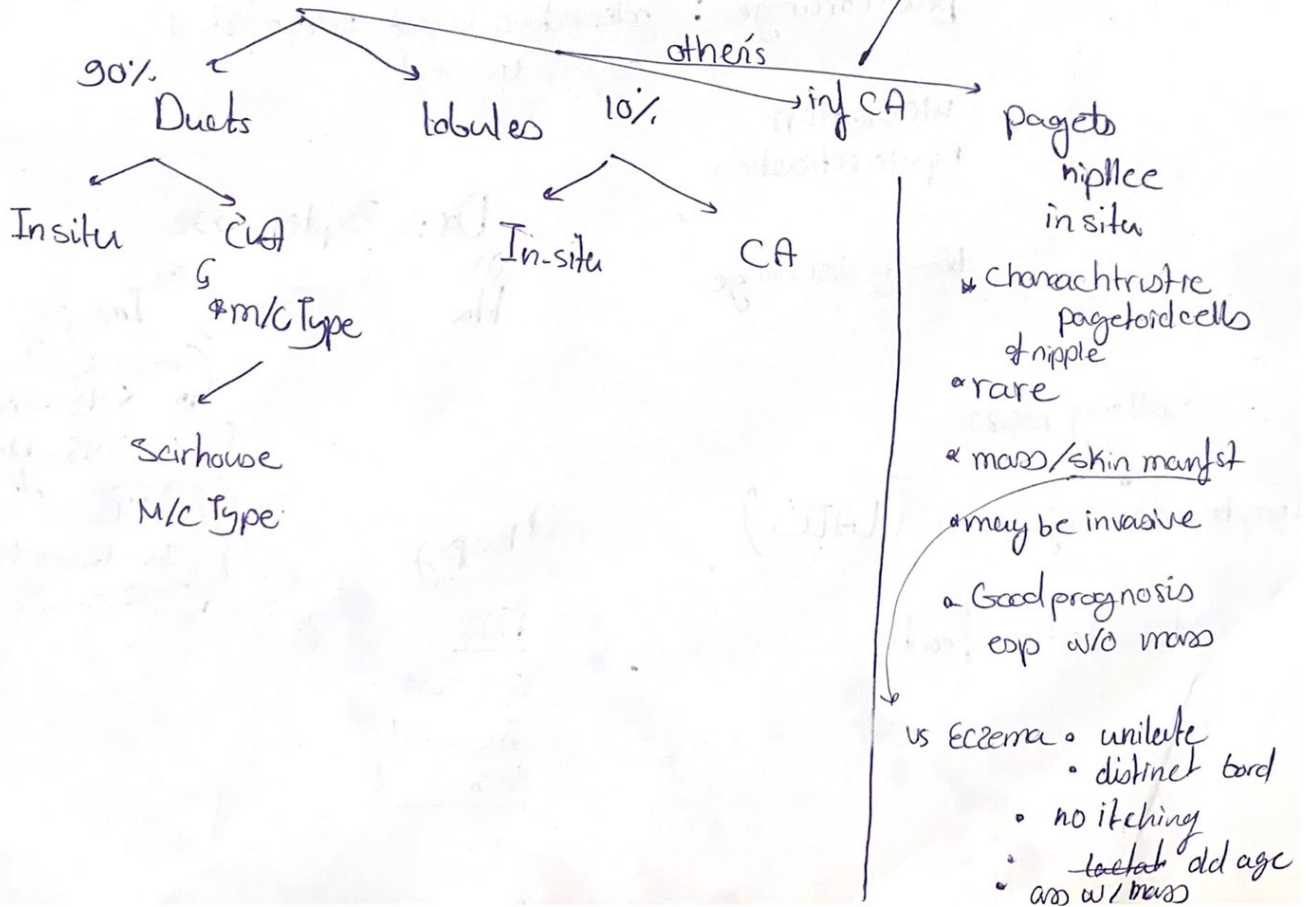
CA of contrabreast

Environmental

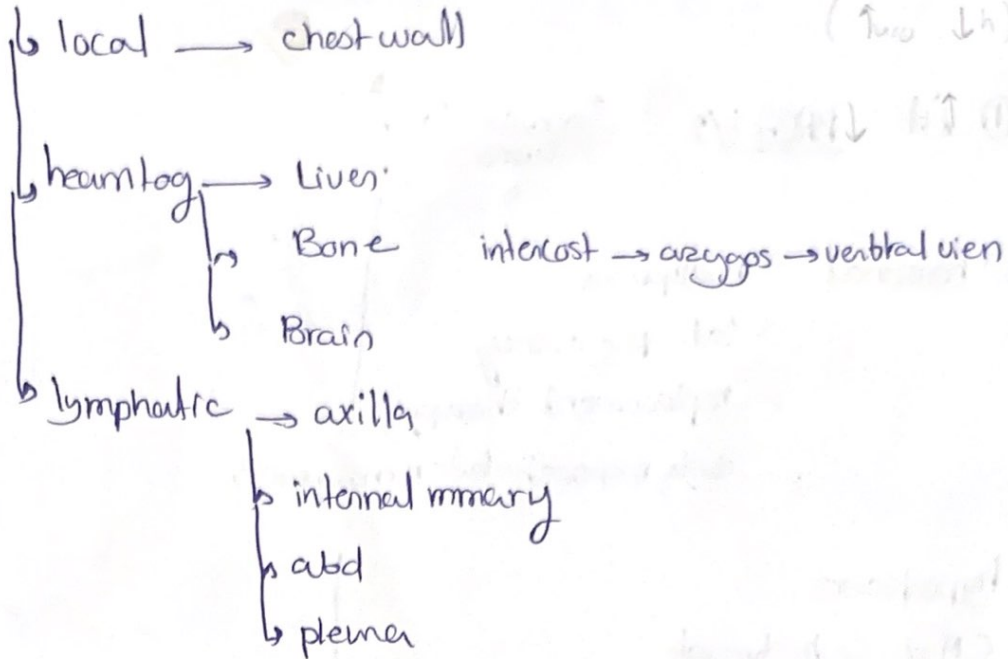
Smoking
Alcohol
N

- resemble acute mastitis
- most aggressive

Types



Spread



(↑ ↓) mainly
 ↓ ↑

c/p

palpable mass

80% upper
 outer }

skin changes

peu d'orange : edematous breast w/ retracted
 Cooper's ligament

ulceration
nipple retraction

bloody discharge

axillary mass

↓
 Lymphedema of arm (LATE)

Metastatic feat

Dx: Triple assess

- ① Hx
- ② Ex
- ③ Imaging
 - < 45 = USG
 - > 45 = Mamm
 - 45 no see b. dense tissue

④ Biopsy

- FNA
- Core cut
- Incisional
- Excisional

STAGE (TNM)

- X-ray
- PET
- CT

prog TMarker

T₀

T_{is}

T₁

T₂

T₃

T₄

N₀

M₀

N₁

M₁

N₂

M₂



Stage 1-4

palliative surgery

Tbx Mastectomy

① simple breast tissue + skin

② modified radical " " + LN 1+2

no longer done
 ③ Radical halsted " " + 1+2+3 + pect muscles

CI ④ Breast conservative: wide Excision of mass
 Tissue

① small breast, large T → Scm

② skin invol

③ mult centric Tumour

④ CT disease

Quadrantectomy

+ LN +/- if present/palpeble
 + post oper radiation → Mast

Sentinel node biopsy


injected Tumor w/ methylene blue

look for stained LN

6) Reconstruction of breast after removal

Silicone Implant

Flap harvest



biopsy

if neg-

don't LN } re
remove } LN