

Comprehensive treatment –Full Mouth Rehabilitation case

By: Aisha Abdulla

Roll No: 1001



This work was achieved by the student: Aisha Abdullha under the supervision of dental teaching staff at Libyan International Medical University:

Dr: Rafik M AlKowafi

Dr: Abdelmonem Abdelnabi.

Dr: Ali Bosnina .

Dr: Amal Alawamy .

Dr: Abdelsalam Elhdad

Dr: Nuha Elkadik .

Dr: Kadiga Elfallah.

Personal Data

Name : A.S.B.

Age : 49 years (30/05/1970).

Gender: Female.

Nationally : Egyptian.

Occupation : House wife.

Address : Alwhashy / Benghazi

Material & Society : Married.

Chief complaint & History of Chief complaint

Chief complaint :

“ I am not satisfied with my current smile” .

History of Chief complaint :

Bad smile due to poor restoration that carried out 5 years ago, also she note discolored upper anterior tooth and the other is fractured and she dose not remember the Couse, patient is not satisfied of her smile in term of discolored restoration, color of teeth and last is the fractured tooth.

Medical and Drug History:

- **Medical history** : diabetic patient since 2 years on metformin 500mg/day and last reading for HBA1c =11(NON CONTROLLED CASE) , F.B.G.=227mg/dl
- **Drug history** : METFORMIN
- **Allergic history** : N.O.S
- **Family history** : N.O.S

Dental history

O.H.P. : brushing her tooth once /daily ,soft tooth brush ,no specific tooth paste .

- ❖ Any other interdental cleaning aids: No
- ❖ Attitude towards dentistry: Fair
- ❖ Type of dental treatment:
 - **Previous restorative.**
 - **Endodontic .**
 - **Extractions without complication .**
 - **Prosthodontics .**
- Reasons for loss of teeth if any: **caries**



Extra-oral examinations

- **Symmetrical face**
- Ovoid form
- Competence lip , lower lip line .
- No Swelling .
- No scaring .

- **TMJ status** : Normal with Average Mouth opening
- ❖ **Lymph nodes** :Not palpable

Intraoral examination:

➤ **Soft Tissue :**

- Halitosis: Present.
- Gingiva:
- **Gingival recession.**
- Gingival enlargement.

16	11	26
—	2	—
—	2	2
46	31	36

$$D.I = 6/6 = 1$$

16	11	26
—	0	—
0	1	1
46	31	36

$$C.I = 2/6 = 0.3$$

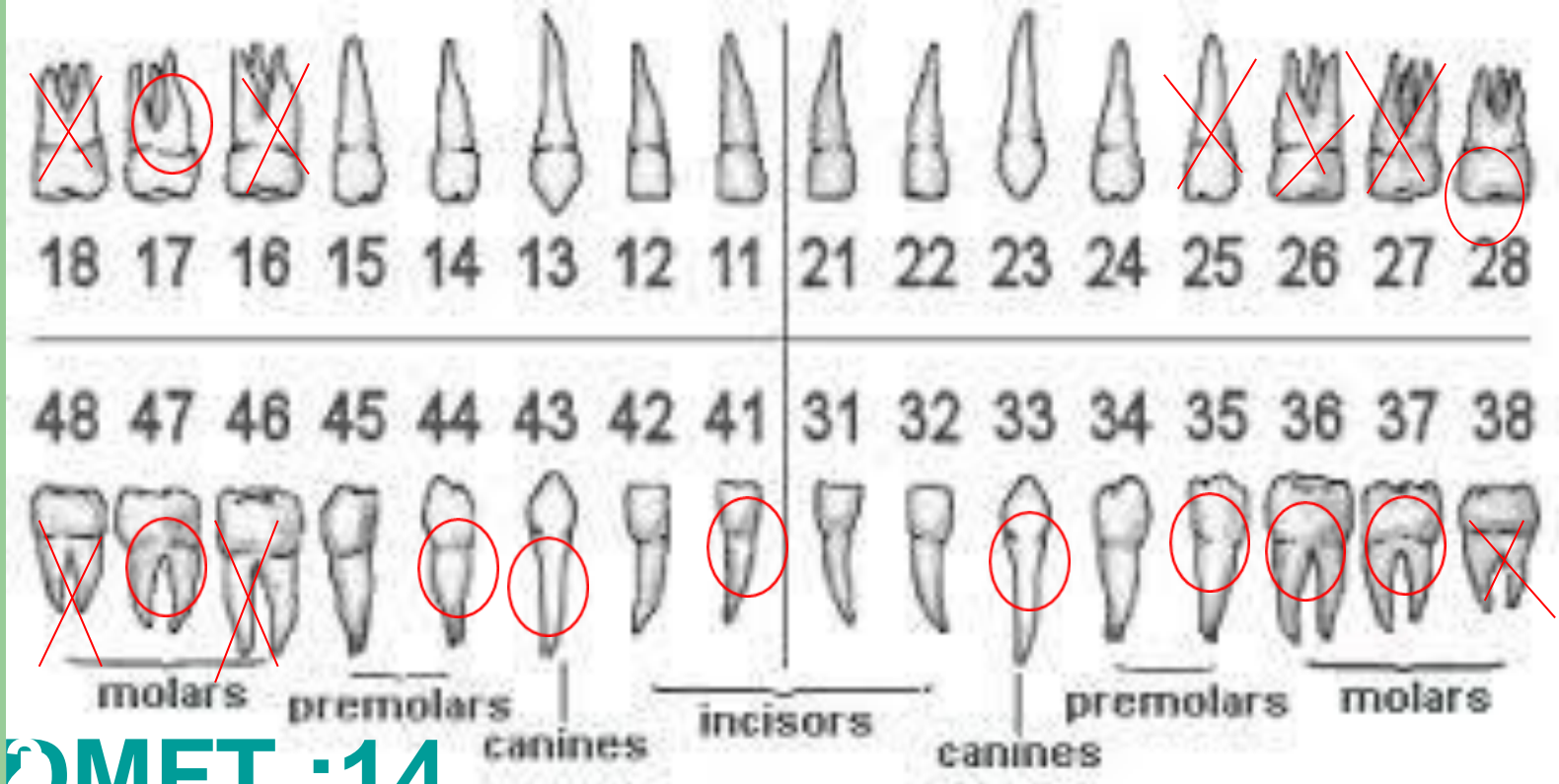
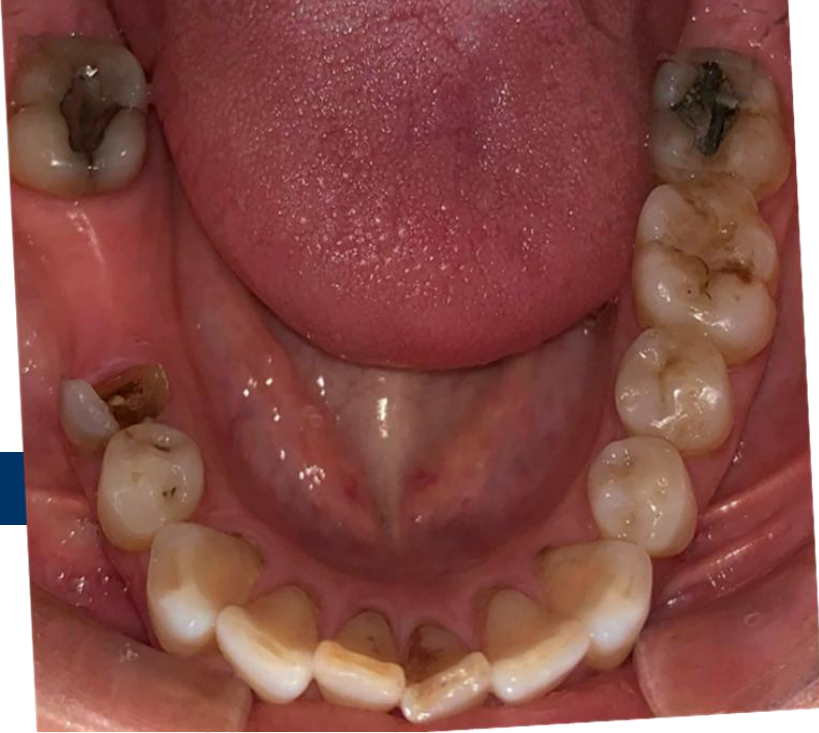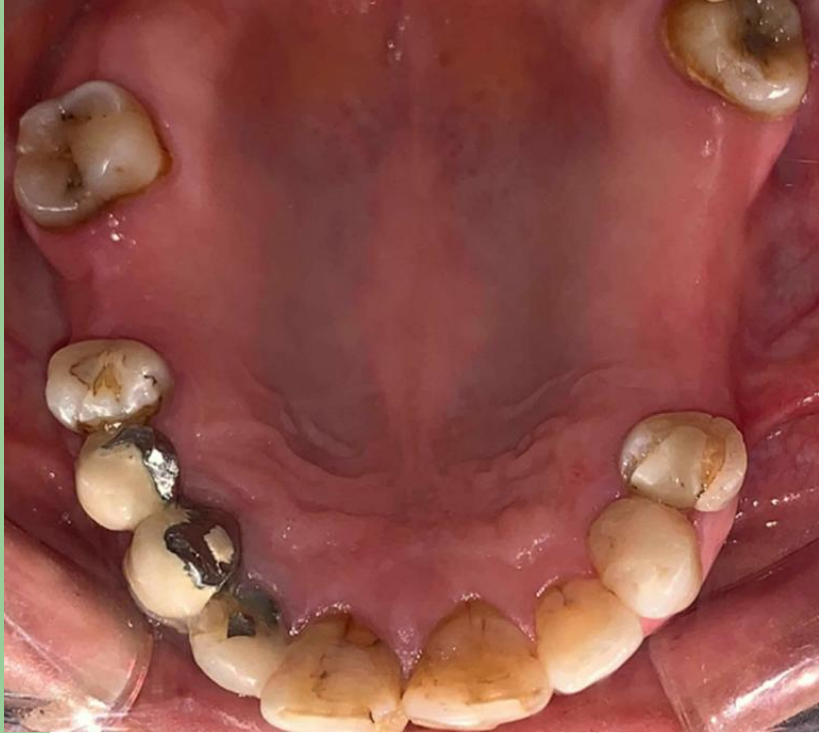OHI STATUS: 1.3 FAIR

Gingiva and periodontal Status

- Pink.
- Round gingival margin , blunt IDP.
- Bleeding on probing .
- Localized gingival recession .
- Pocket depth 1-4.
- CAL 0-3MM.
- No exudate , No Mobility ,No swelling
- Normal frenal attachment .

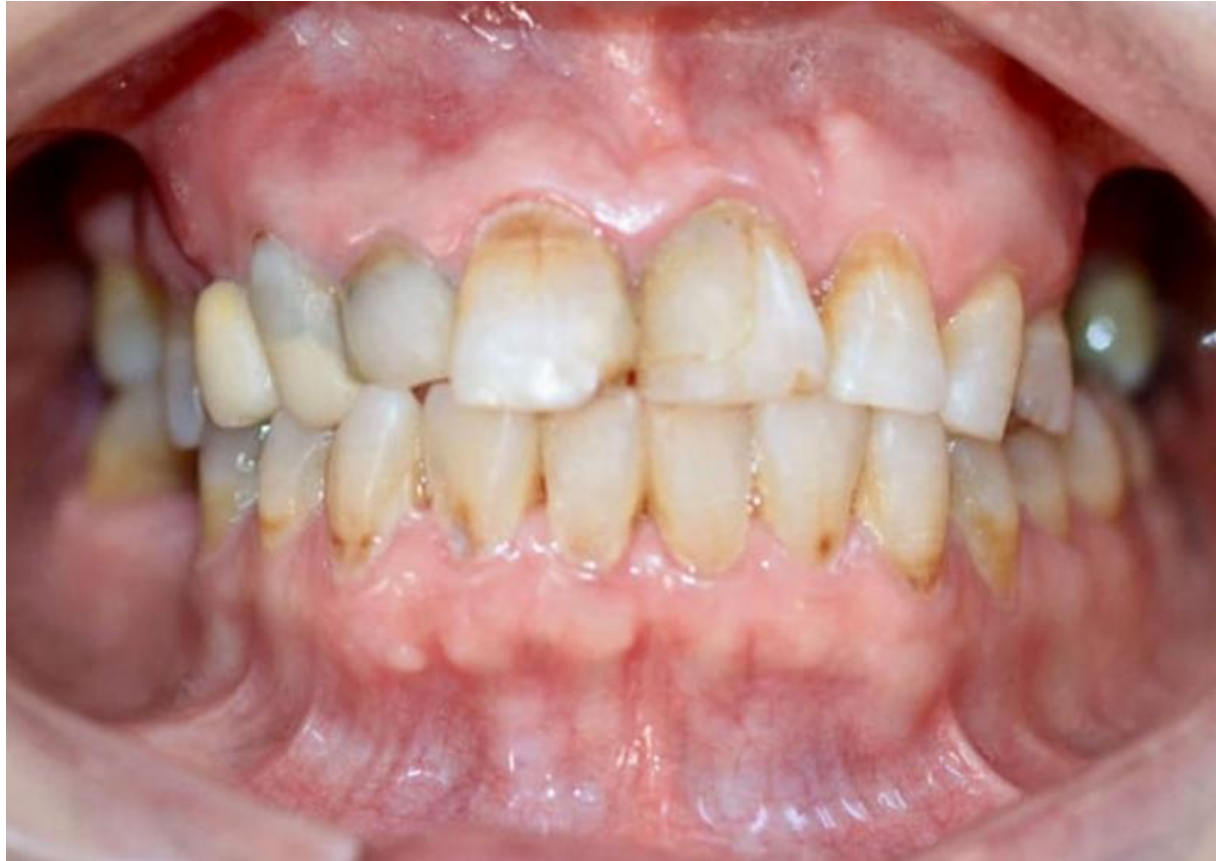Diagnostic Cast Analysis .



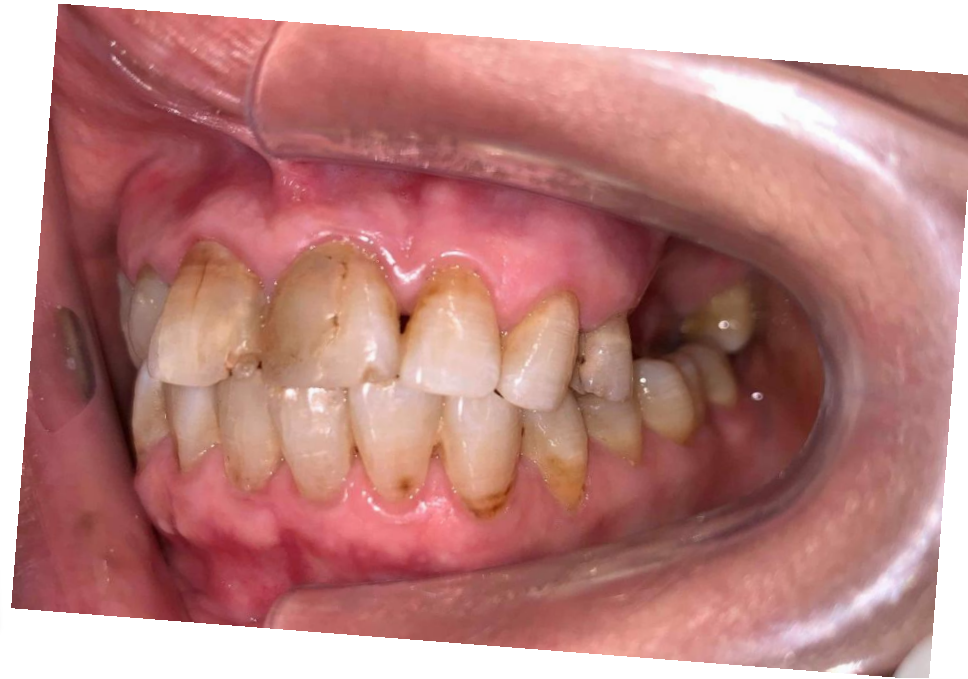
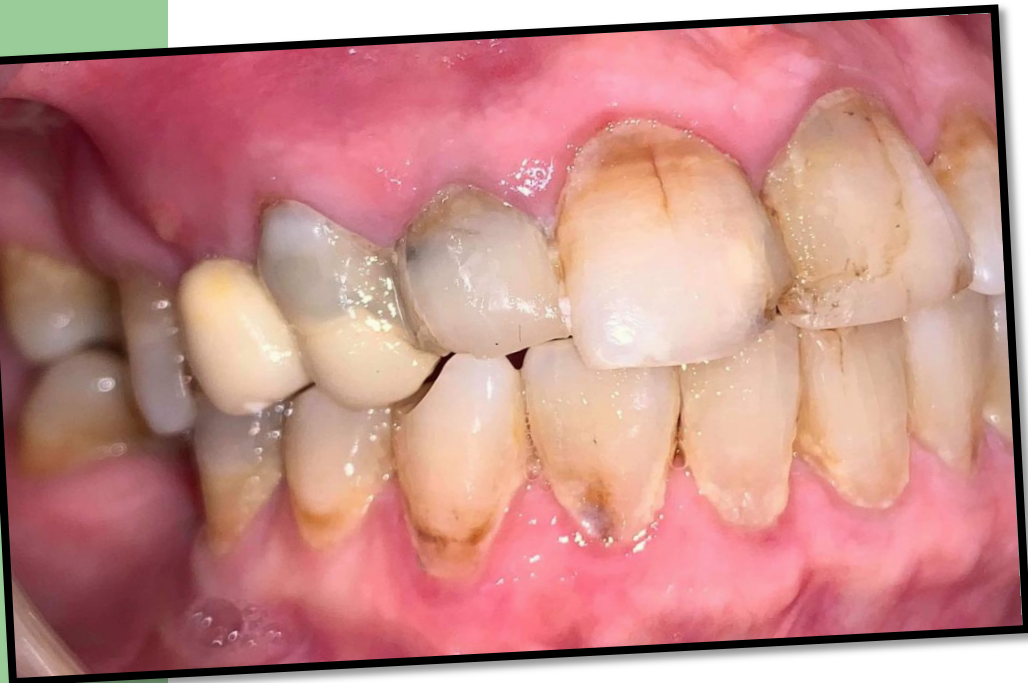
12 DMFT :14

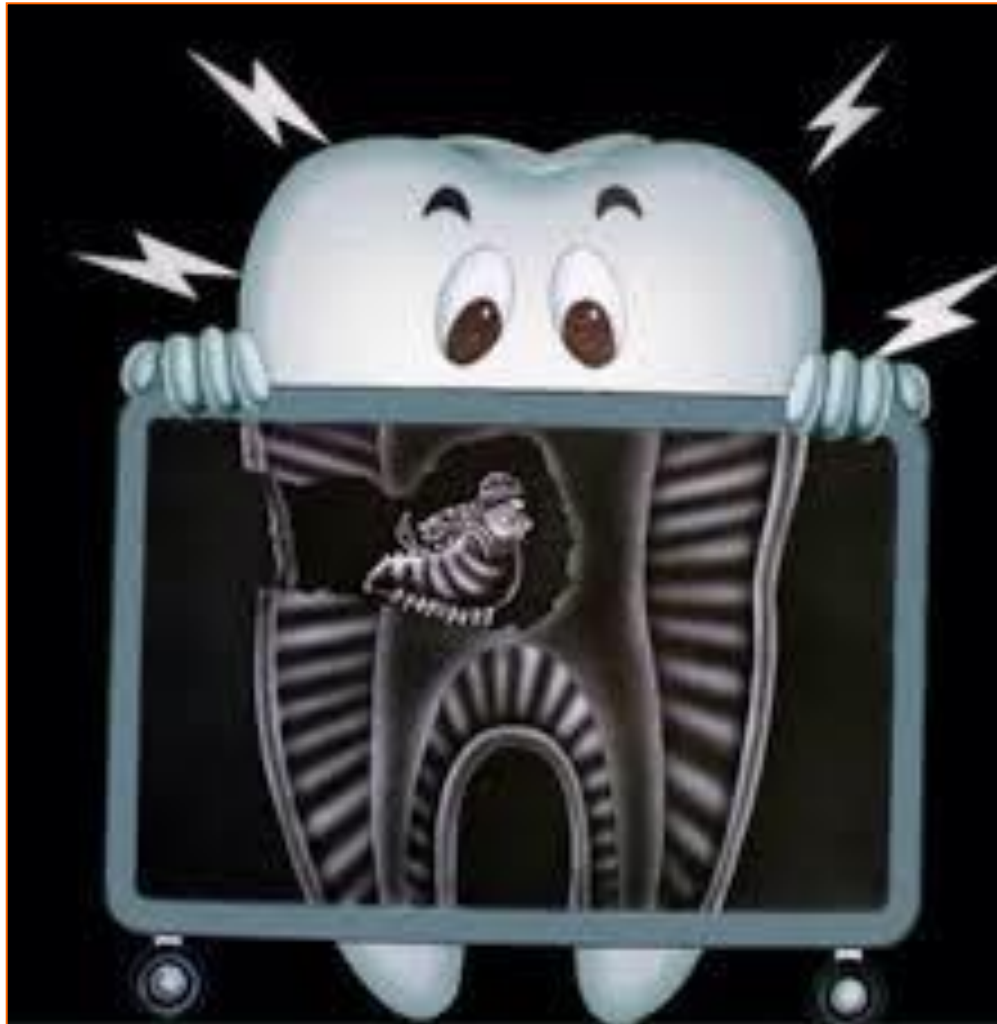Frontal view

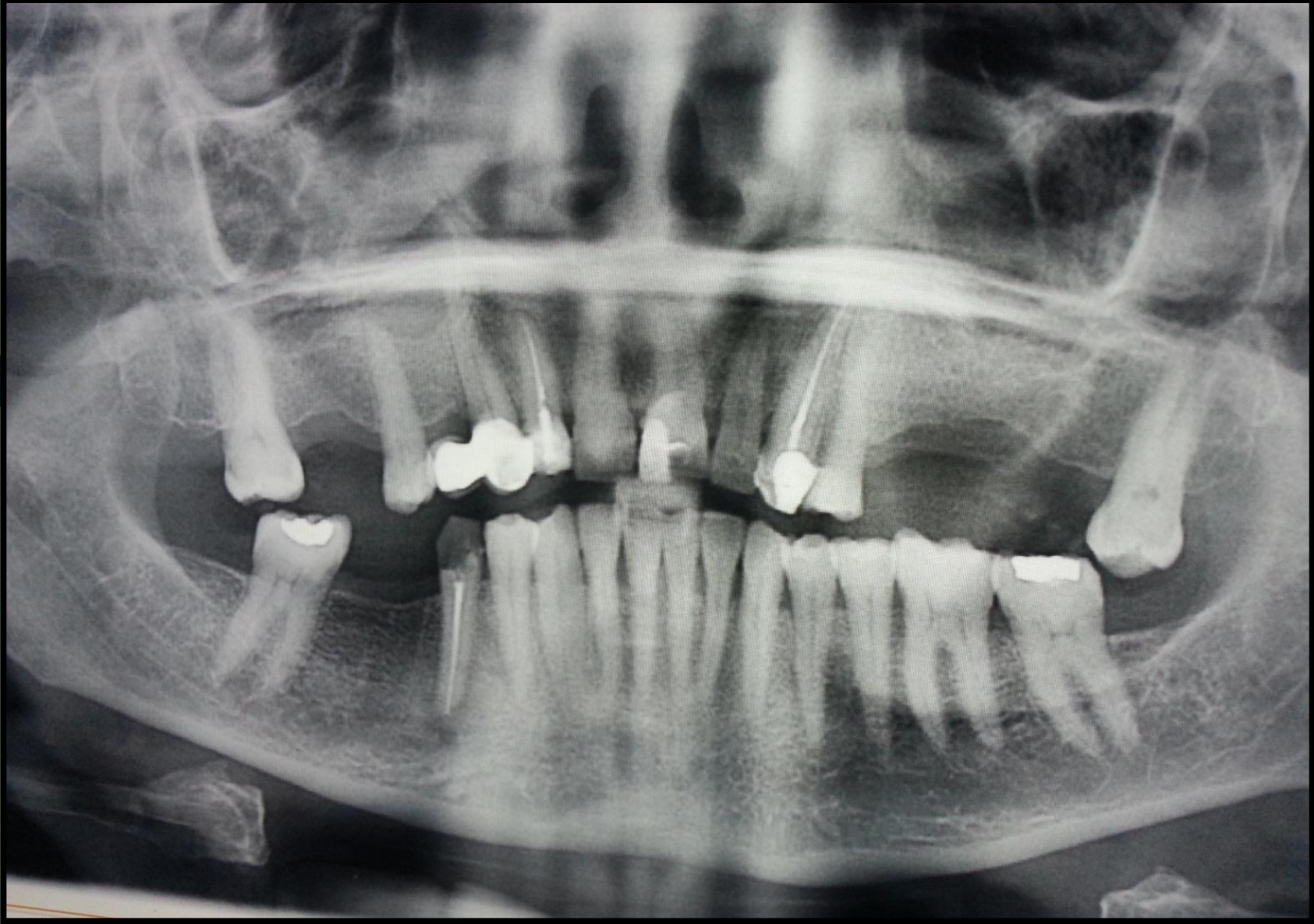


Lateral View



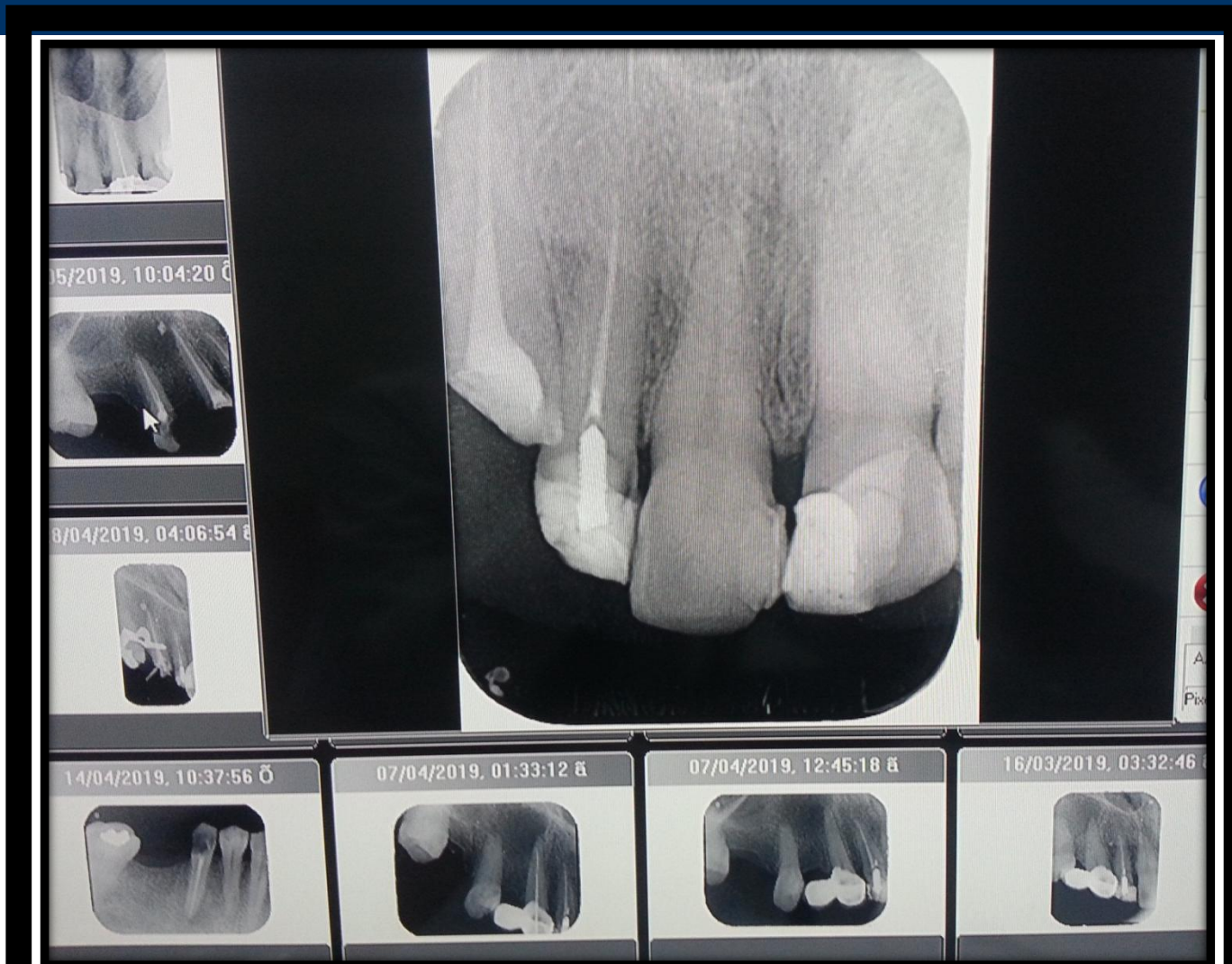Radiographic Examination





- ✓ **Panoramic view show Maxillary & Mandibular Generalized Mild periodontitis .**
- ✓ **Endodontic treated upper Rt lateral , Upper Lt Canine & Lower Rt 2nd Premolar .**
- ✓ **Show Large Lesion related to Upper Rt Canine .**

IOPA X-ray



Investigation

Referred by:
 Nature of specimen: Soft tissue swelling (right upper canine).

MACROSCOPIC DESCRIPTION:

A small irregular grey white soft to firm tissue mass measures 1.1x1x0.8 cm in size. On C/S: Soft, light brownish.

MICROSCOPIC DESCRIPTION:

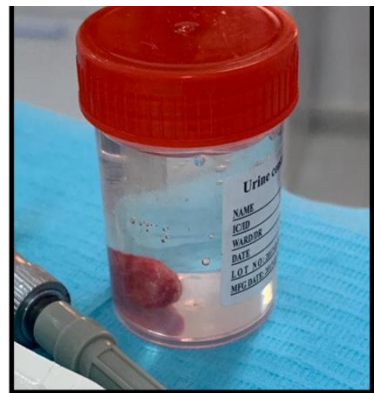
- Well-circumscribed tissue mass covered partially by stratified squamous epithelium with underlying active vascular stroma contains fibrohistiocytic cells and chronic inflammatory cells are seen beneath the epithelium along with small amount of neo-formed bone areas of calcification along with lymphocyte aggregation. There is no evidence of atypical or malignant changes.

DIAGNOSIS:

The picture is consistent with Periapical (radicular) cyst.

Faculty of Dentistry
 Biopsy Form

Patient Name: [Redacted]
 Age: 45 Sex: F
 Address: [Redacted]
 History (related medical issues, habits, medications): H/o D.m., H/o recurrent Dental infection and swelling related to upper (Rt) canine Premolar area. Teeth related were non vital!
 Location: [Redacted]
 Clinical appearance (duration, number, size, color, texture, related extra-oral lesions): Slight swelling vestibular with sinus tract, on palpation egg shell cracking. no other sin on Suptus.
 Radiographic appearance: radiolucent area 1cm x 1cm oval surrounded with radiopaque line. opical to 43.
 Type of biopsy: (Excisional biopsy) & L.A.
 Previous treatment: endodontic treatment.
 D.D.: Radicular Cyst (Inflammatory Cyst)
 - Periapical Cyst
 - Periapical granuloma.
 Date: 23/9/2019.
 Surgeon Name & Sig: [Signature]
 LIMU
 0927321812



Final Diagnosis :

✓ Generalized mild chronic periodontitis.

✓ Multiple Caries . 7 8

7	43	1	2	3	4	5	6	7
---	----	---	---	---	---	---	---	---

✓ Recurrent caries 7

✓ Radicular Cyst related to Upper Rt Canine .

✓ Endodontic treated with badly destructive Crown.5

✓ Edentulous areas “Kennedy classification “

○ Upper arch : Class III .

○ Lower arch : Class II.

Treatment plan

- ❖ **Phase I** : O.H instruction & scaling
- ❖ **phase II**: Surgery (cyst enucleation with curettage) & apicectomy 3.
- ❖ **Phase III** : RCT 5 3 1
- Retreatment 5 | 2 3
- ❖ restoration :
- ✓ Composite restoration 7 | 4 3 1 2 3 4 5 6 7
- ✓ Amalgam restoration 7 | 8
- ✓ Composite Veneer 2 3
- Replacement :
- ✓ Custom made poste & core + PFM Crown 5
- ✓ Custom made poste & core + E-Max 5 2
- ✓ Replacement by E-Max Crown 1 1 4
- ✓ Replacement RPD .

Patient Informed Consent :

الجامعة الليبية الدولية للعلوم الطبية
كلية طب وجراحة الفم والأسنان
موافقة للأذن بالعلاج

أقر أنا بطاقتي شخصية رقم
وبكامل اراضي اعطيت موافقتي اللغضية والكتابية للبدء والاستمرار في العلاج بعيادات كلية طب الأسنان بالجامعة
الليبية الدولية للعلوم الطبية والذي يتضمن
.....
.....
وقد تم شرح التشخيص المرضي لحالتي والخيارات المختلفة المتوفرة لمعالجتها والأعراض الجانبية والمخاطر التي قد
تصلب العلاج والمشاكل التي قد تنتج عن عدم العلاج والمدة التقريبية اللازمة للانتهاء منه والتكلفة الاجمالية للعلاج
وفقا للرسوم الرمزية المقررة كما اتفهم ان هذا العلاج قد تم تنفيذه من قبل طالب او طبيب اميتير تحت الاشراف المباشر
لأعضاء هيئة التدريس بالكلية.
ارفض العلاج - تبييض الأسنان - قرصم السن الامامية
الموافقا على عرضها الصور لرفض العملية التعليمية

اسم المريض:
توقيع المريض:
اسم الطالب أو طبيب الامتياز:
الاستاذ المشرف:
التاريخ: 2019.1.17

Phase I therapy :

- ❖ **Patient motivation.**
- ❖ **Oral hygiene instructions.**
- ❖ **Scaling.**
- ❖ **Diet Sheet .**
- ❖ **Re-evaluation .**

Diet sheet

Patient Name: _____ Gender: M/F Date of Birth: _____
 Occupation: _____ Address: _____

نوع الوجبة	الأكلات والشروبات	الساعة	الأيام
الغذاء العشاء	زيتون الزيتون + خبز + جبنة حليب القمح رز مبلوح بالخضروات + مشروب غازي قهوه + بسكوته	10:00 صا 2:30 صا 4:00 صا 11:00	الصبيحة
الغذاء العشاء	بسكوته + بسكوته مكرونه + بطاطه مبيكه + مشروب غازي شاي + بيريوت	8:30 صا 2:00 صا 5:00 صا 12:00 صا	الاثنين
الغذاء العشاء	قهوة بالحليب + بسكوته كسكس بالخضروات + سلطة الخضروات قهوة + شاي + آفاج مكرونه بساطة خضروات + مشروب	10:30 صا 3:00 صا 5:30 صا 10:00 صا	الاثنين

Scaling



Floss



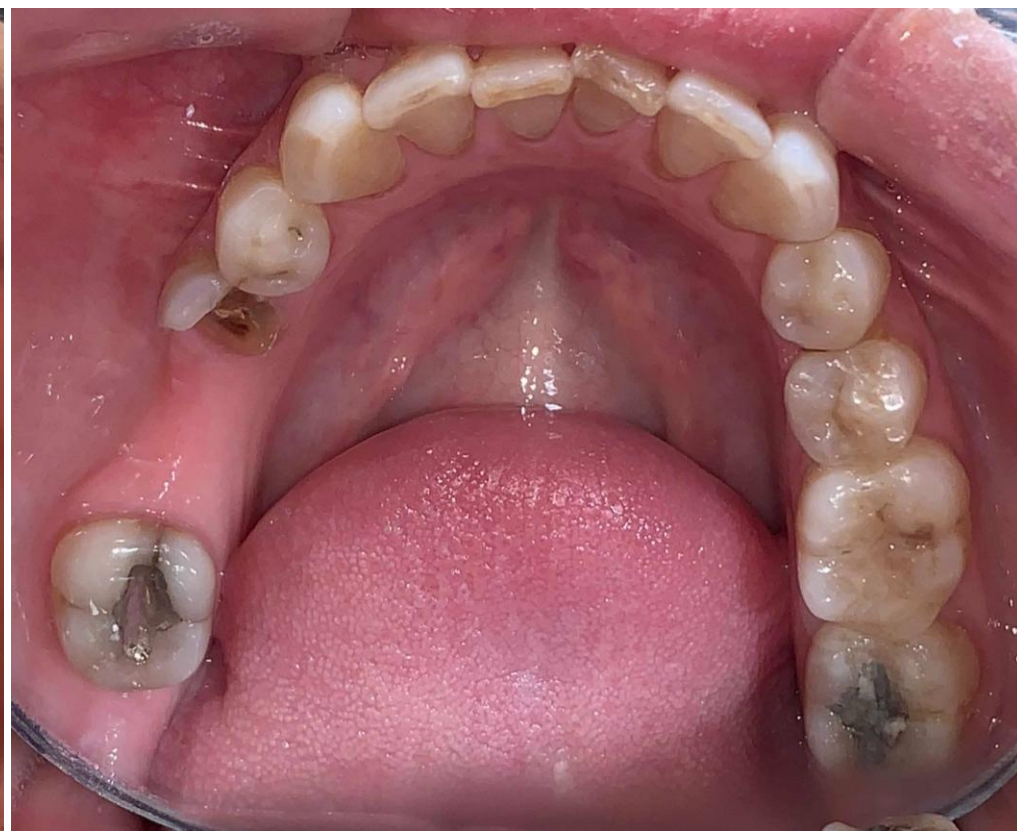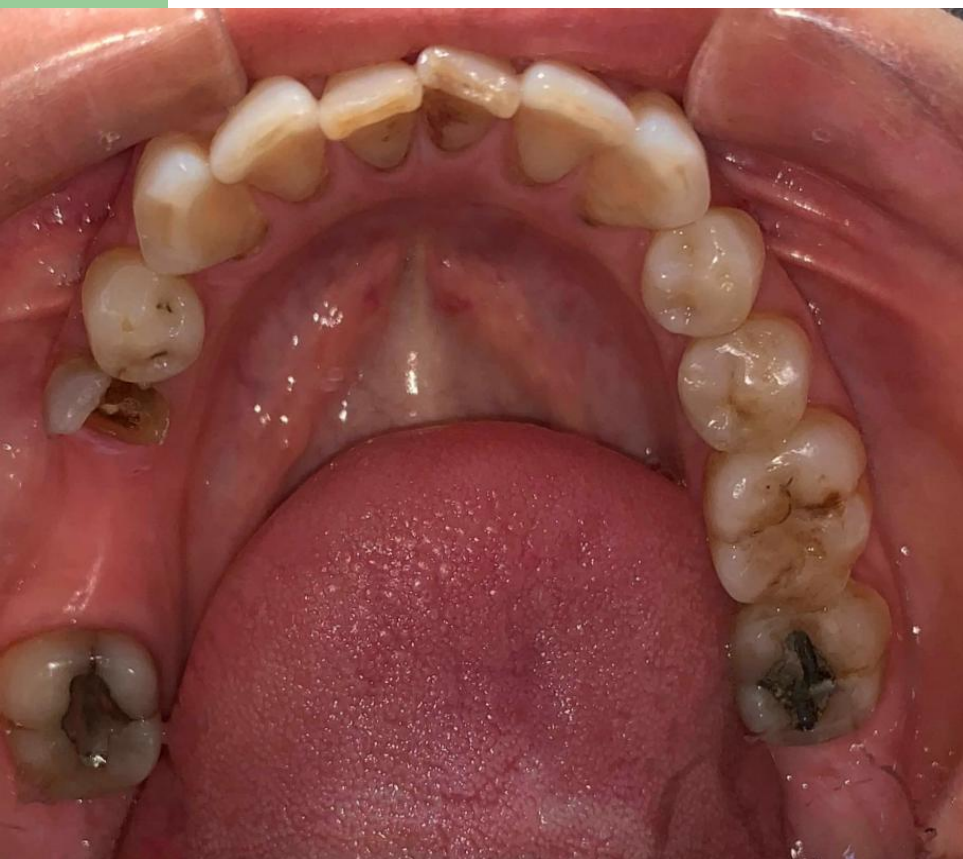Brush



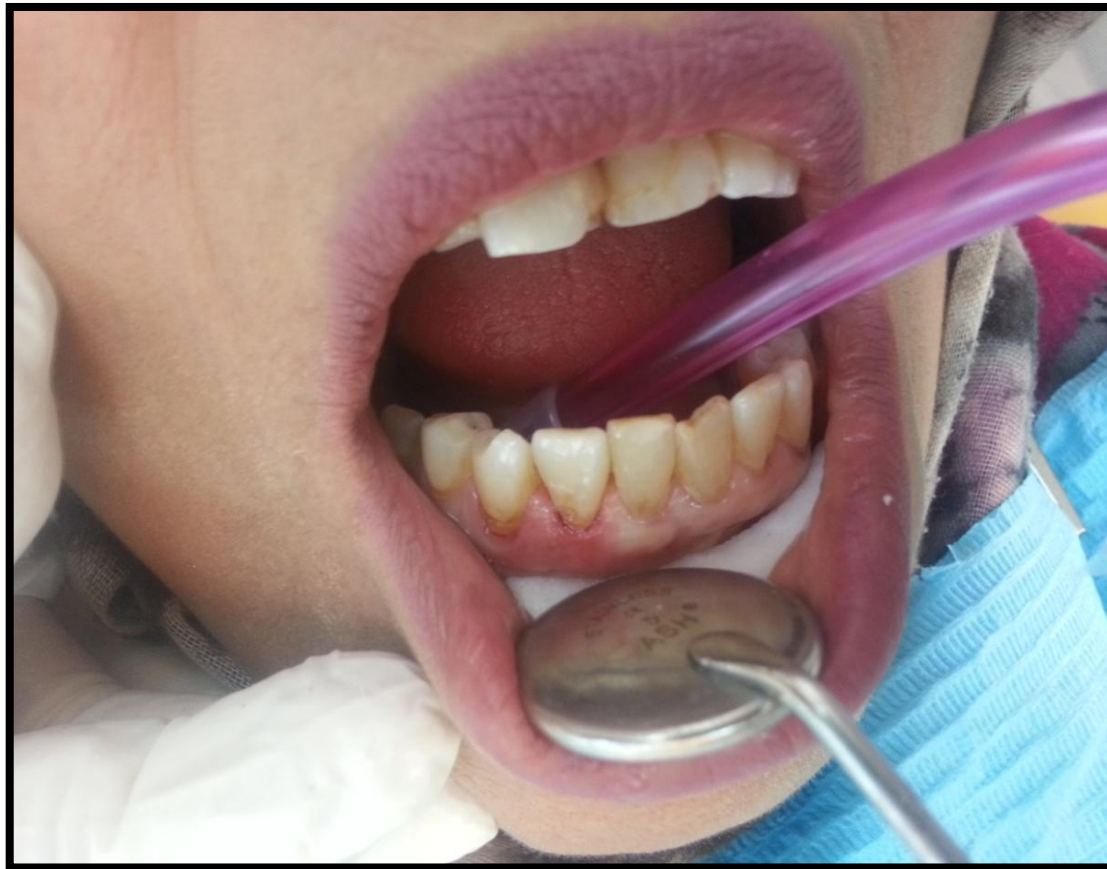Rinse

Before

after

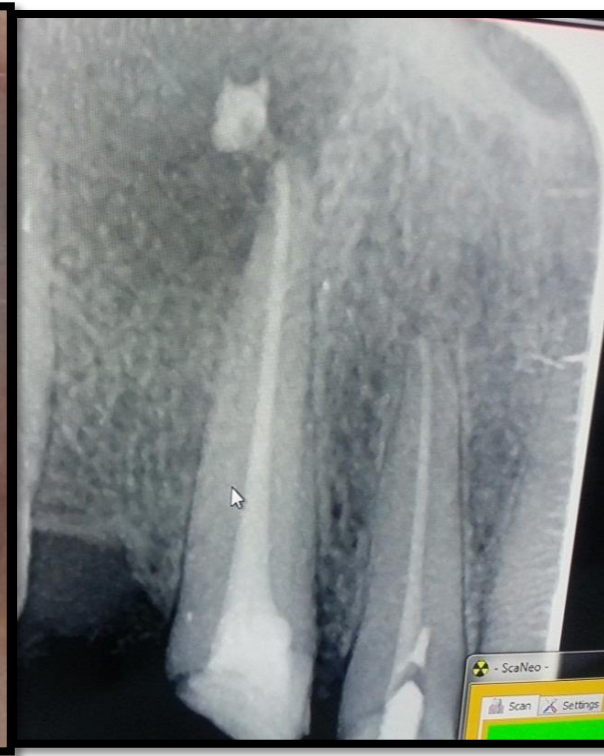
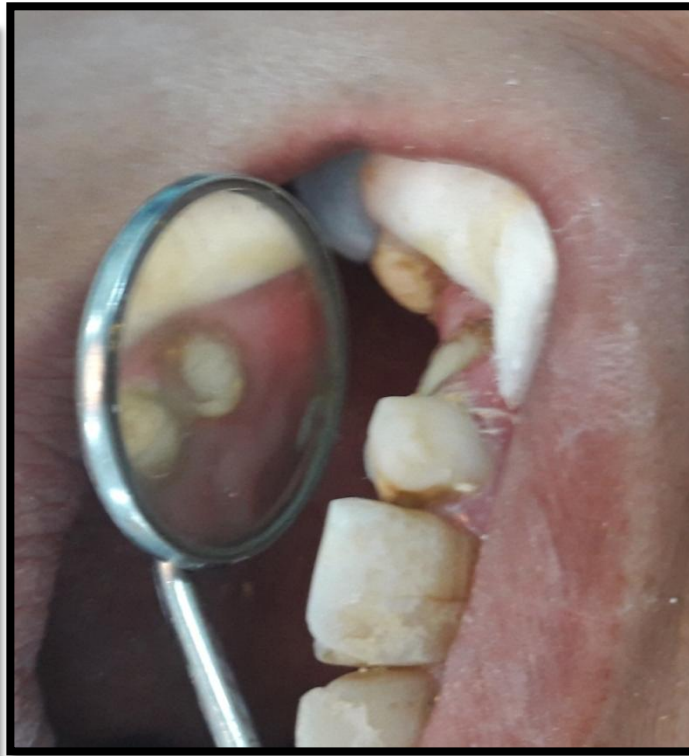
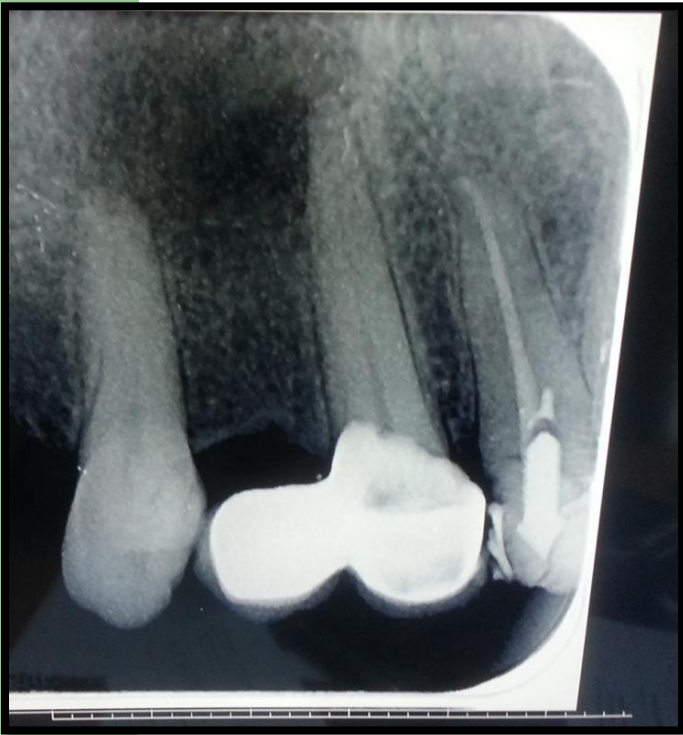Re – evaluation

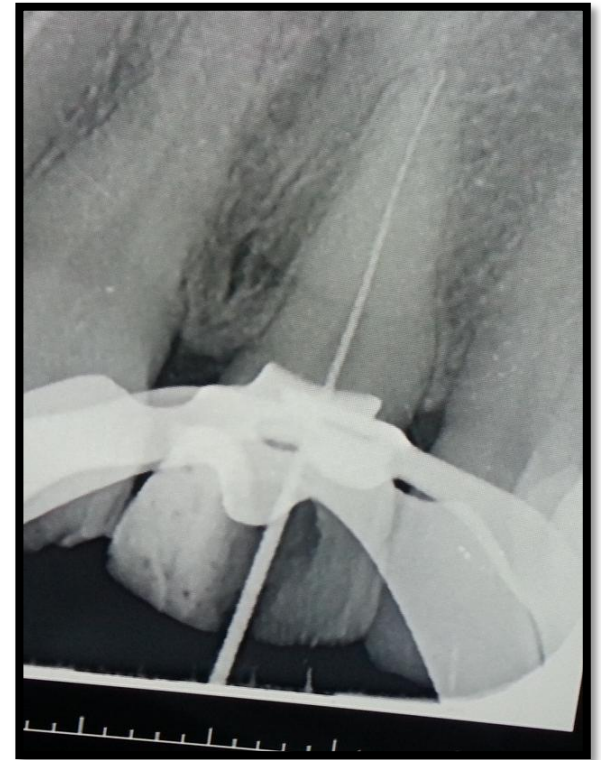
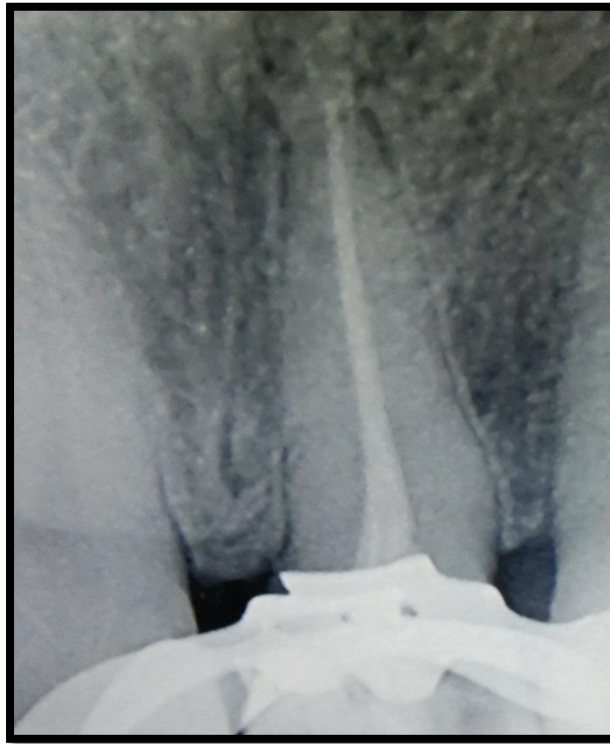
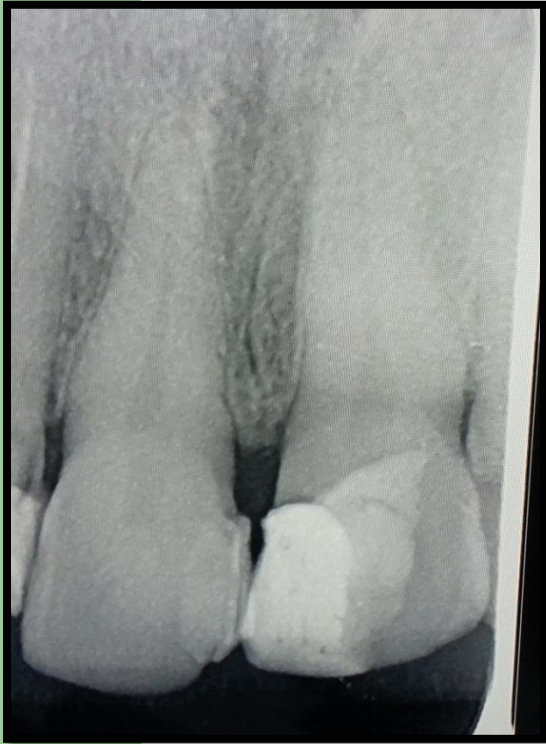Phase III

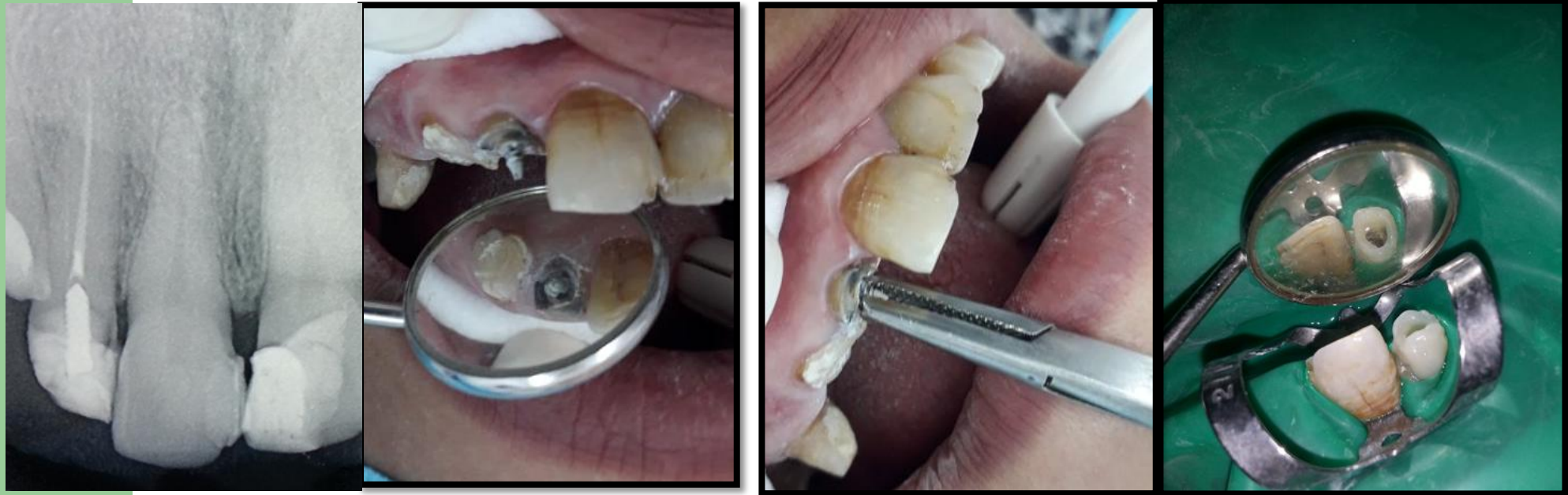RCT : upper Right canine

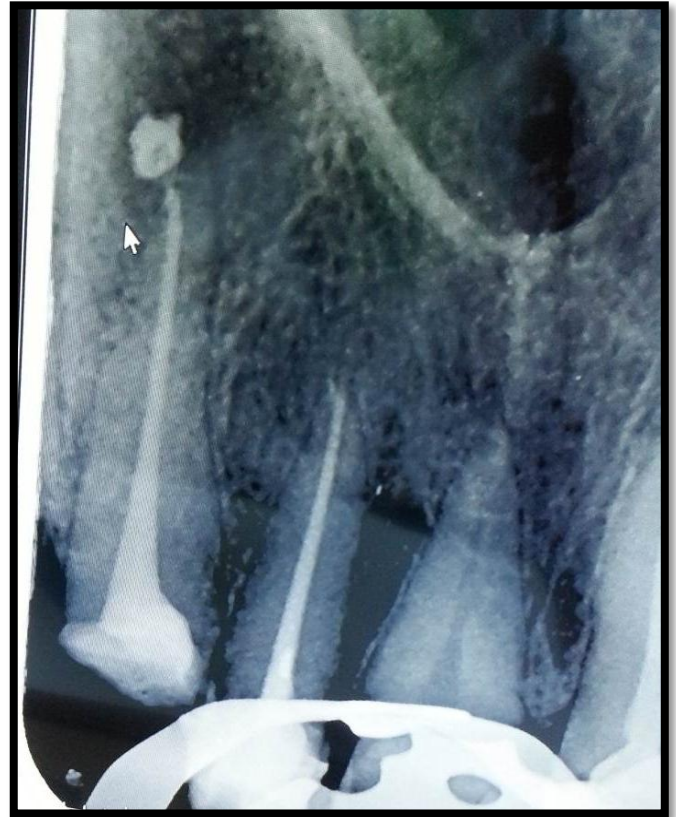
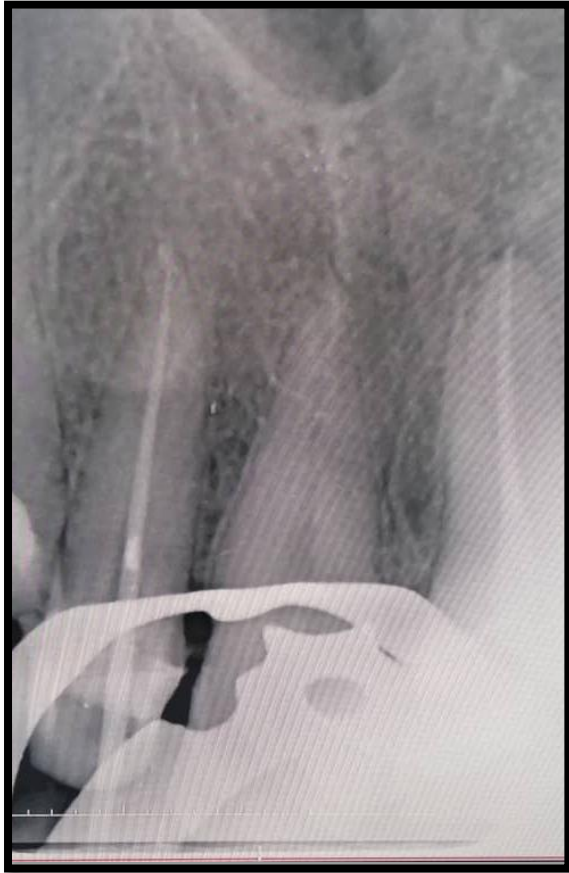
Root Canal Treatment upper left central

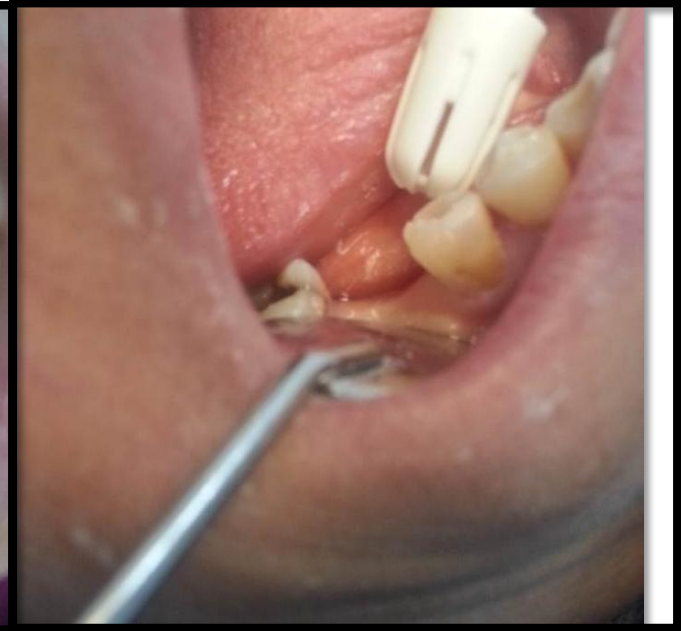
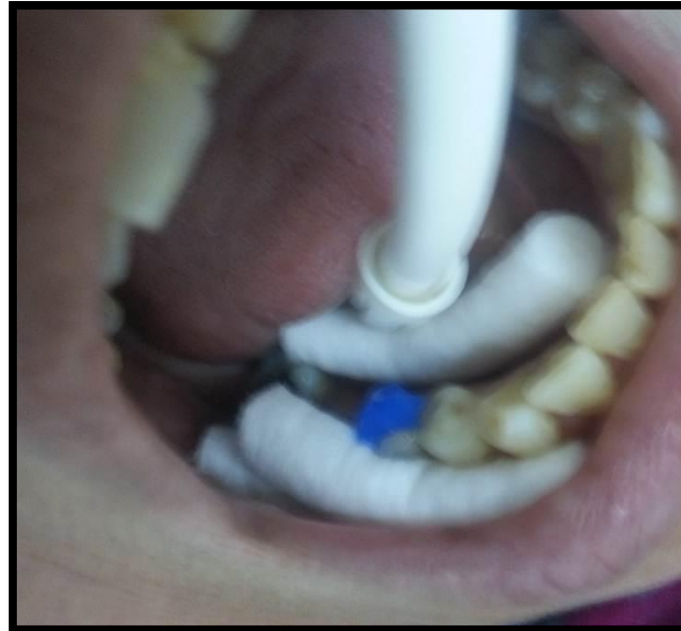
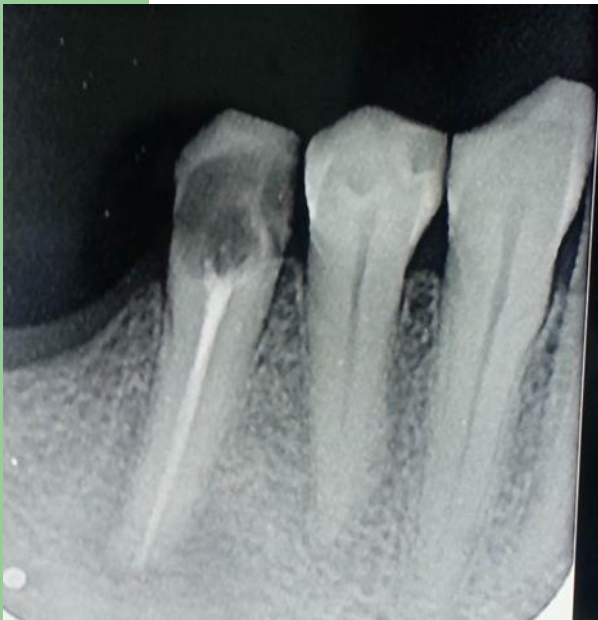

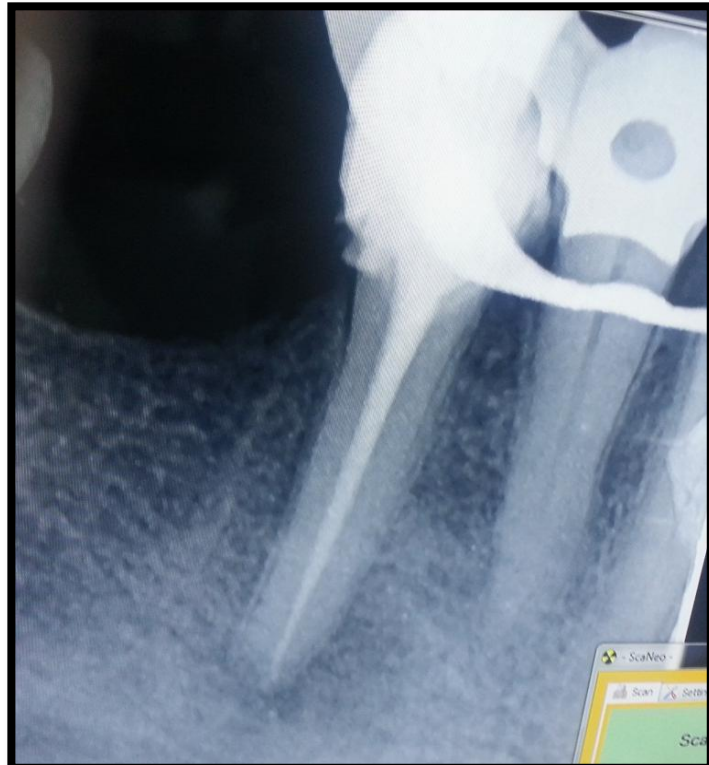
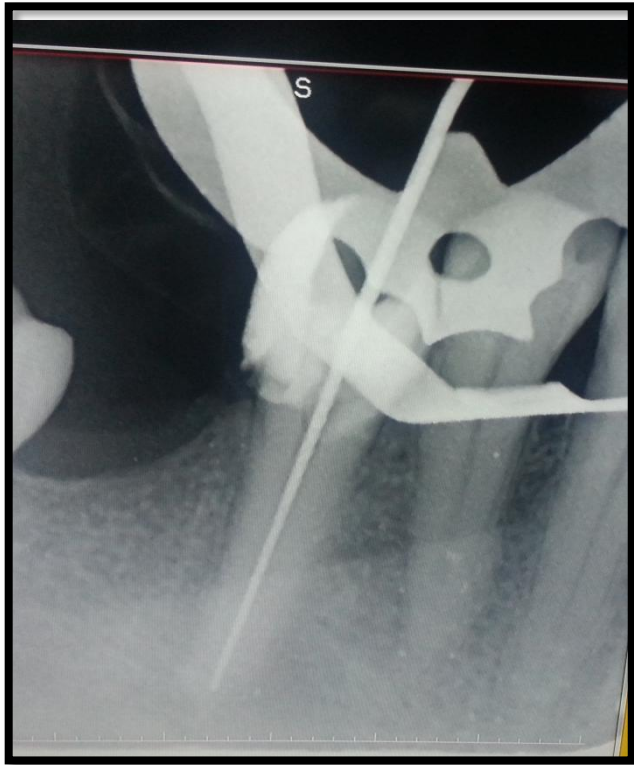
Retreatment upper right lateral



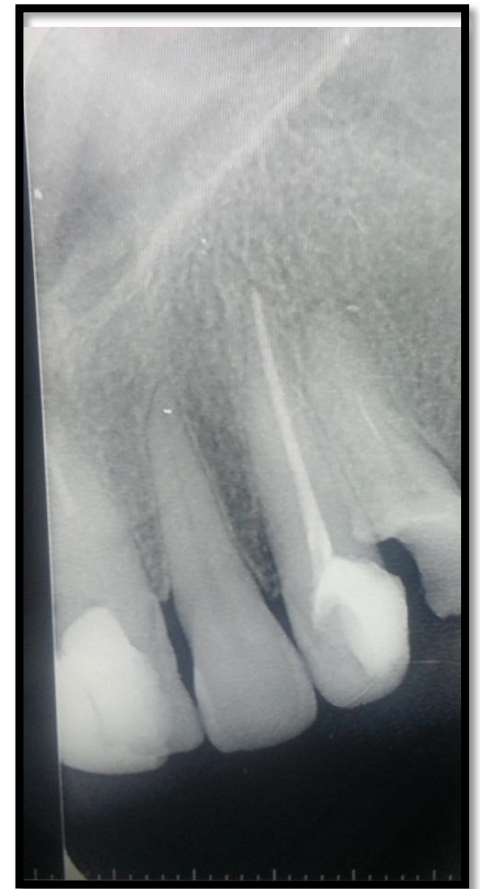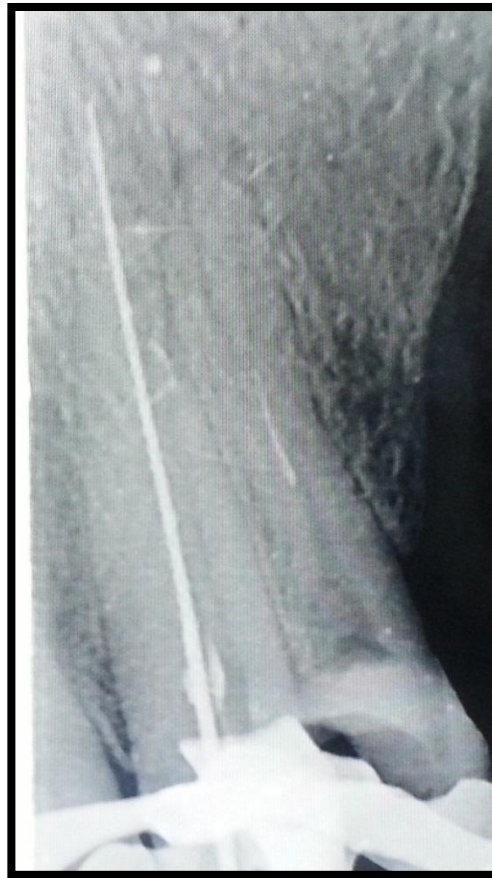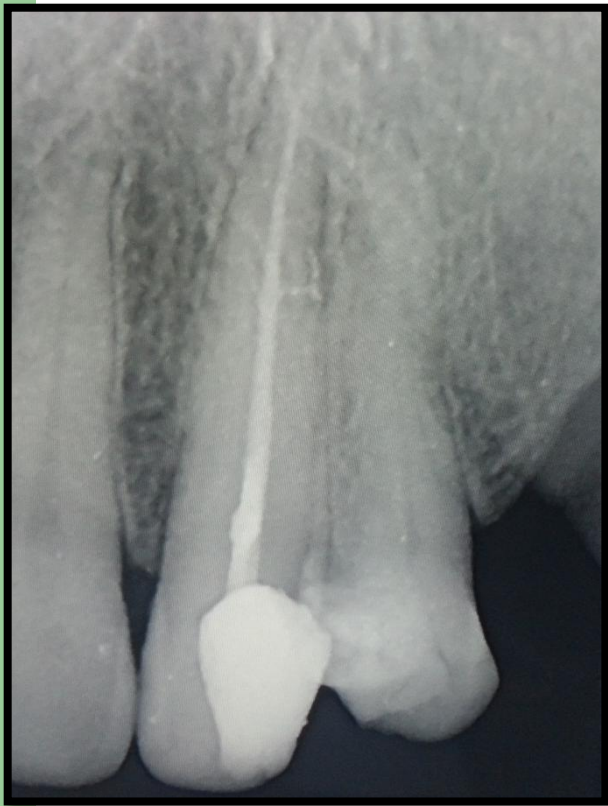


Retreatment lower right 2nd premolar

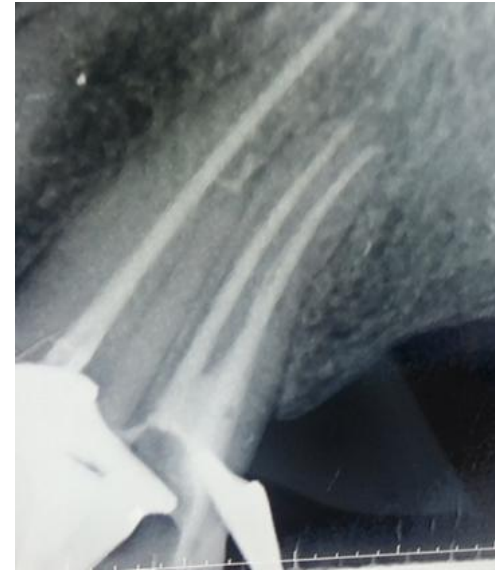
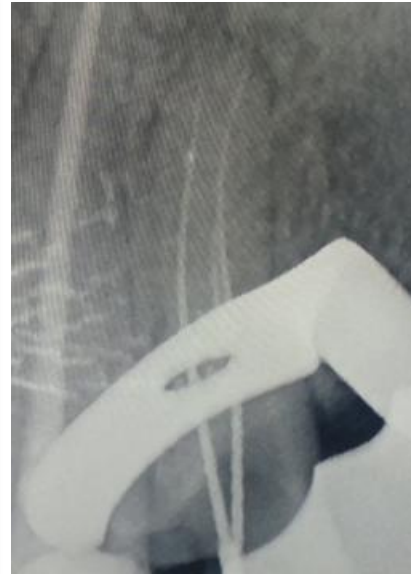
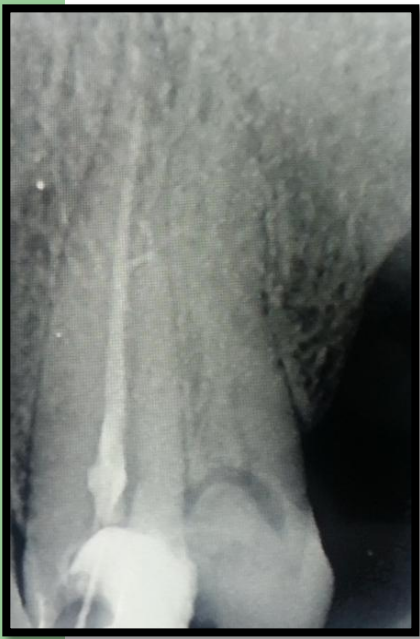


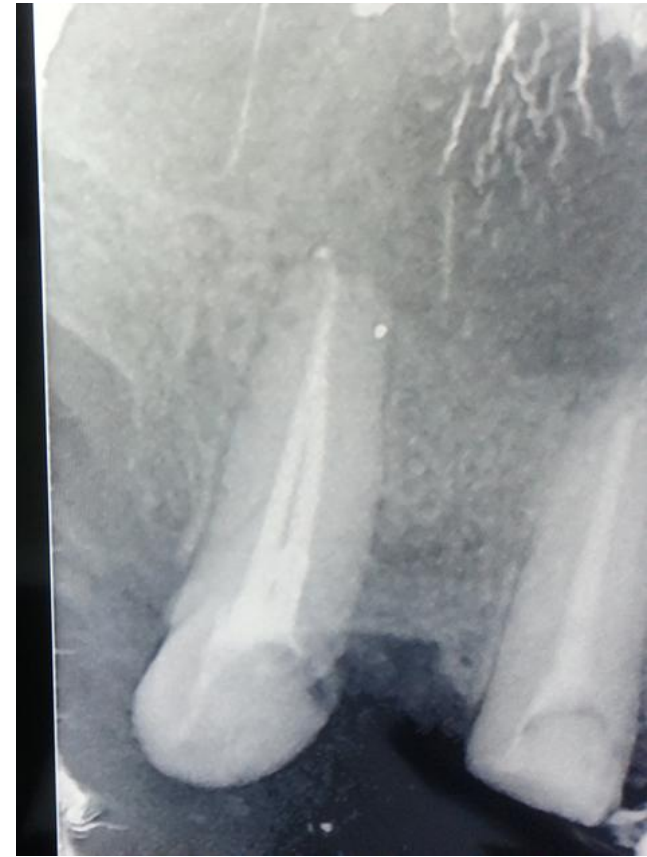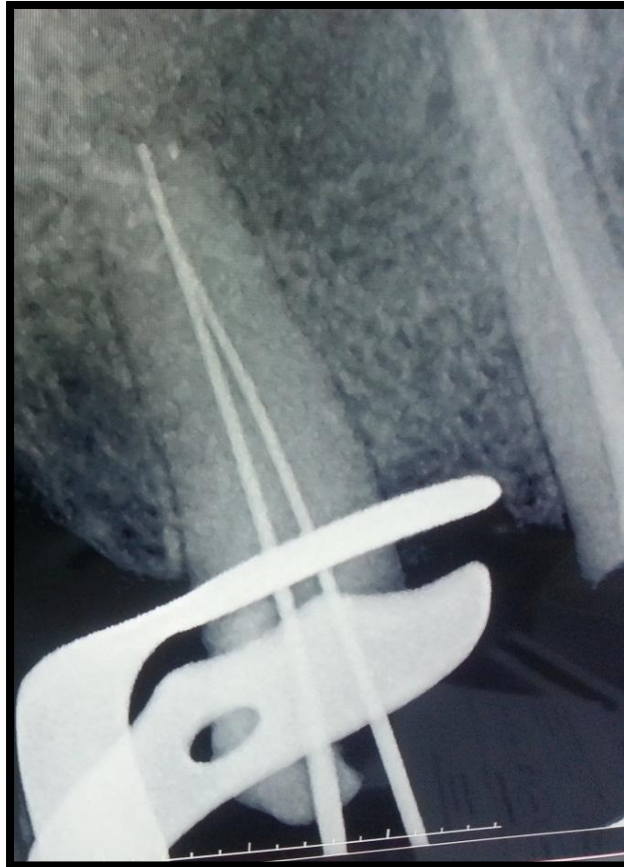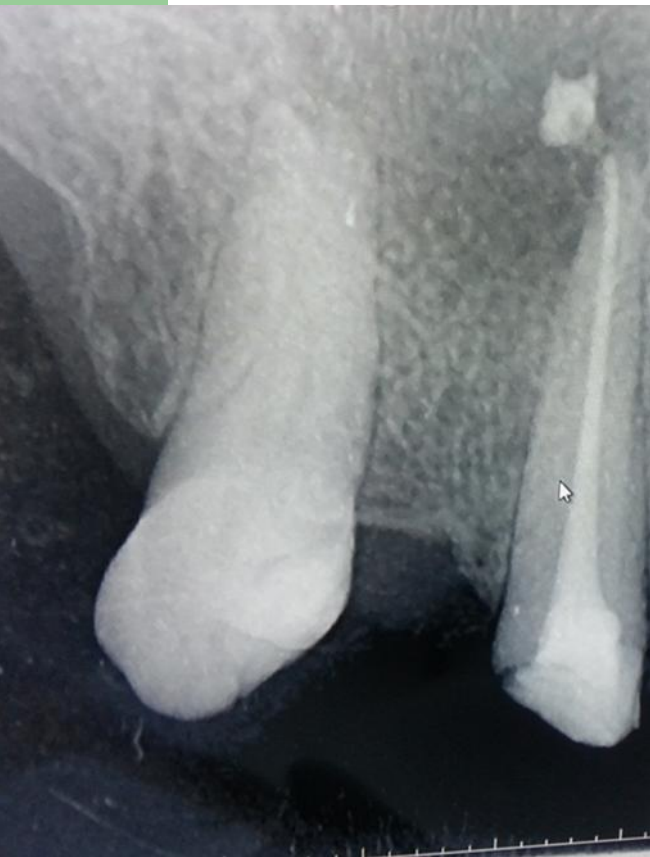Retreatment upper left canine



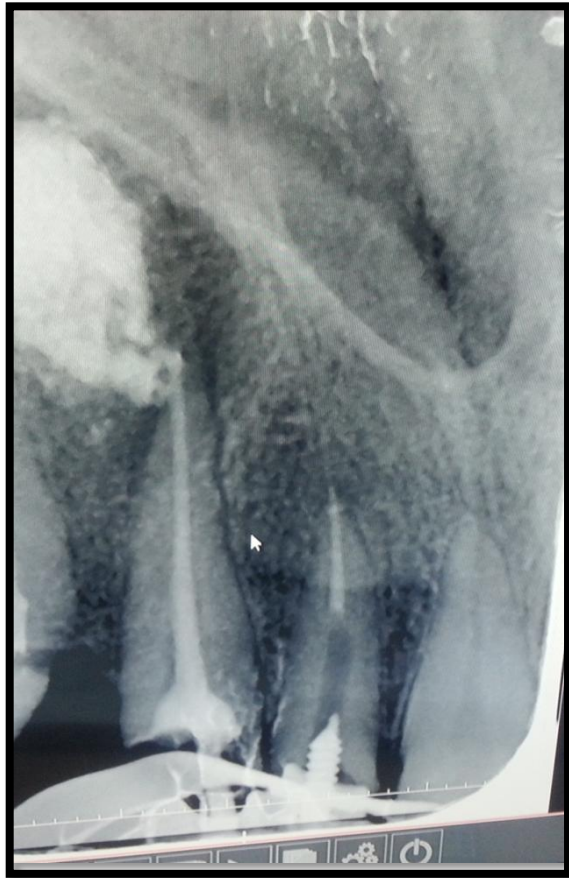Root Canal treatment upper 1st premolar left



RCT : Upper right 2nd premolar .



Redo



Patient Informed Consent :

الجامعة الليبية الدولية للعلوم الطبية
كلية طب وجراحة الفم والأسنان
موافقة للأذن بالعلاج

7210
[Redacted]

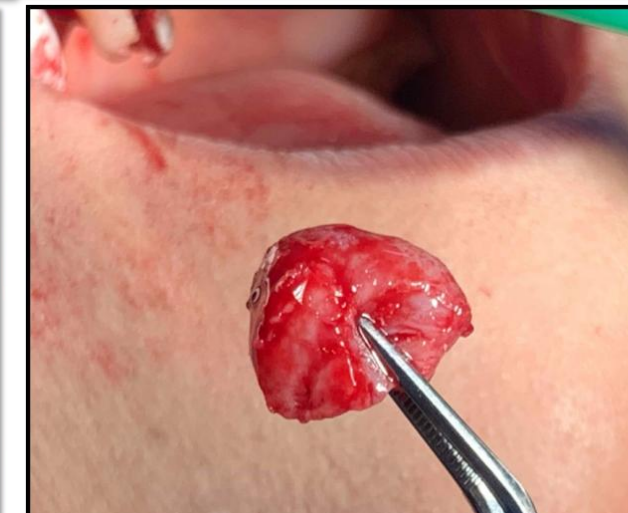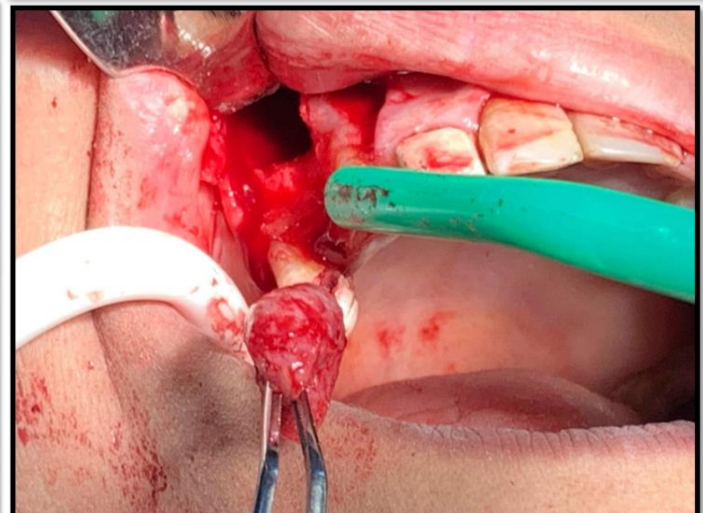
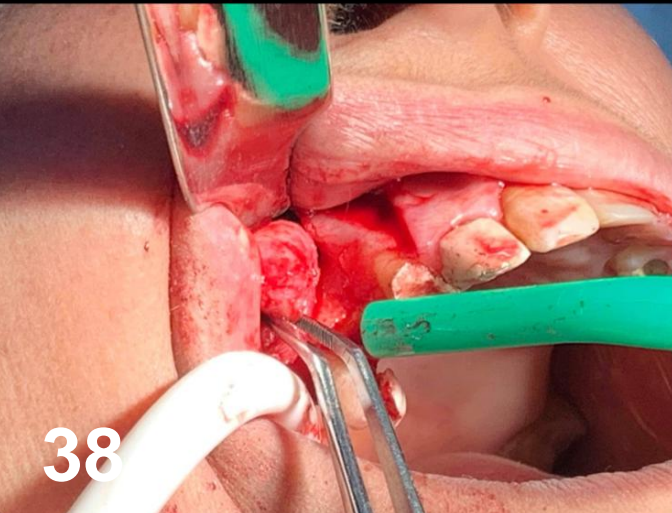
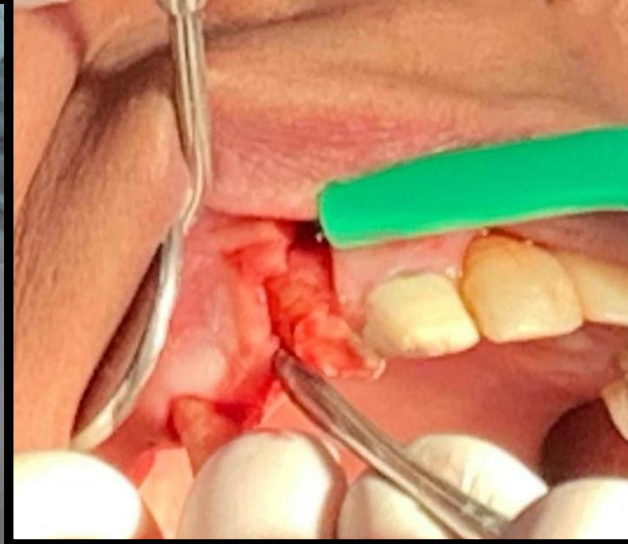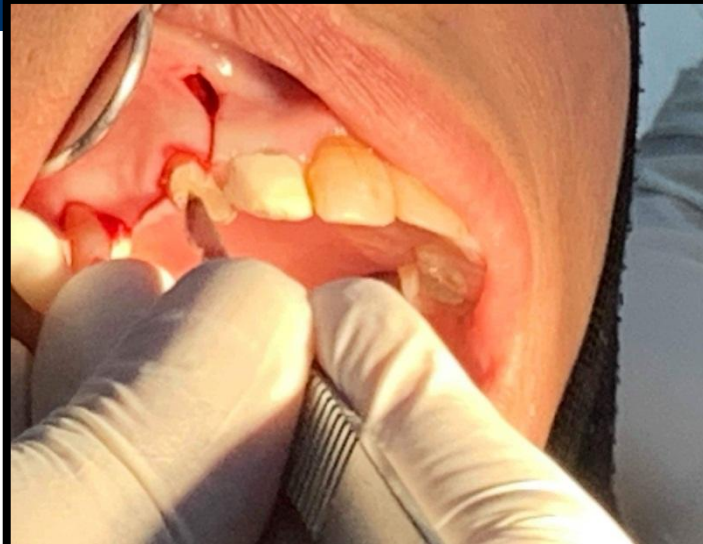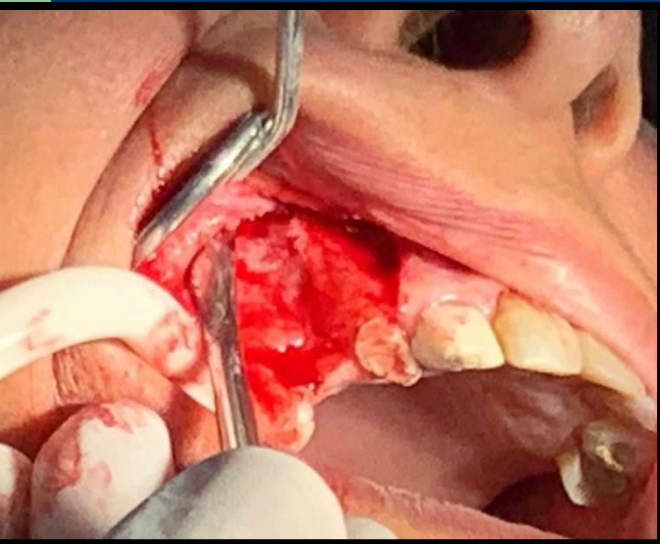
ويكامل ارادتي أنني أعطي موافقتي للفضية والكثبية للبدء والإستمرار في العلاج بعلاج
الليبية الدولية للعلوم الطبية والتي يتضمن

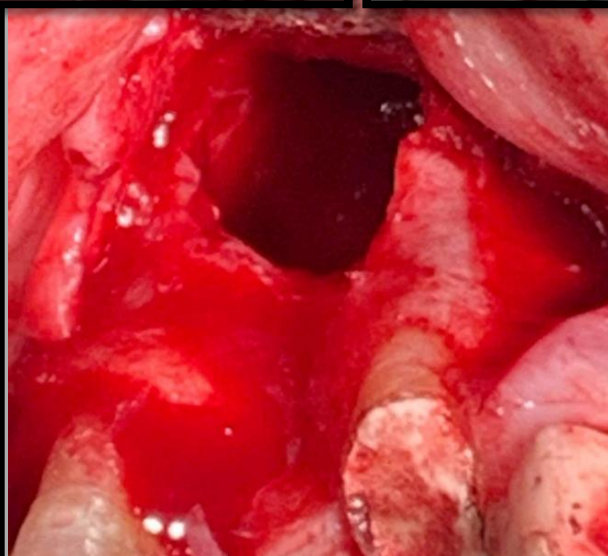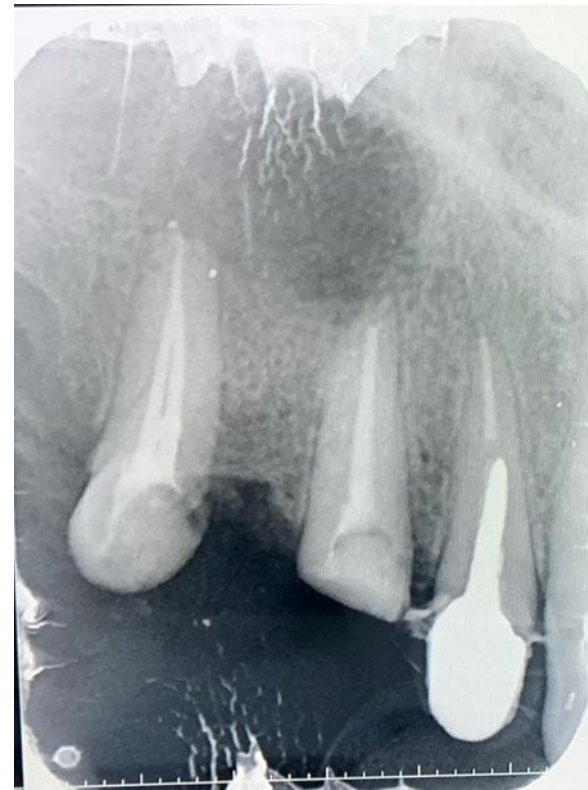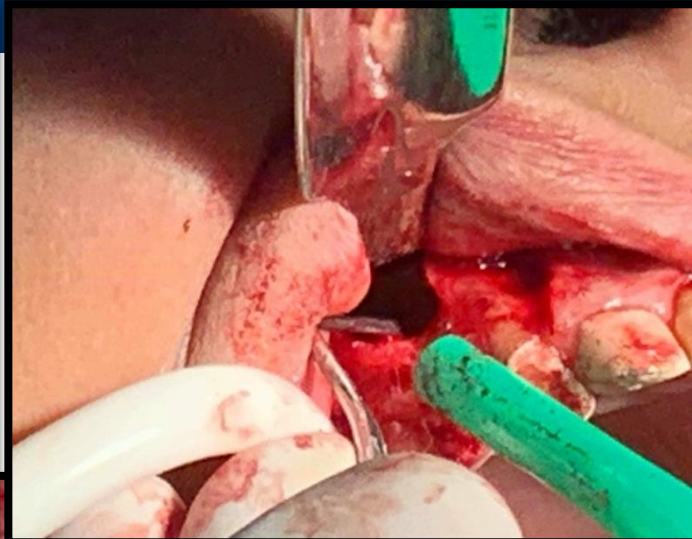
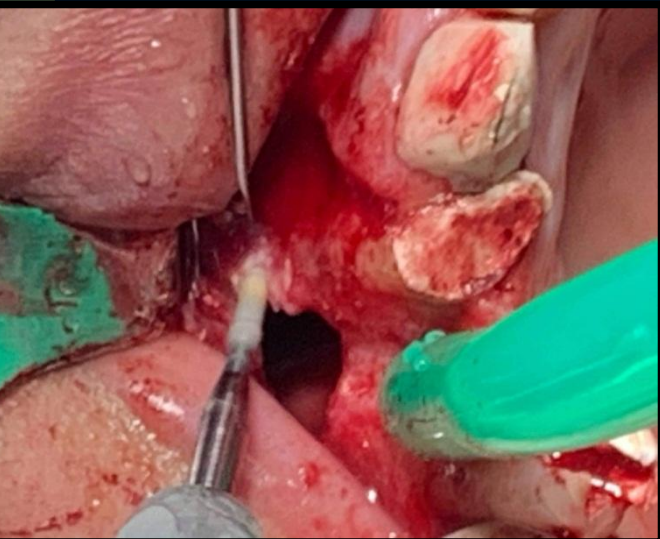
جراحة الفم والأسنان
[Redacted]

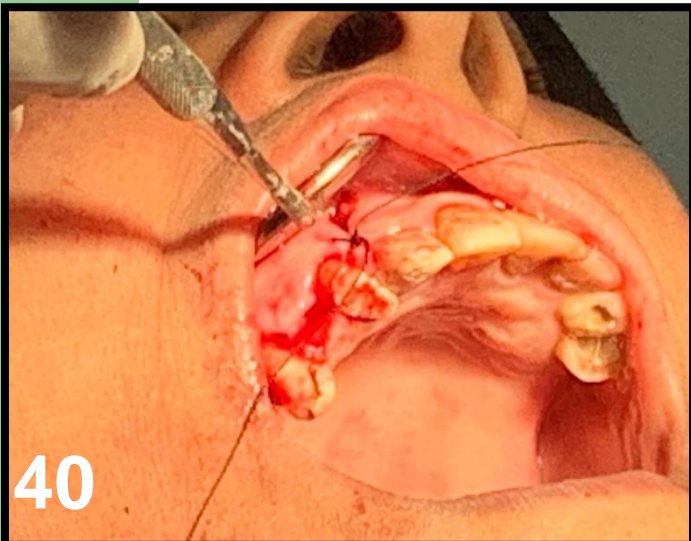
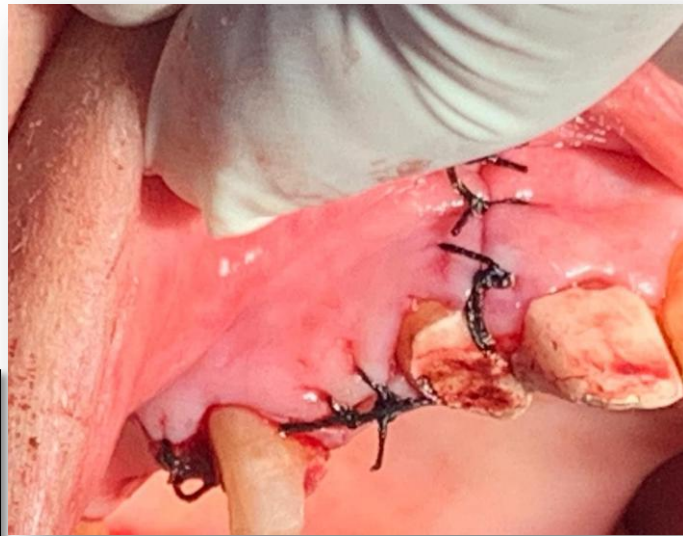
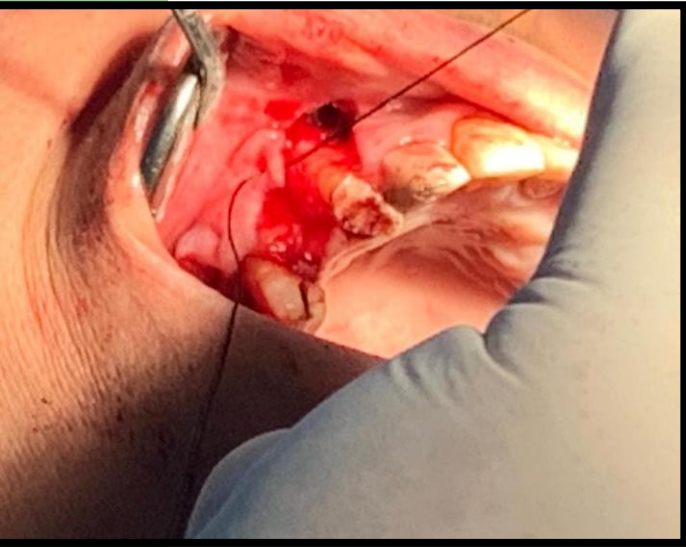وقد تم شرح التشخيص المرضي لحالتي والخيارات المختلفة المتوفرة لمعالجتها والأعراض الجانبية والمخاطر التي قد
تصاحب العلاج والمشاكل التي قد تنتج عن عدم العلاج والمدة التقريبية اللازمة لانتهاء منه والتكلفة الاجمالية للعلاج
وفقا للرسم الرمزية المعروفة كما تفهم ان هذا العلاج قد تم تنفيذه من قبل طالب أو طبيب امتياز تحت الإشراف المباشر
لأعضاء هيئة التدريس بالكلية

اسم المريض: [Redacted]
توقيع المريض: [Redacted]
اسم الطالب أو طبيب الإمتياز: [Redacted]
الأسفد المشرف: [Redacted]
التاريخ: 23/6/2019

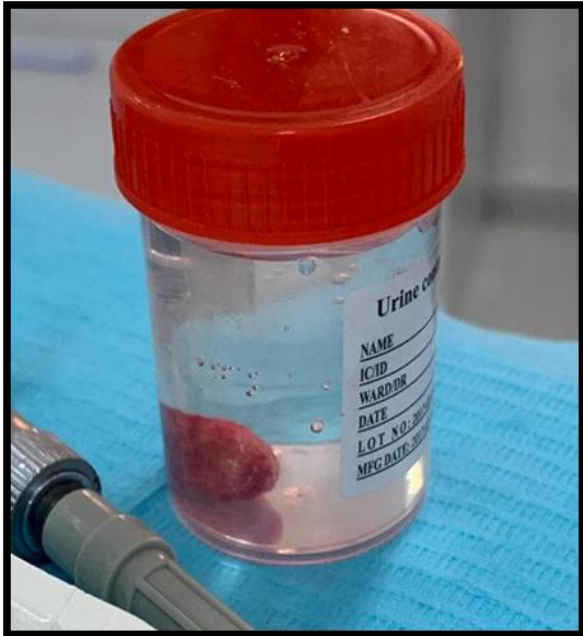
Surgical Procedure







Biopsy



جامعة ليبيا الدولية للعلوم الطبية
 Libyan International Medical University

Faculty of Dentistry
Biopsy Form

Patient Name: السيدة [Redacted]
 Age: 45 Sex: f
 Address: [Redacted]

History (related medical issues, habits, medications): H/O D.m.; H/O recurrent Dental infection and swelling related to upper (Rt) canine Premolar area. teeth related were non vital.
 Location: _____

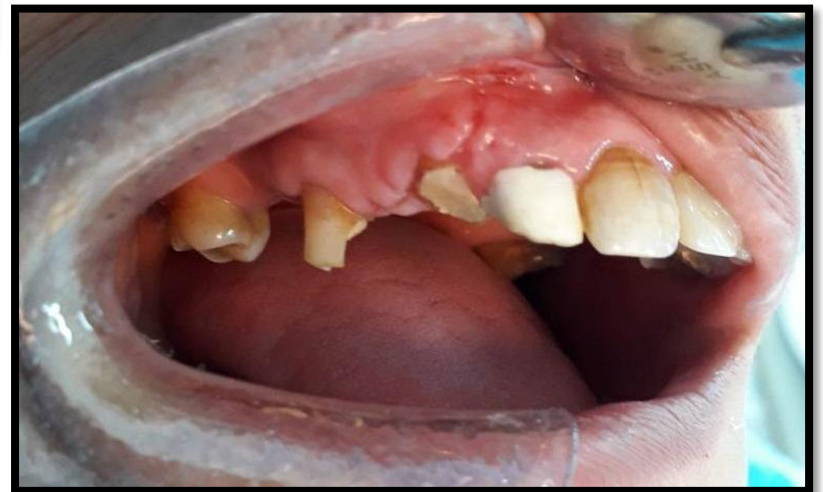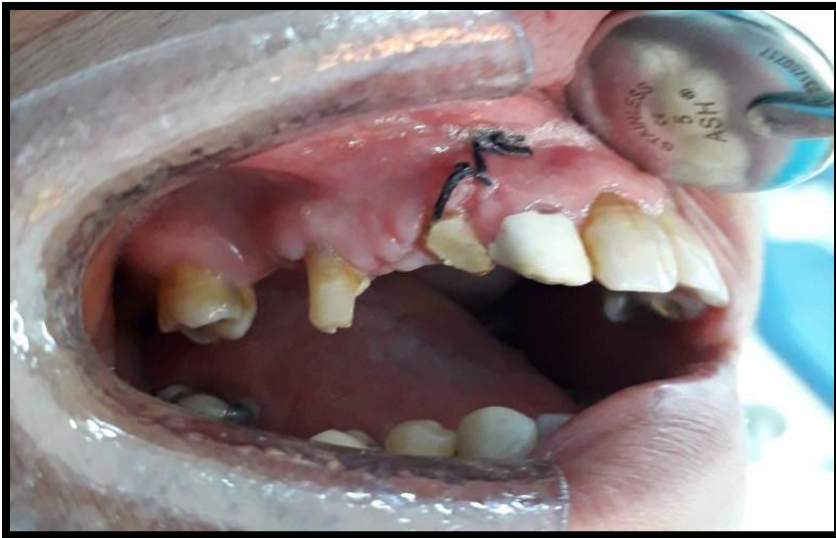Clinical appearance (duration, number, size, color, texture, related extra-oral lesions):
81.07A severely vestibular with sinus tract, on palpation egg shell cracking. no other signs or symptoms.

Radiographic appearance: radiolucent area 1cm x 1cm oval surrounded with radiopaque line apical to 43
 Type of biopsy: (Excisional biopsy) & L.A

Previous treatment: endodontic treatment
 D.D.: Radicular cyst (inflammatory cyst)
Residual cyst
Periapical granuloma

Date: 23/9/2019
 Surgeon Name & Sig: [Signature]

0927321812



Histopathology Report

Histopathology Report

Lab. No: H.1519/2019
Patient's name: [Redacted] 48 yrs. Sex: <input checked="" type="checkbox"/> Male Date: 23/10/2019
Referred by:
Nature of specimen: Soft tissue swelling (right upper canine).

MACROSCOPIC DESCRIPTION:

A small irregular grey white soft to firm tissue mass measures 1.1x1x0.8 cm in size. On C/S: Soft, light brownish.


MICROSCOPIC DESCRIPTION:


- Well-circumscribed tissue mass covered partially by stratified squamous epithelium with underlying active vascular stroma contains fibrohistiocytic cells and chronic inflammatory cells are seen beneath the epithelium along with small amount of neo-formed bone areas of calcification along with lymphocyte aggregation. There is no evidence of atypical or malignant changes.

DIAGNOSIS:

The picture is consistent with Periapical (radicular) cyst.

CONSULTANT: Dr. Ahmed Benhasouna, PhD (UK)



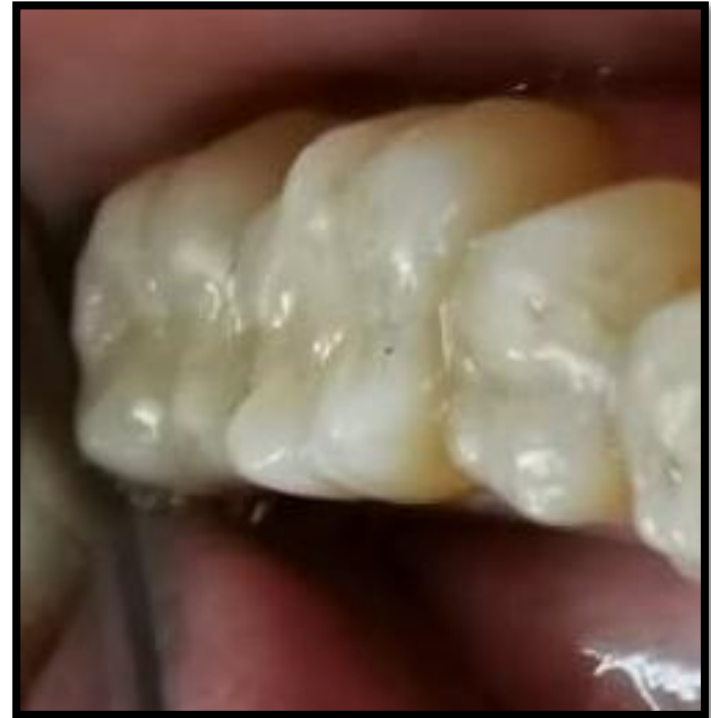
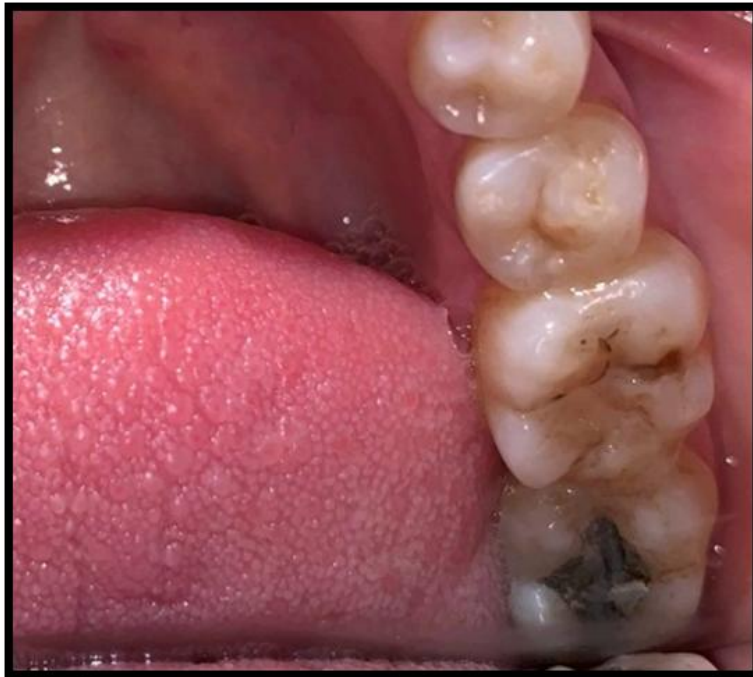
العنوان: الجييزة - البركة - شارع بن شنوان | داخل العيادات سابقا
جميع الأطباء أعضاء هيئة تدريسي بالمرکز
جامعة بنغازي مركز الخدمات الطبية التخصصية

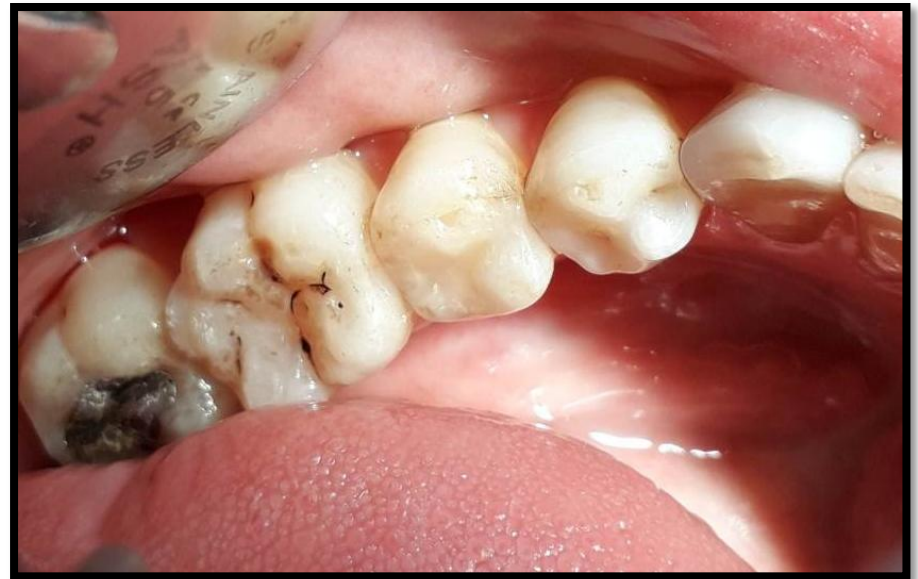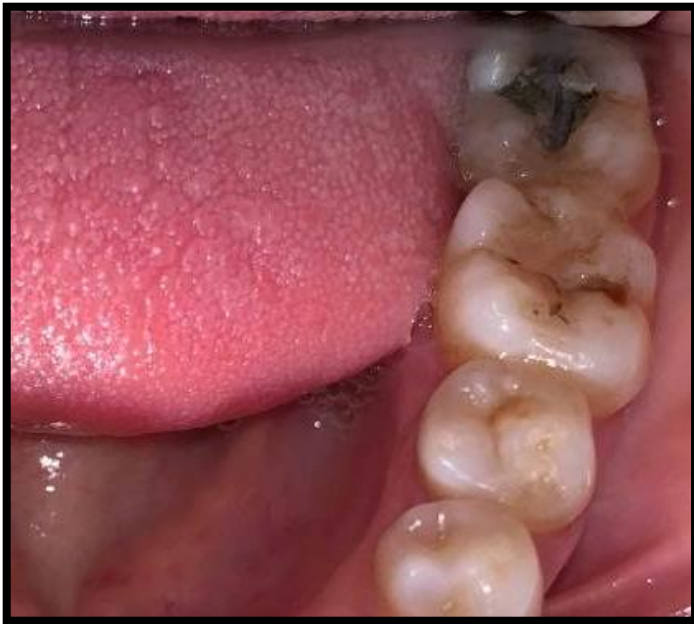Reception: 0612240773 | هاتف الاستقبال الرئيسي
P. box: 7074 | Tel: 0612240774

Phase III : Filing restoration

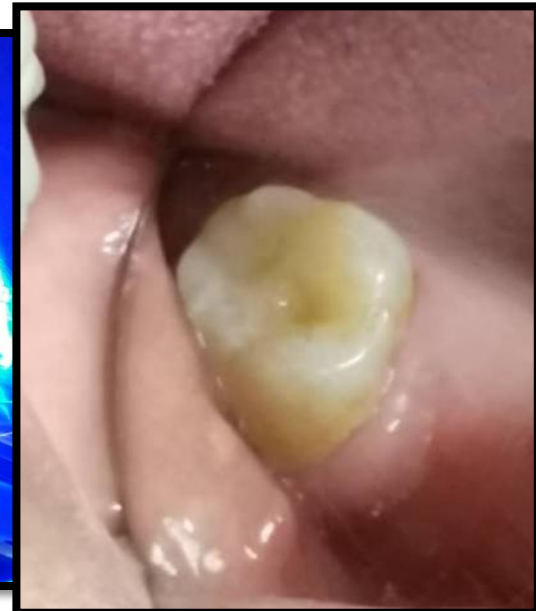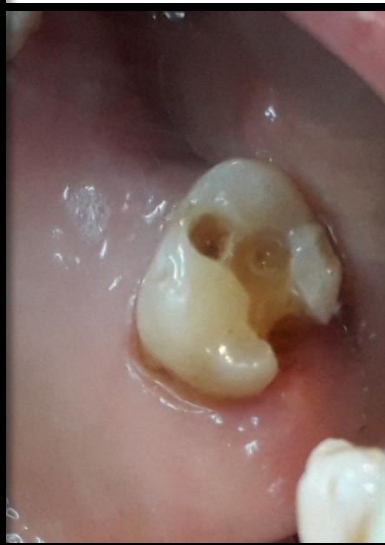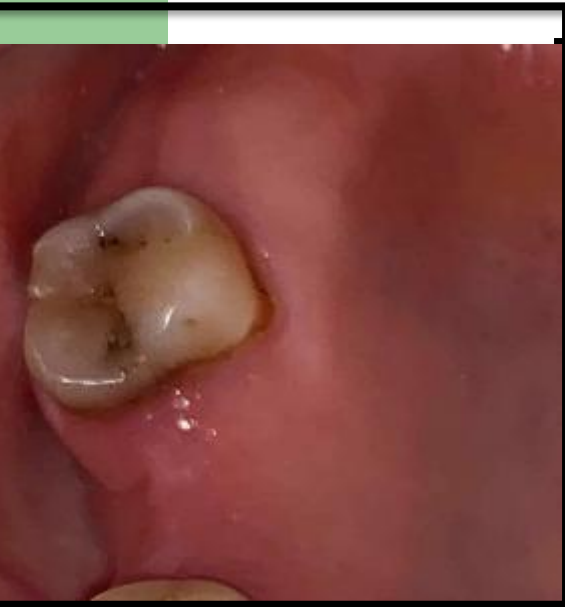
lower Lt posterior 1st molar & 2nd molar .
Class I



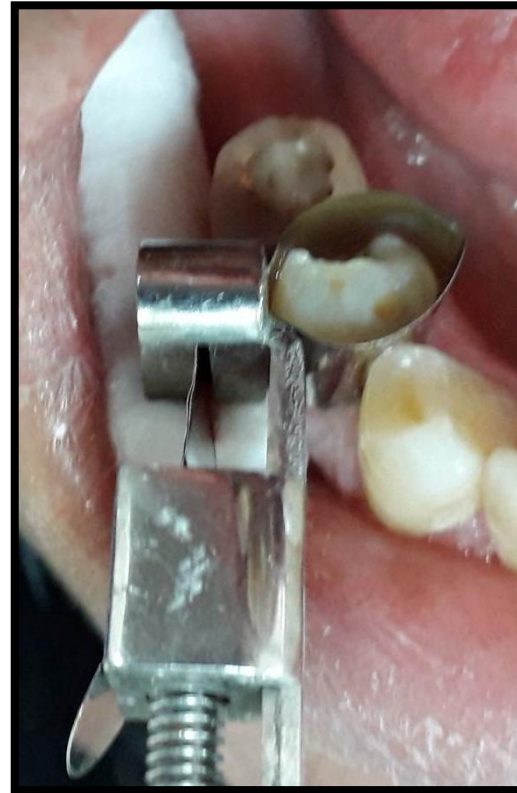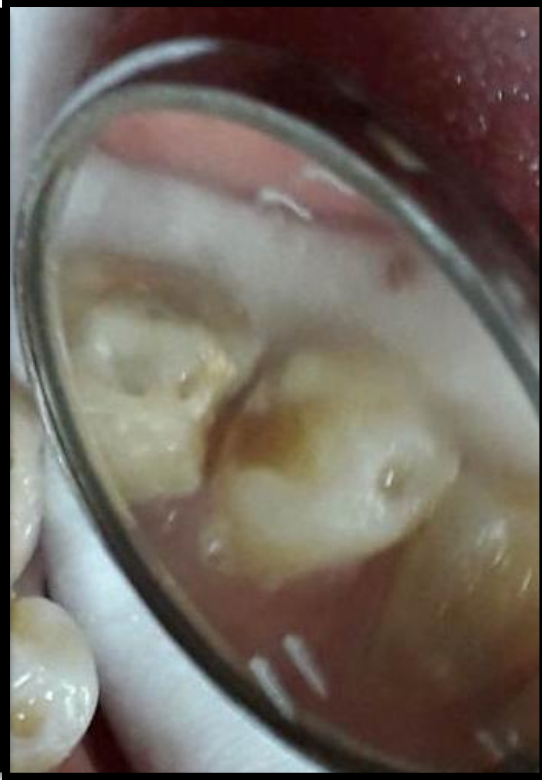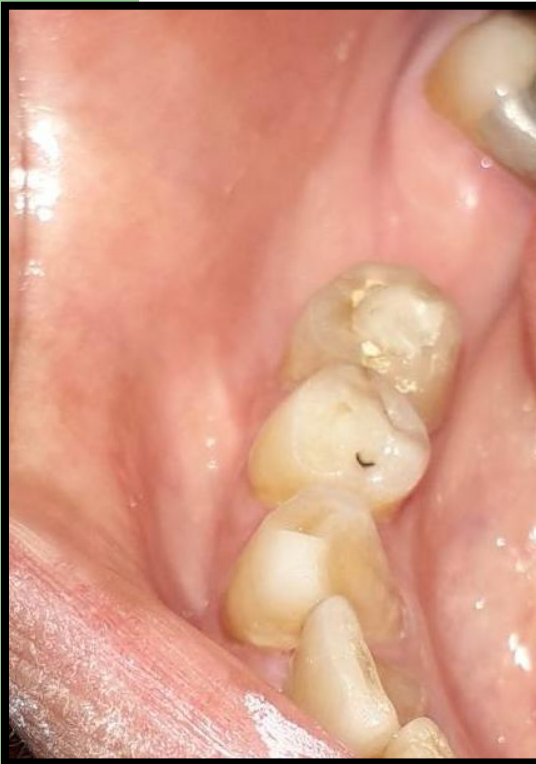lower Lt posterior 2nd premolar Class I



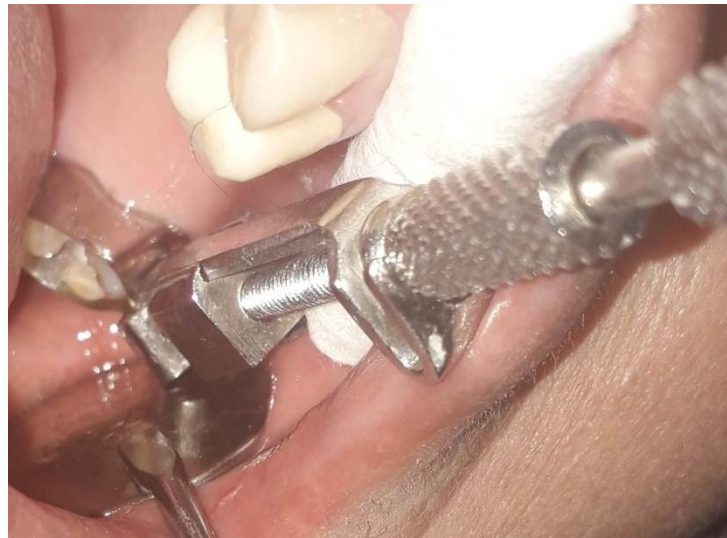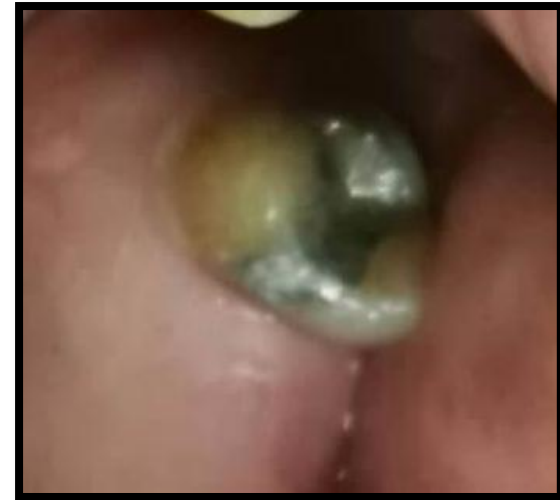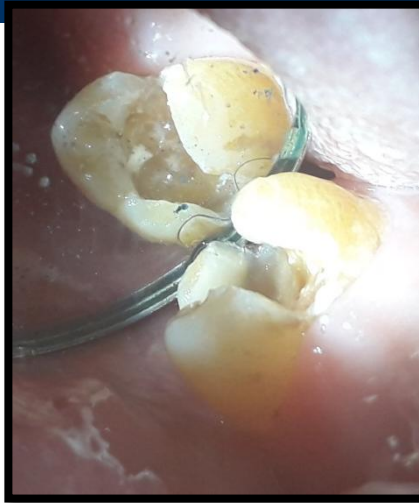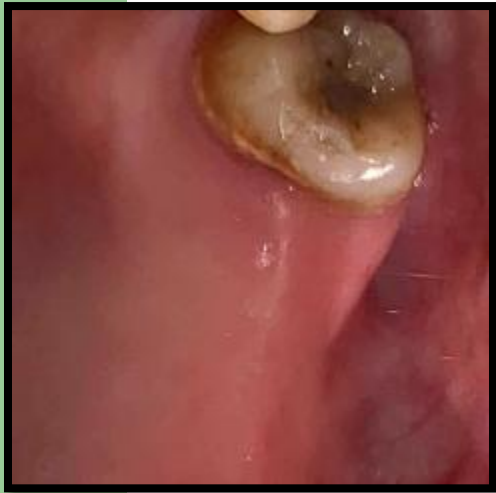Upper Rt 2nd Molar Class II



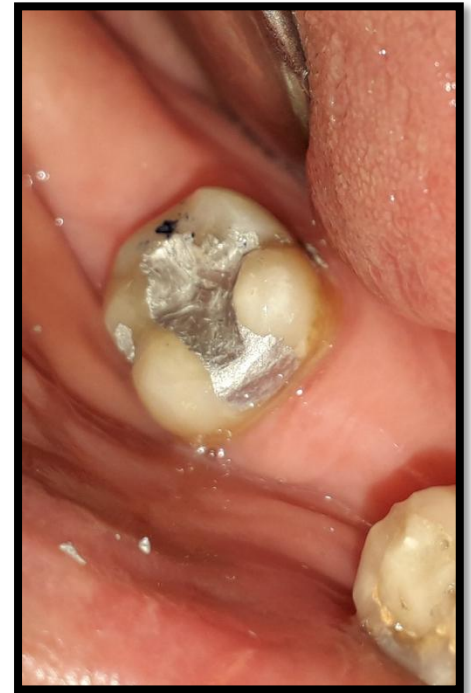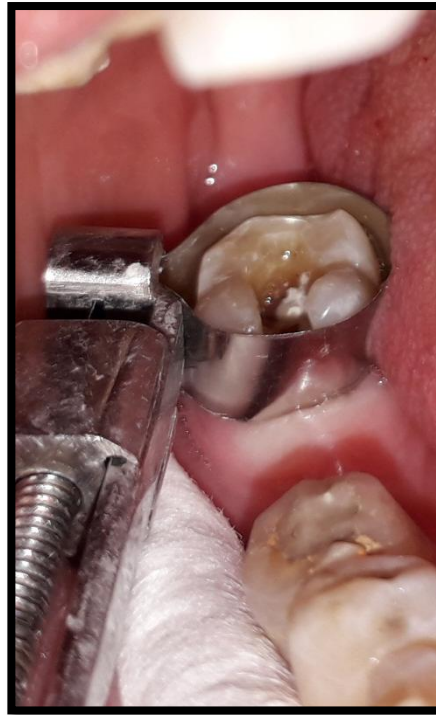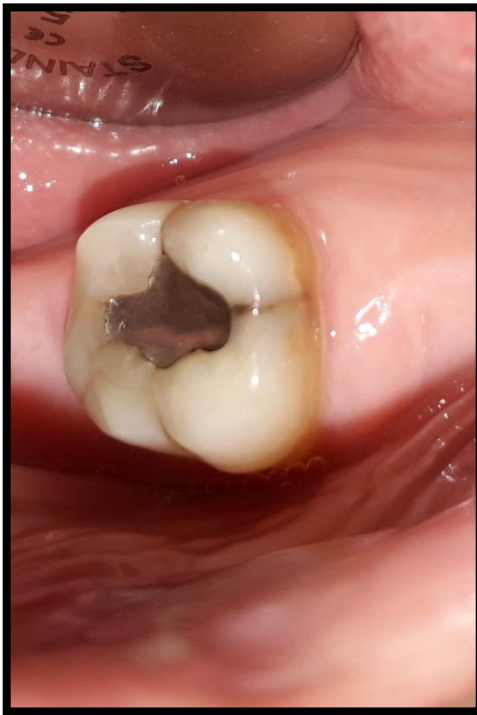Lower Rt 1st premolar Class II



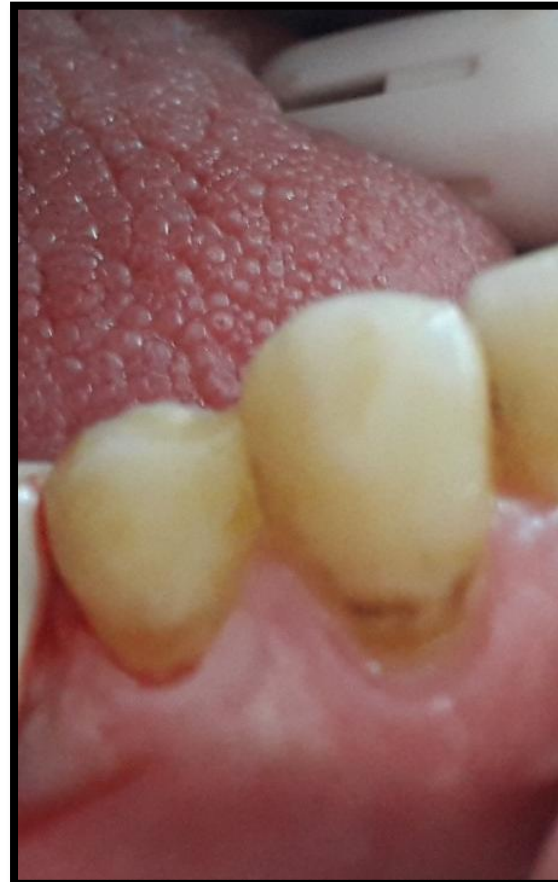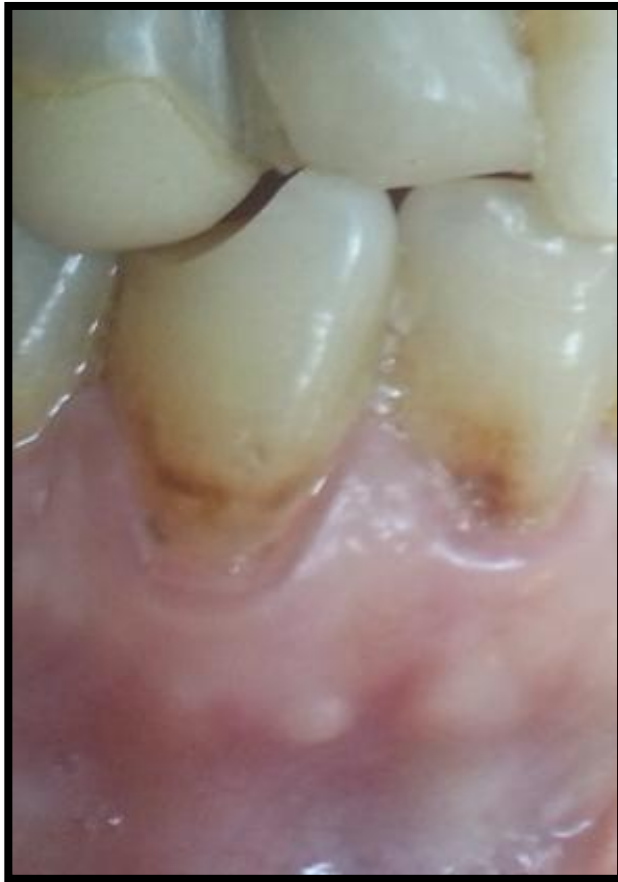Upper Lt 3rd Molar Amalgam Class II



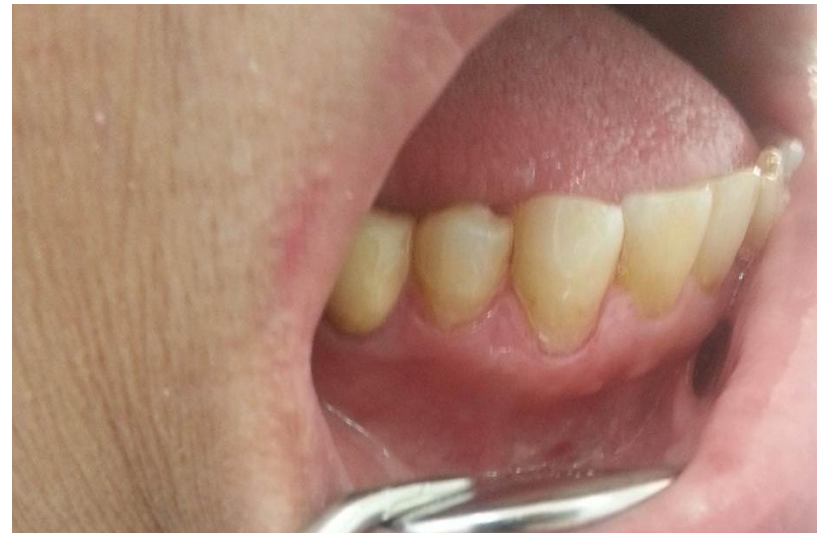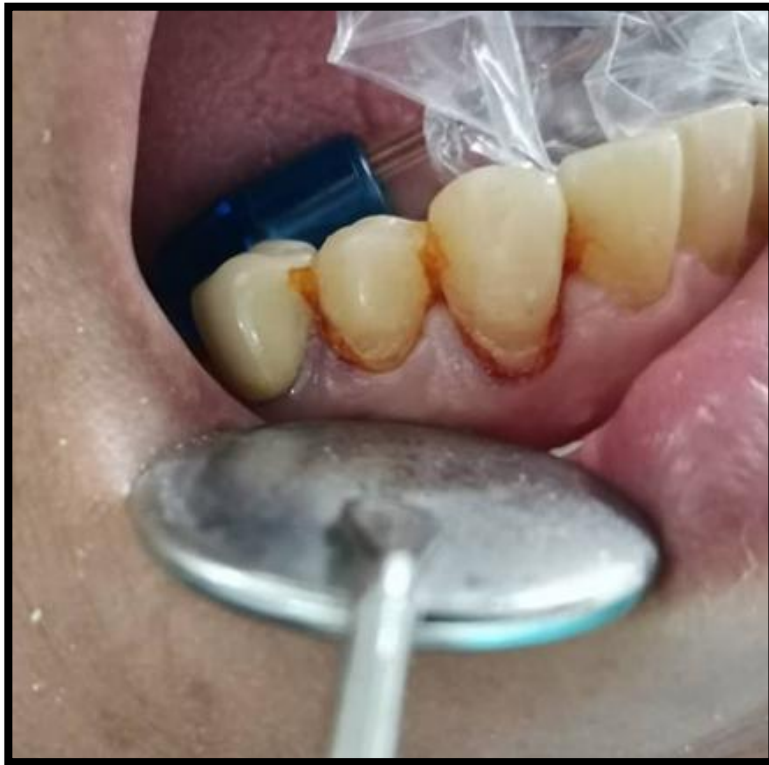Lower Rt 2nd Molar Class II



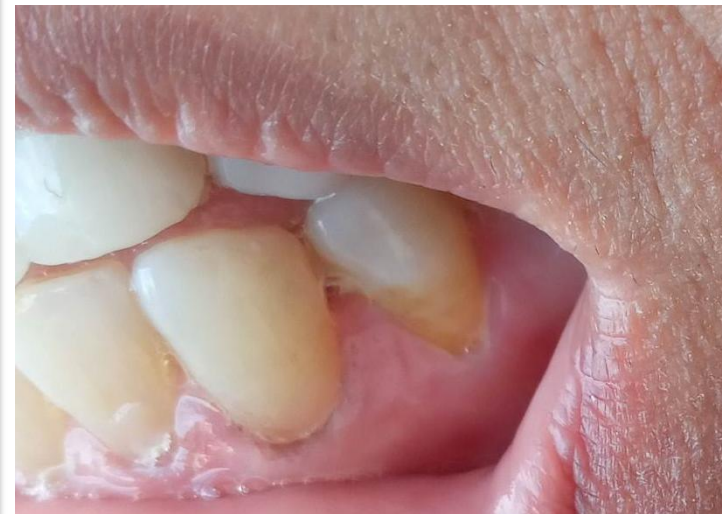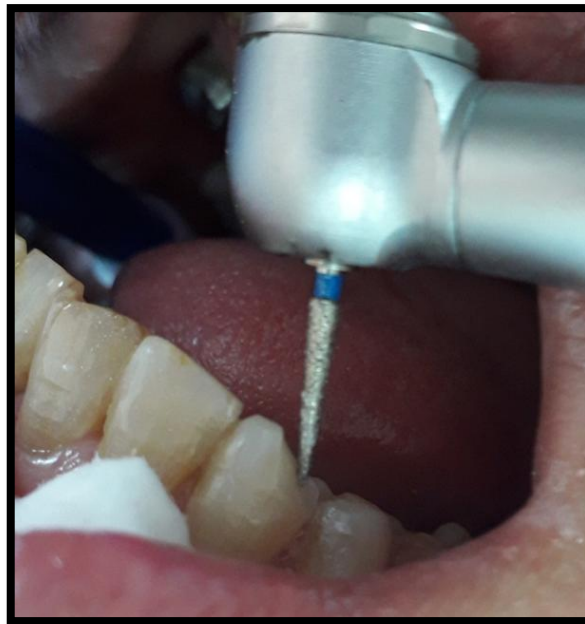Lower Rt Canine Class VI



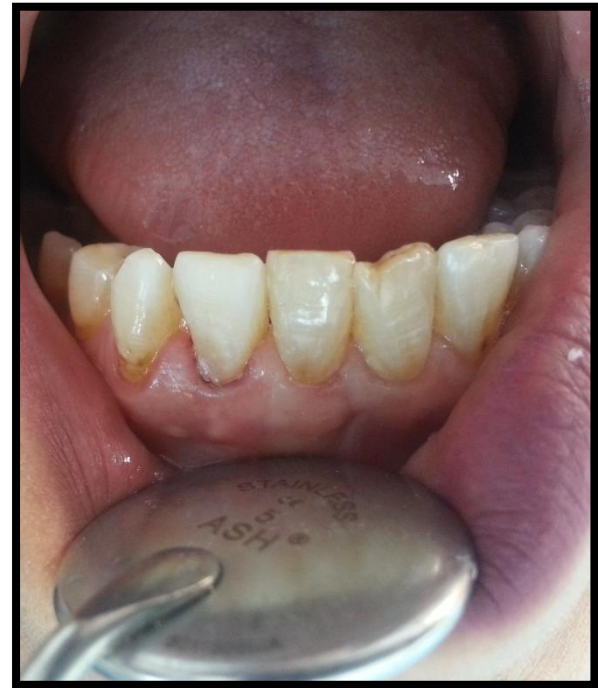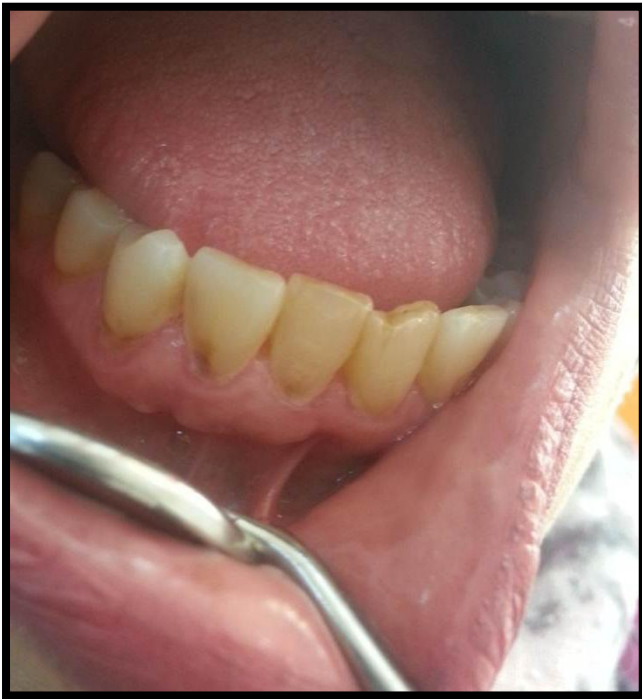
Lower Rt Canine & 2nd premolar Class V.



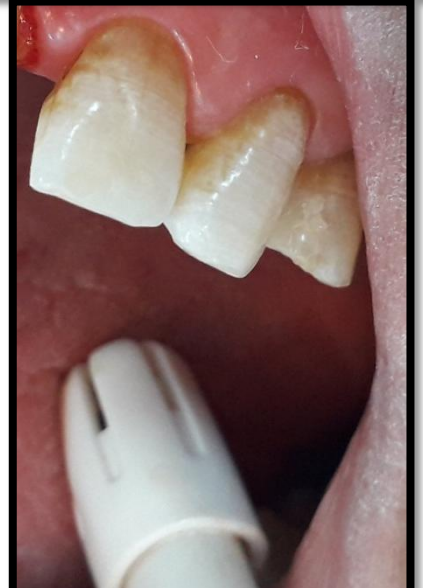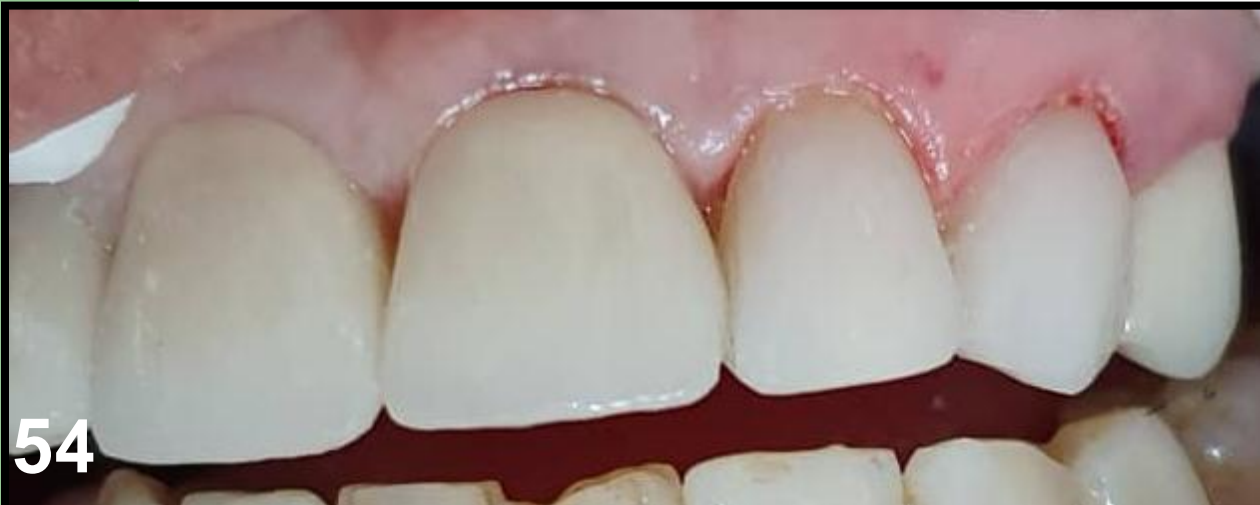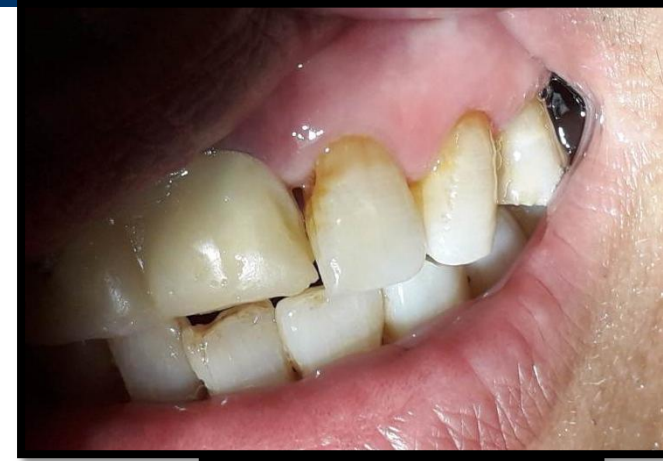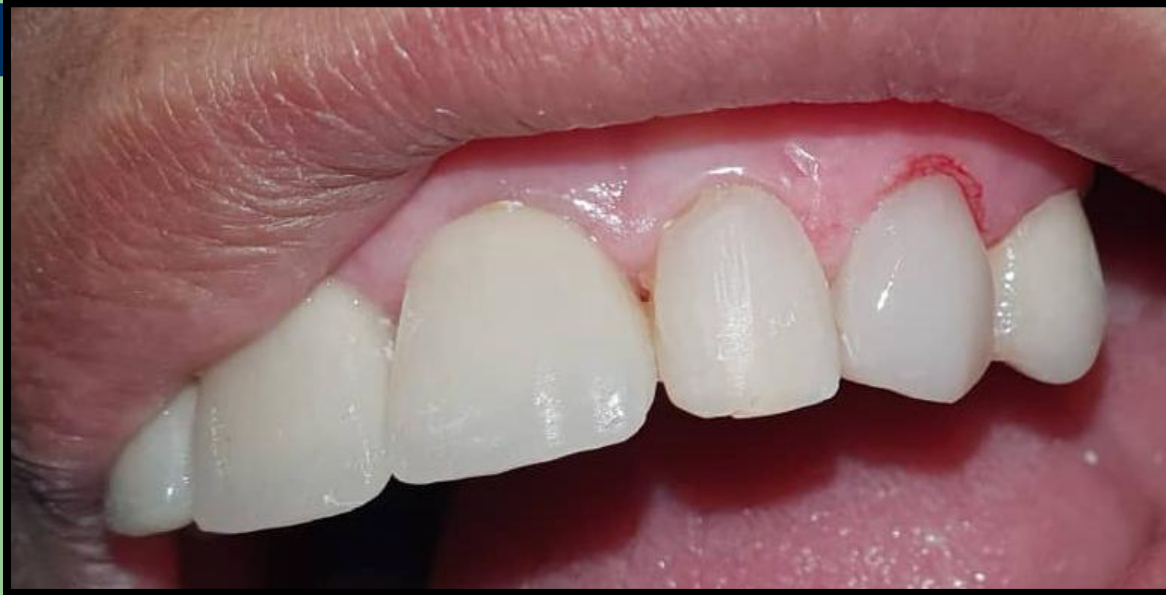Lower Lt Canine Class V & IV



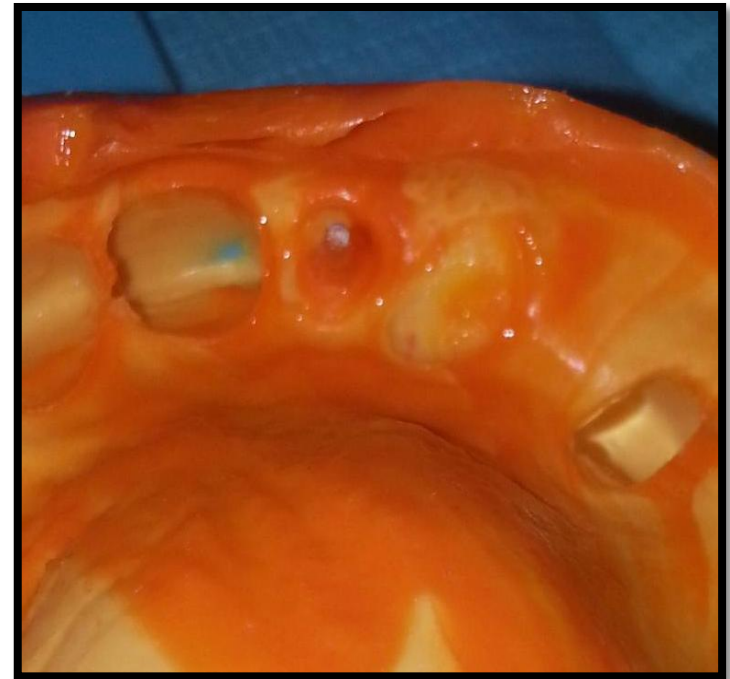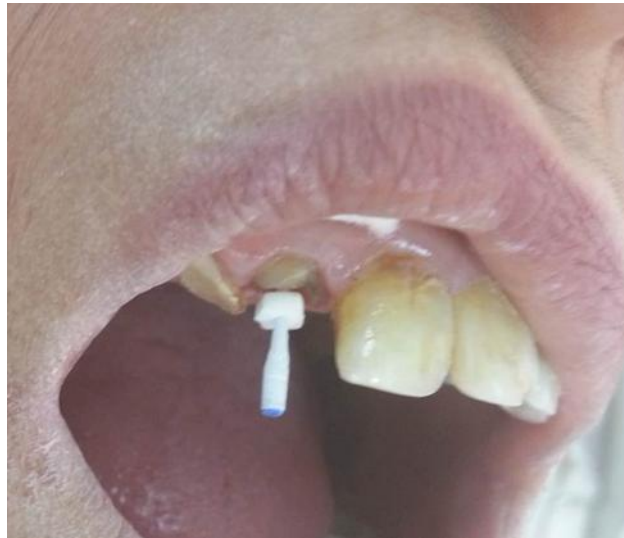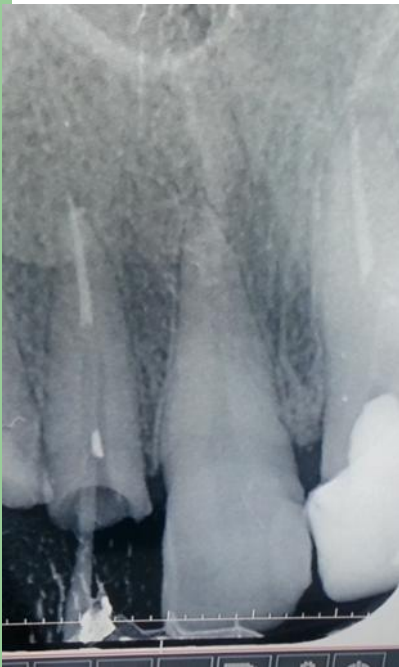Lower Rt Central Class V



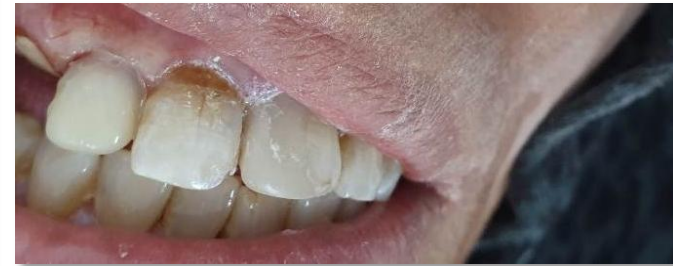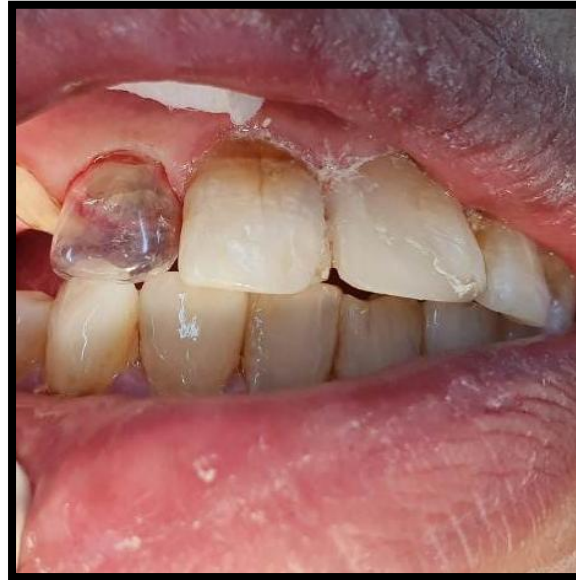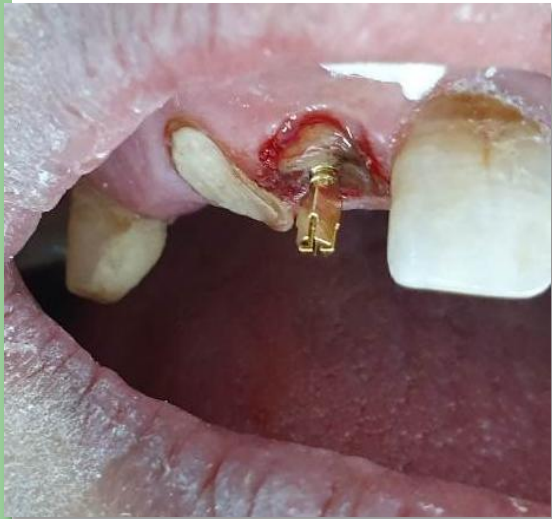Composite Veneer



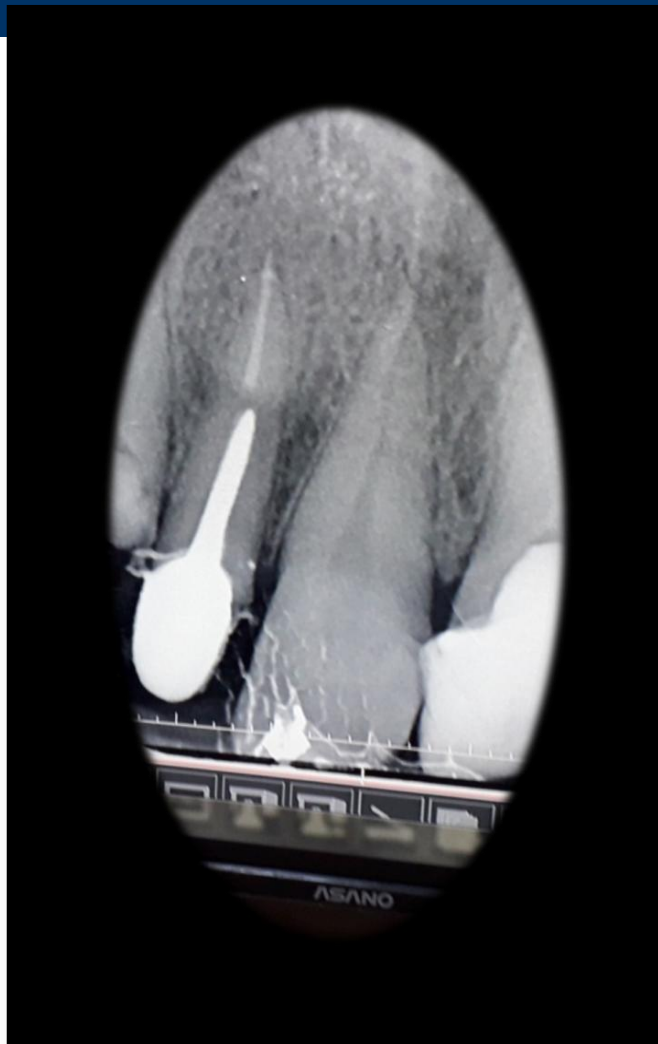
Custom Made Post , Core And E -Max crown .



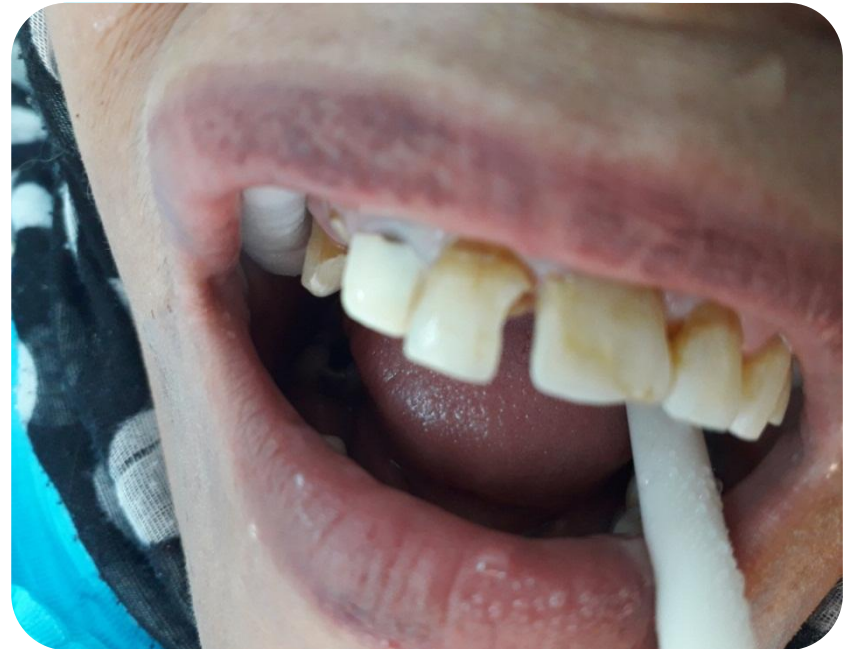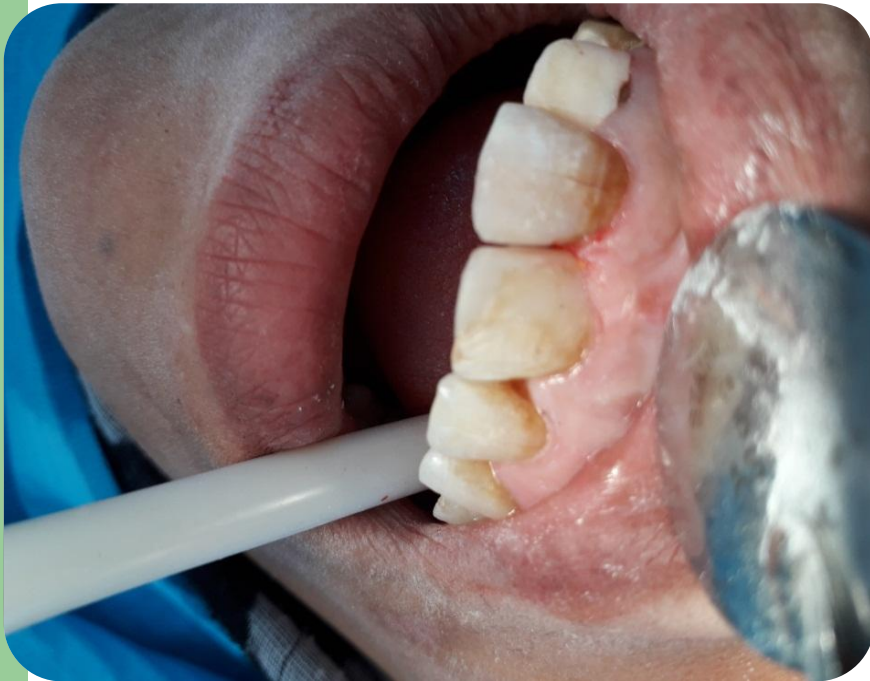Temporary Post and Crown



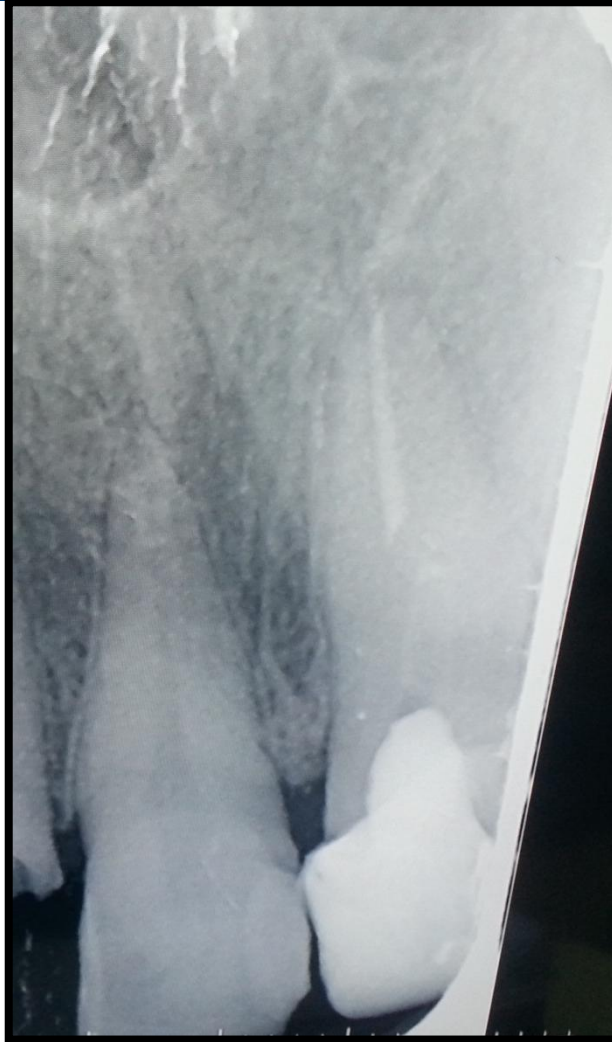Post Placement and Cementation



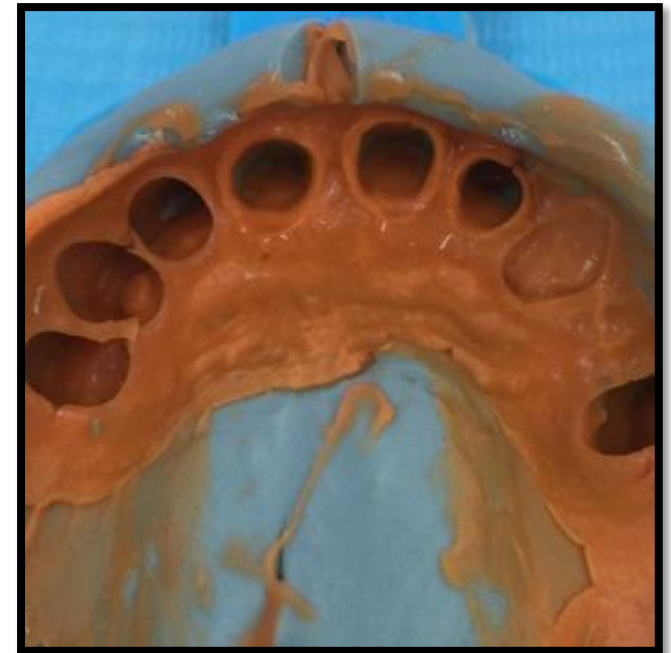
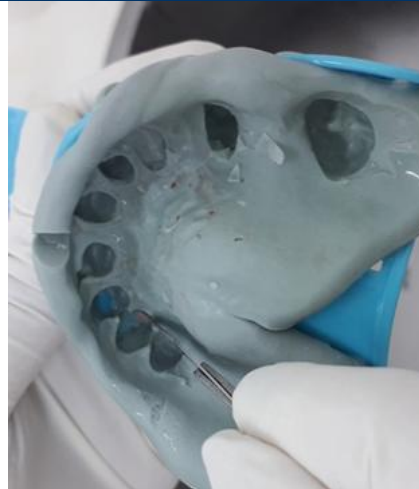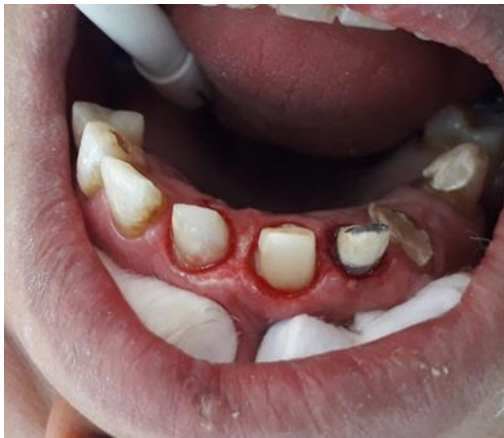Composite build up



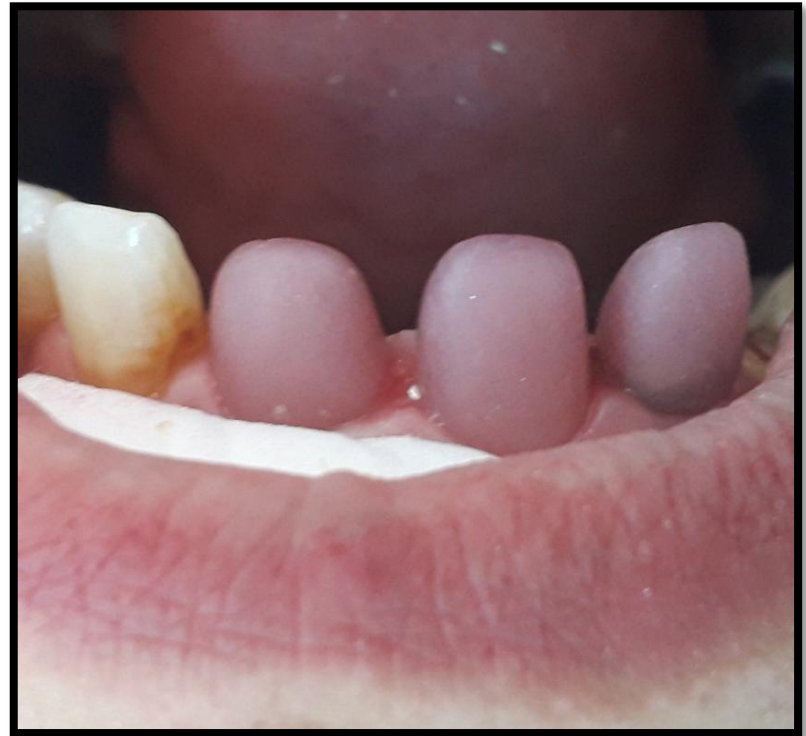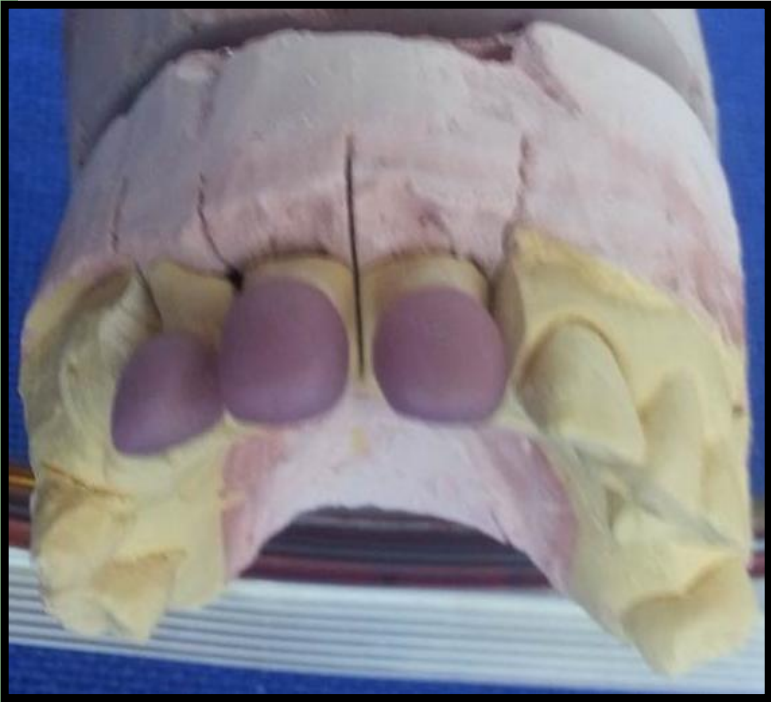Post and core



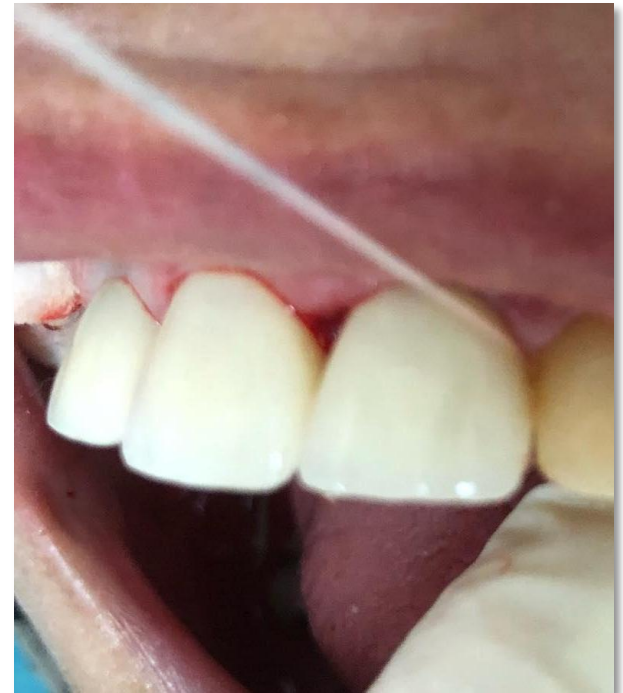
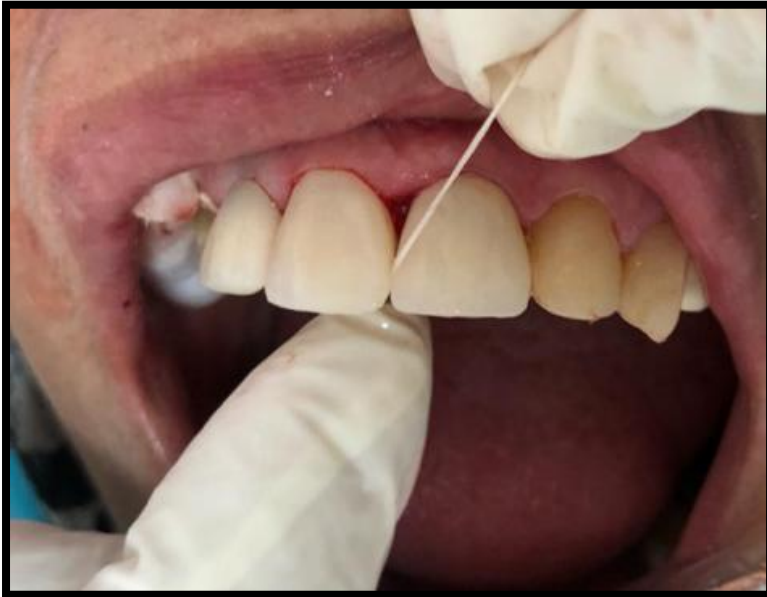Final Impression



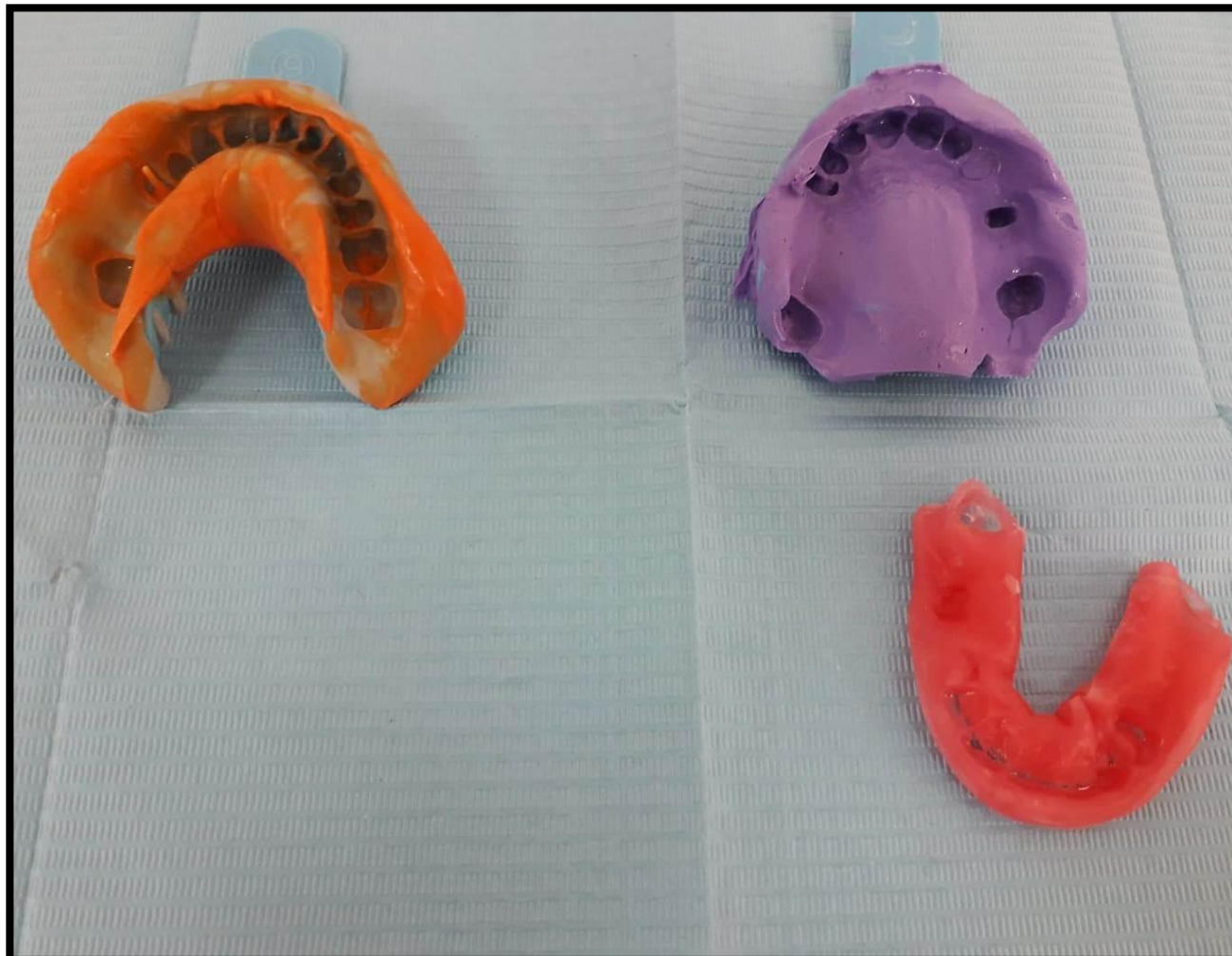
Try in

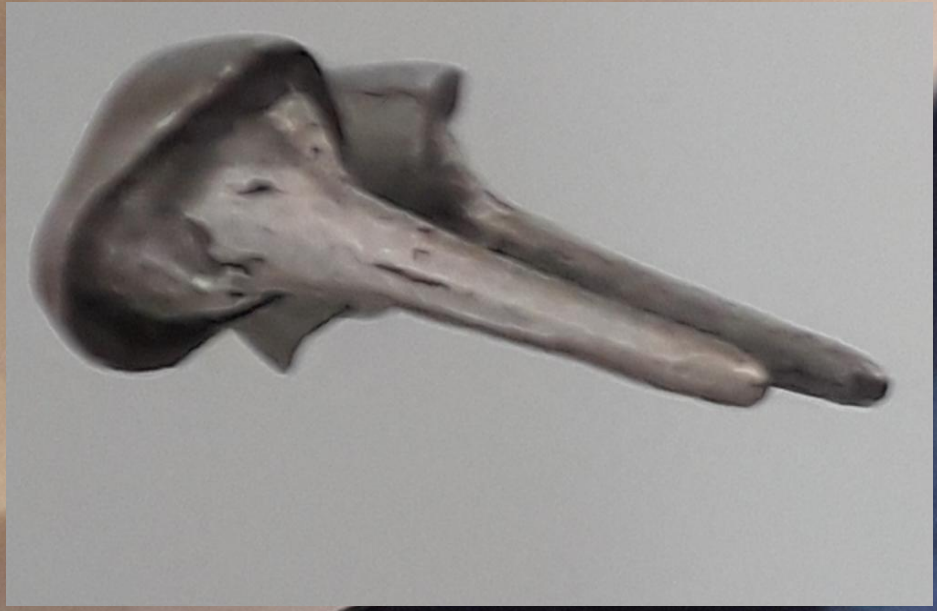
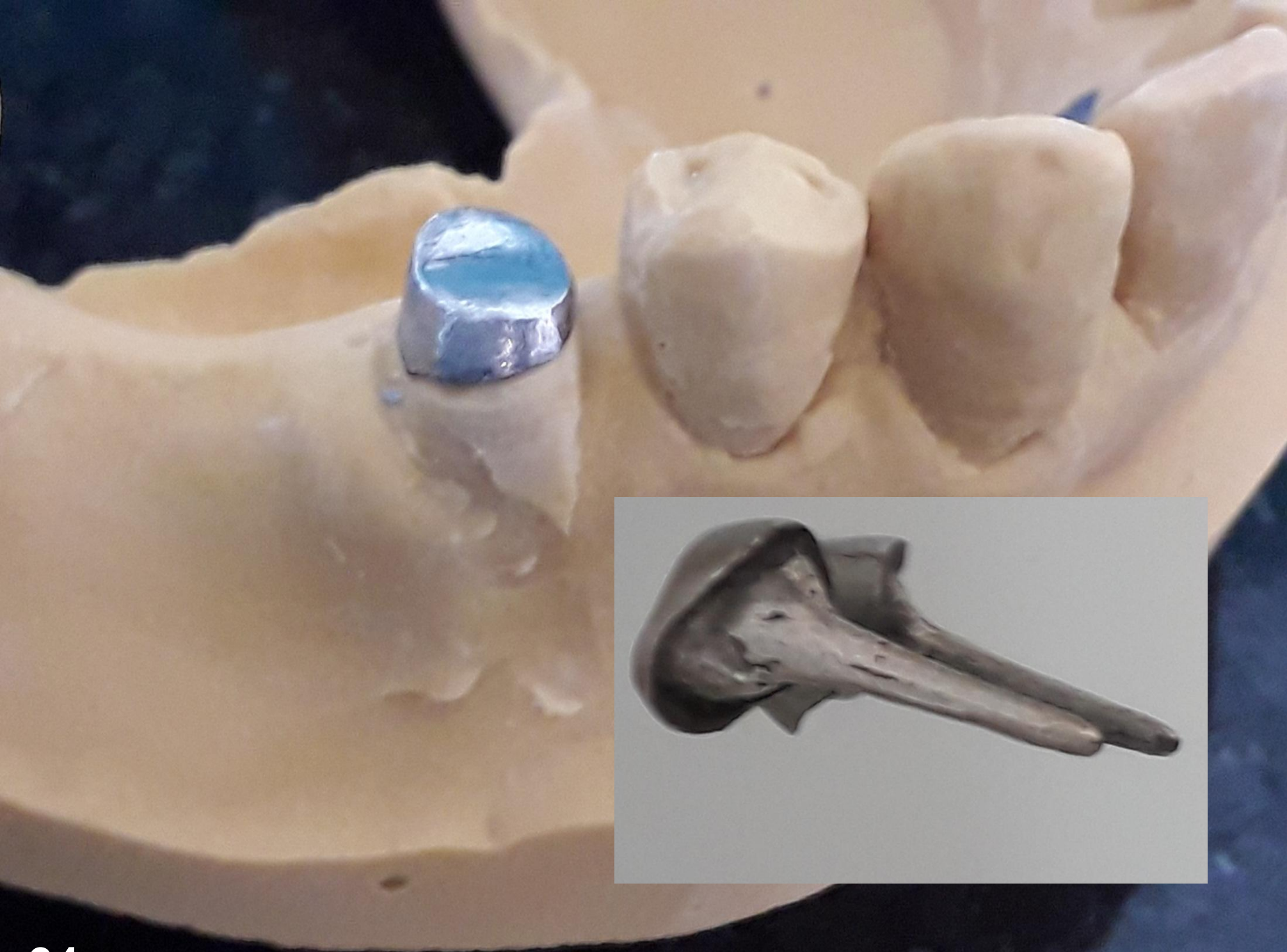
Insertion

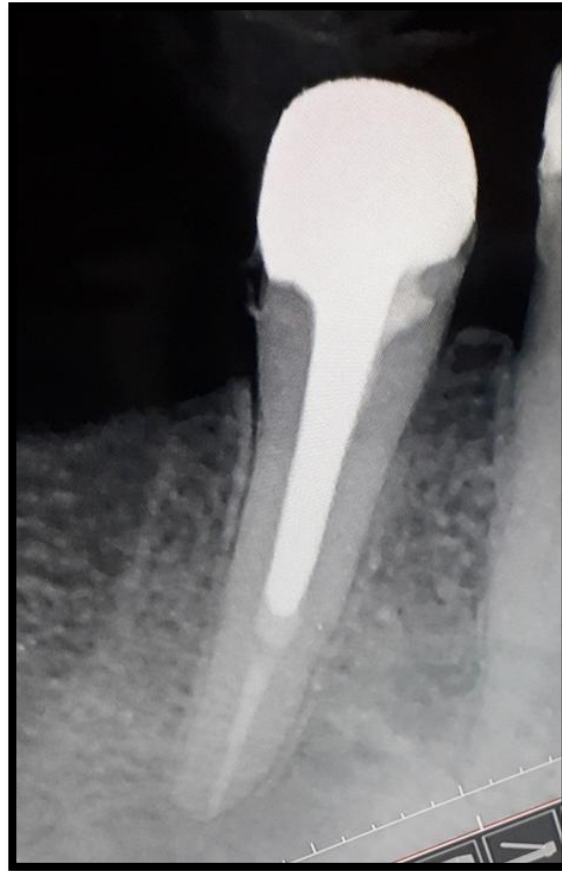


Custom Made Post ,Core And PFM Crown .

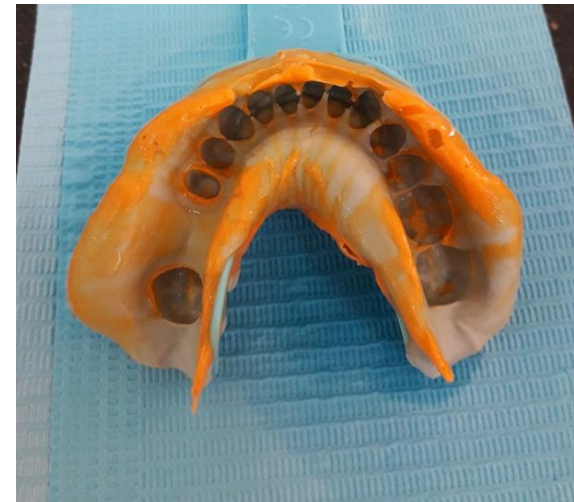
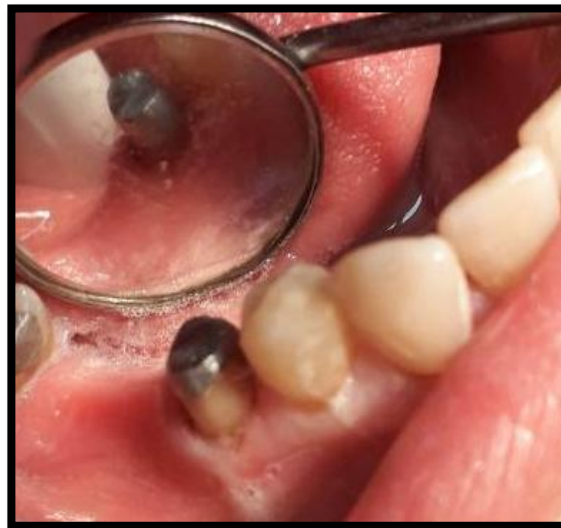
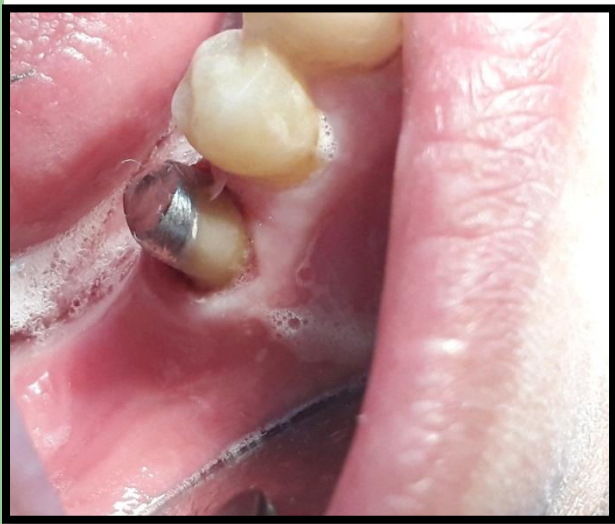

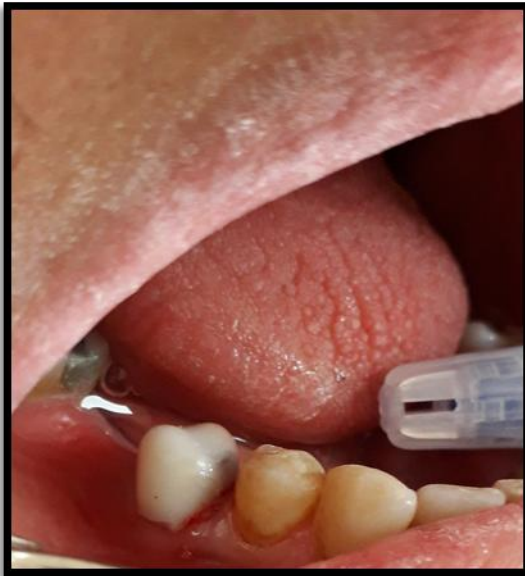
Post Placement and Cementation



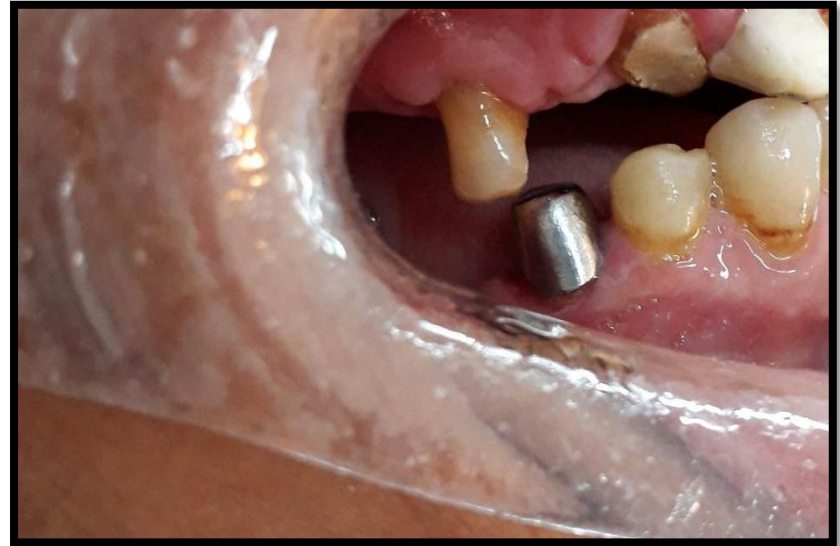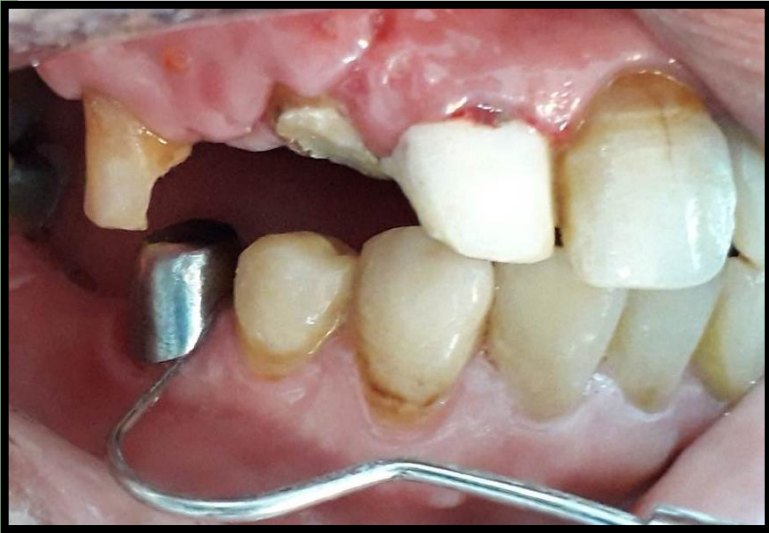Tooth preparation and Final impression



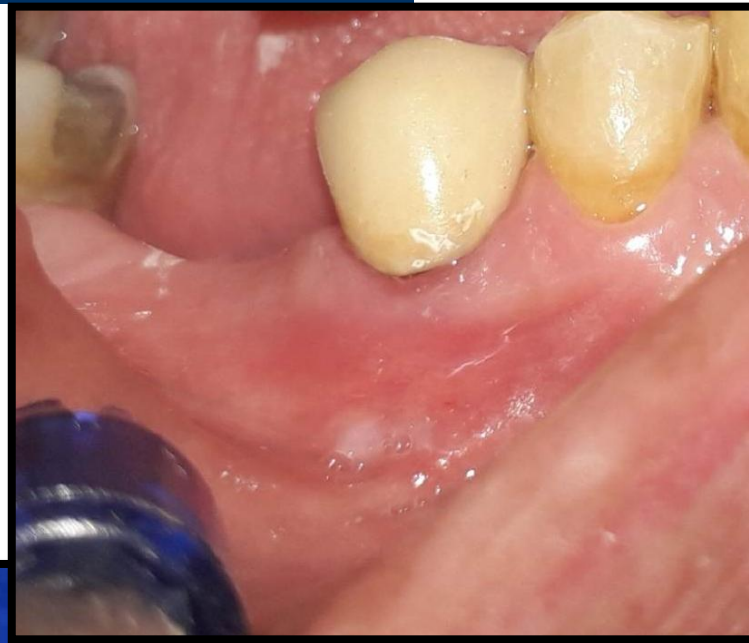
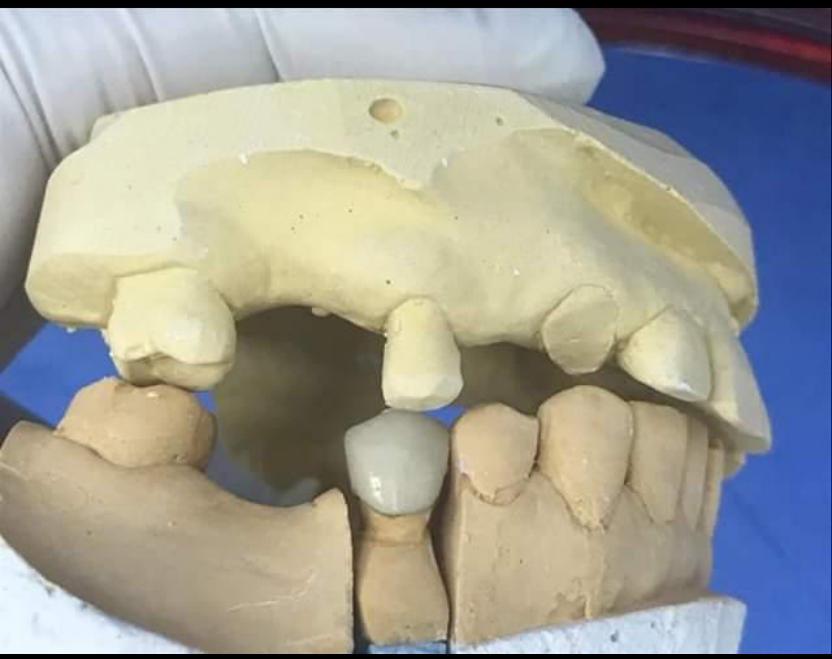Temporary Crown



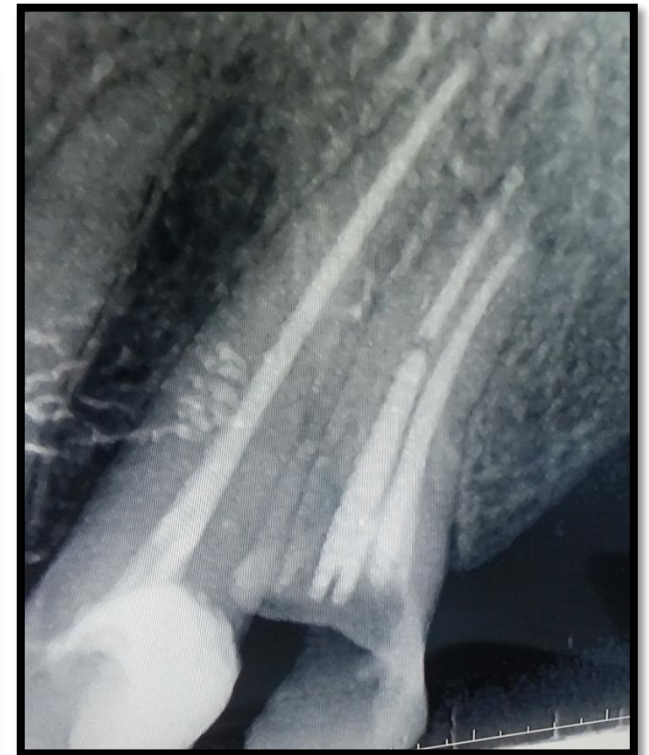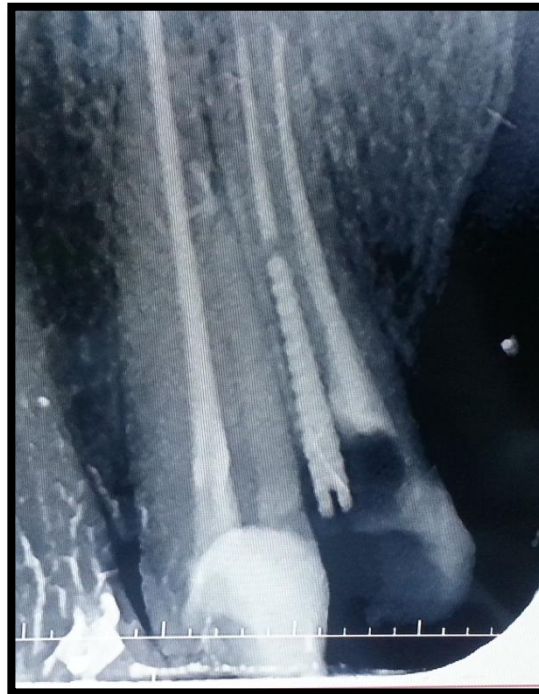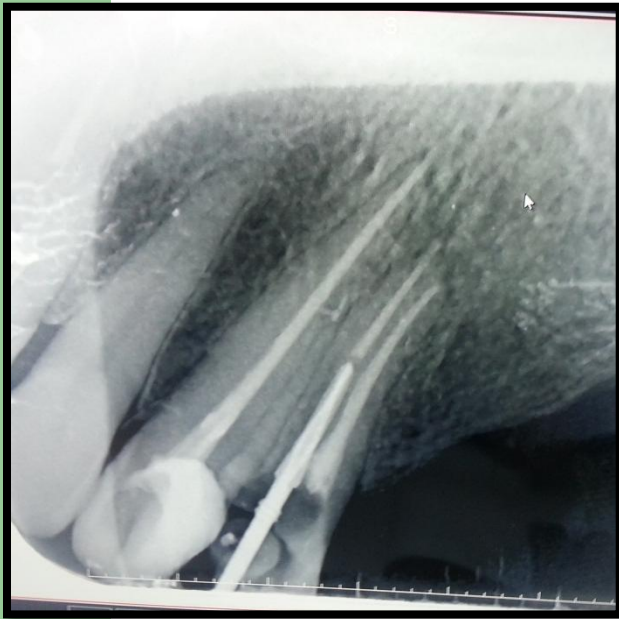
Metal Try In



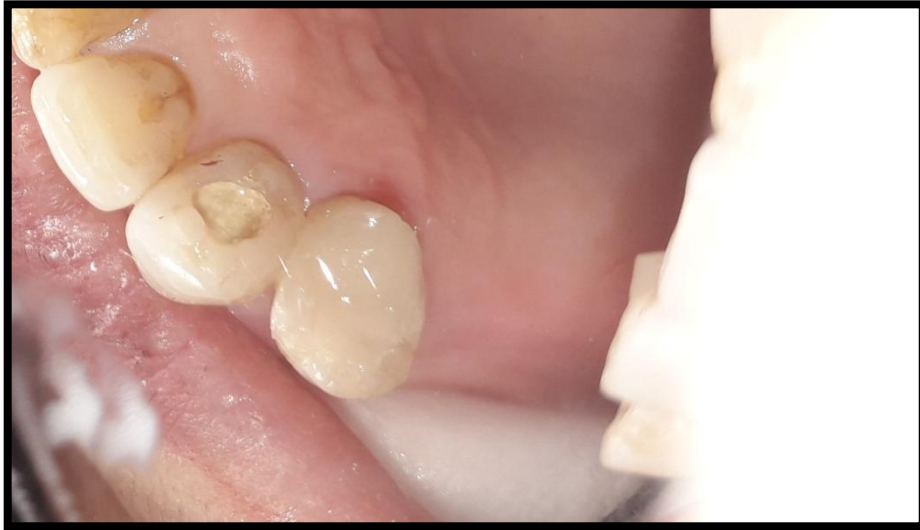Insertion

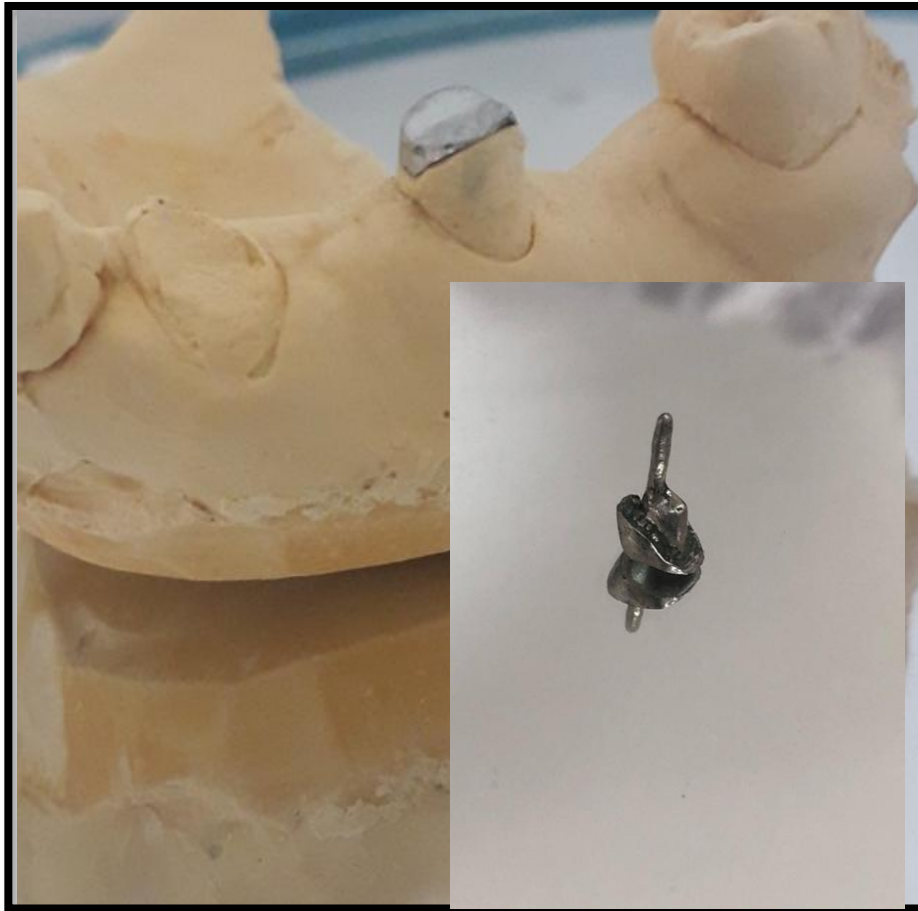

Post Space Preparation & Placement

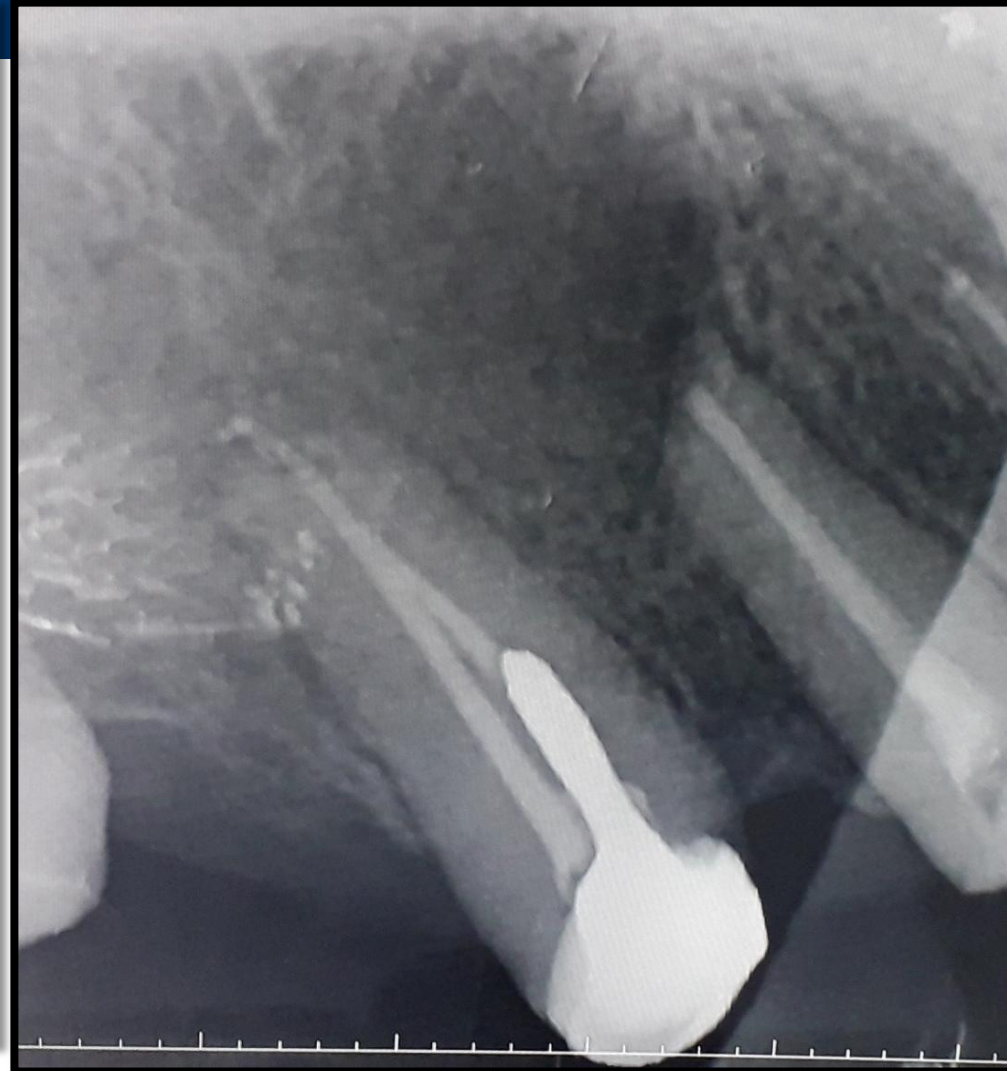
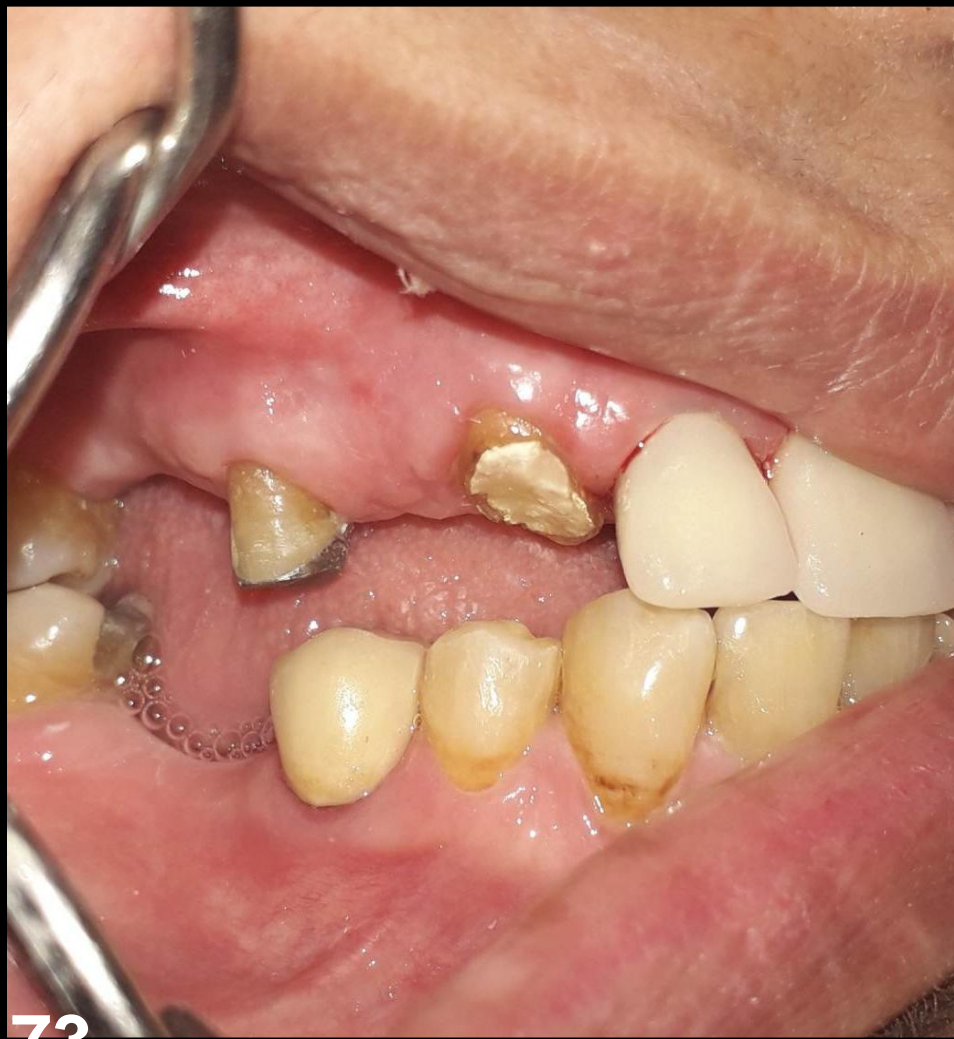

Composite build up

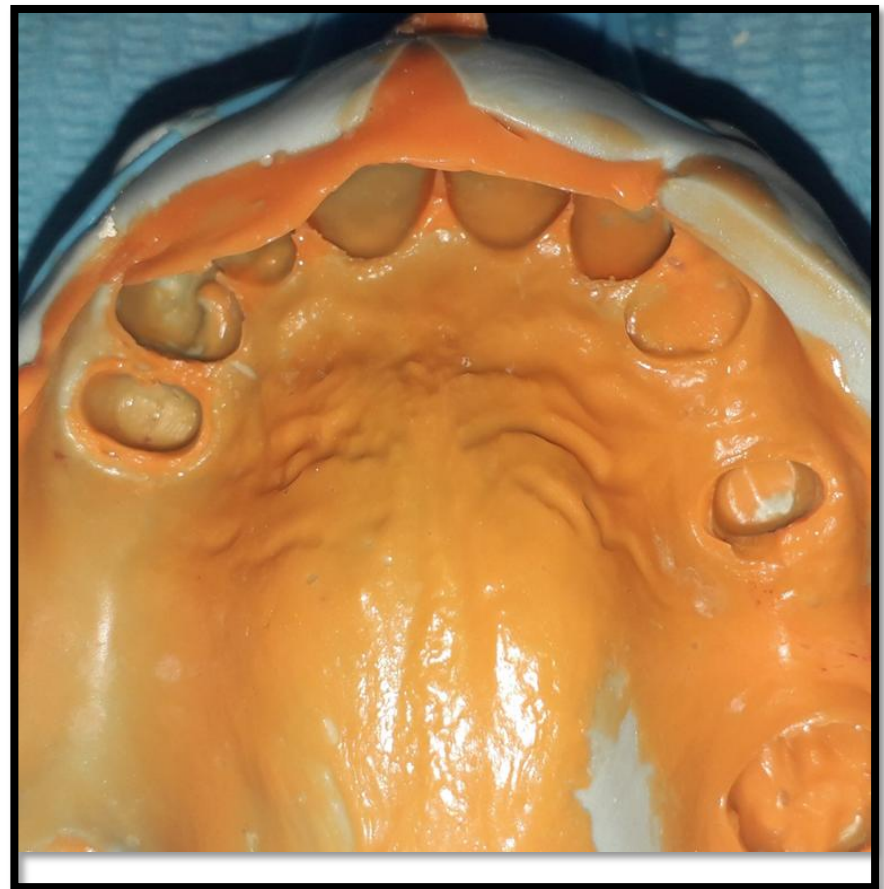
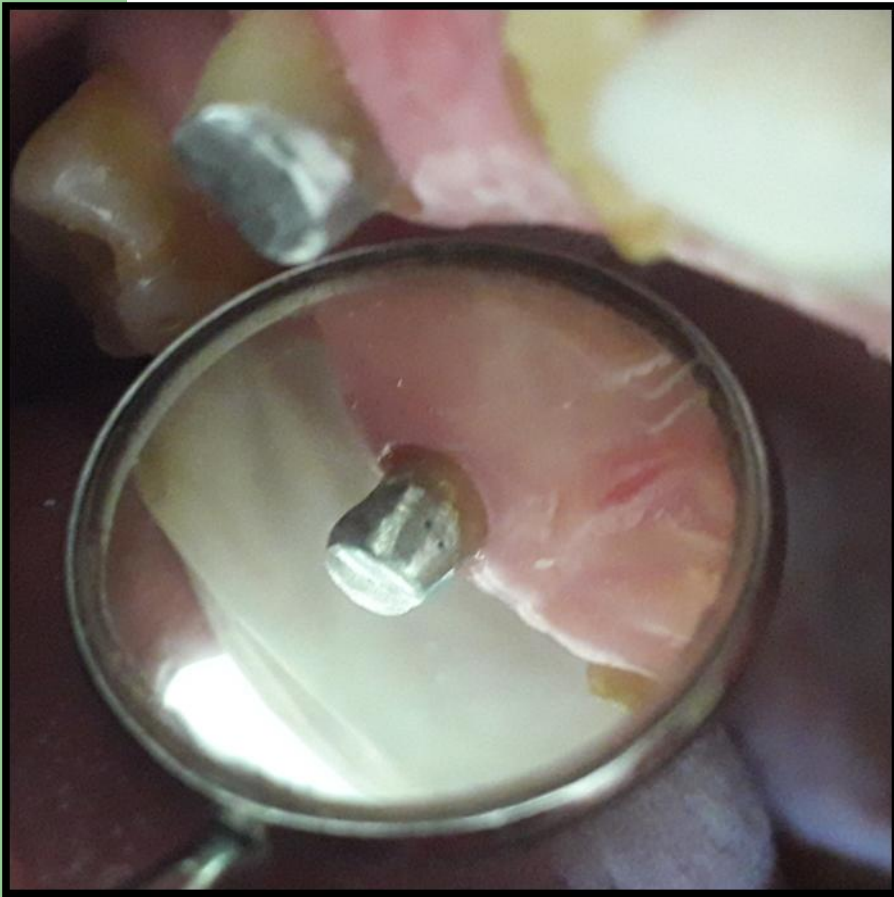



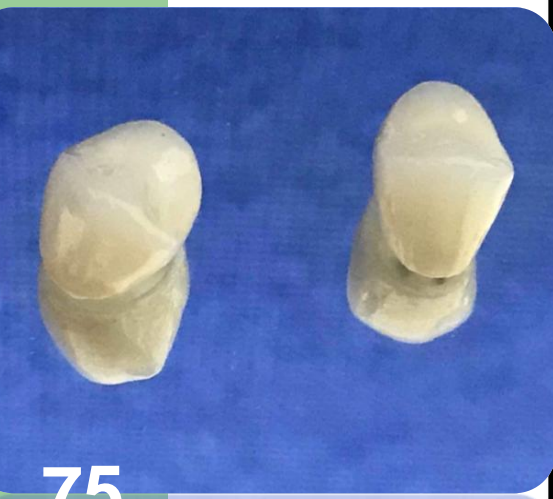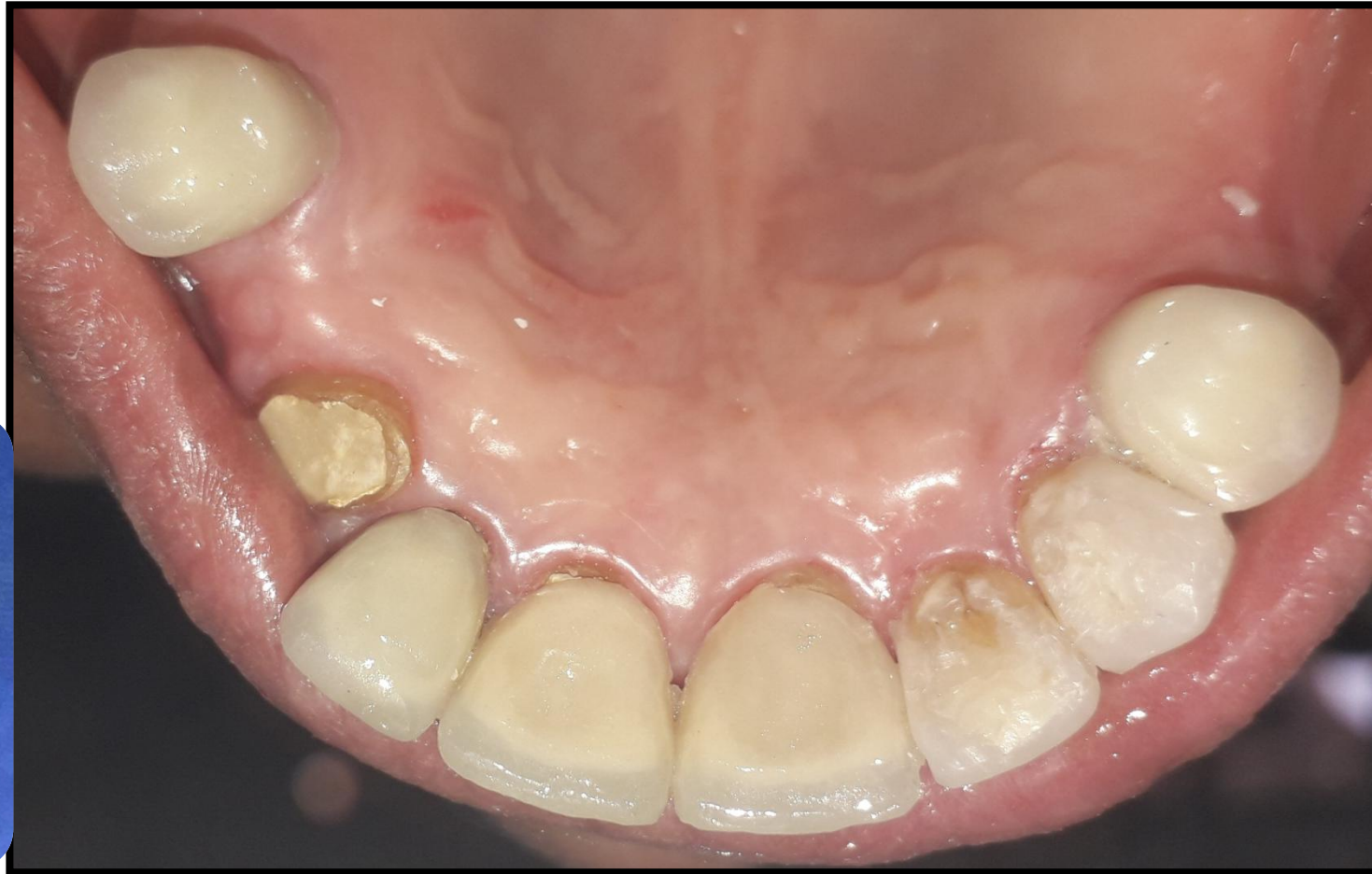Post Placement and Cementation



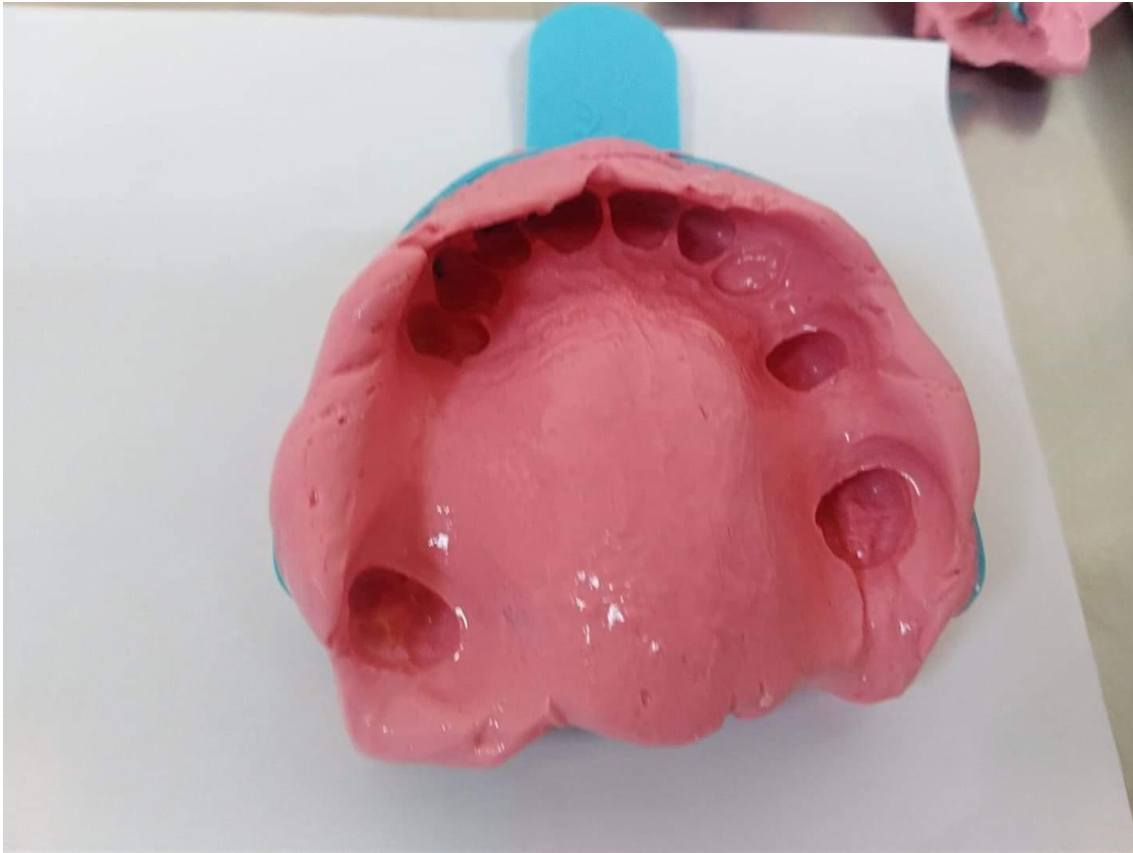
Tooth preparation and Final impression



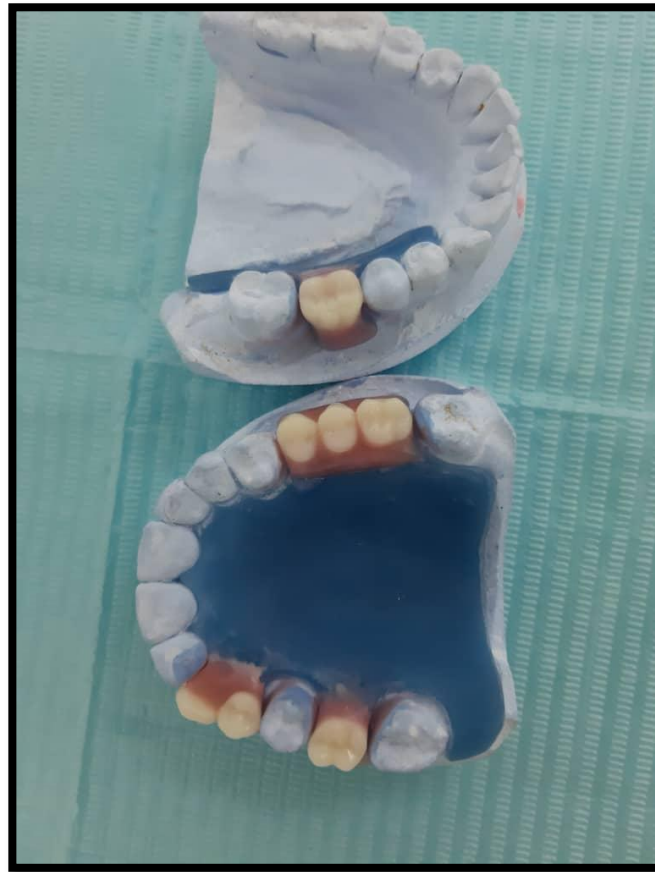Insertion



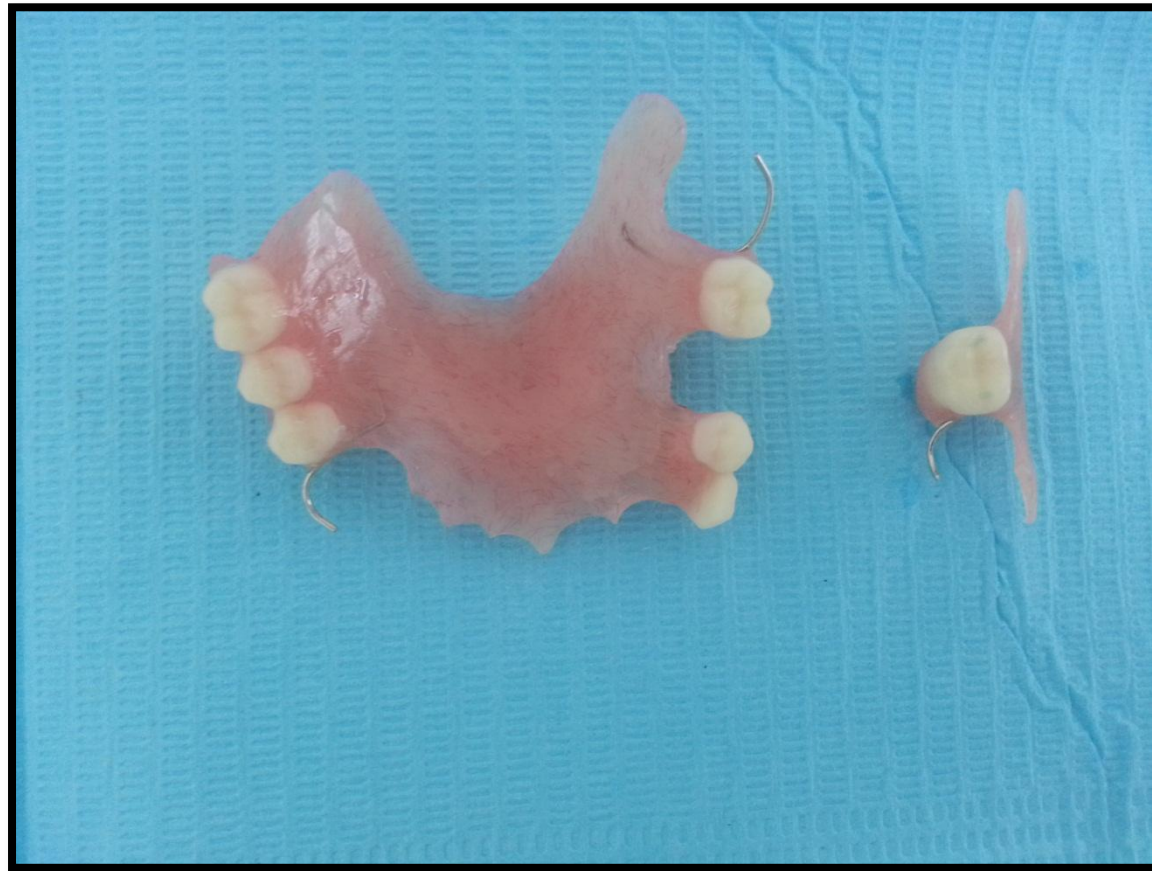
Primary impression



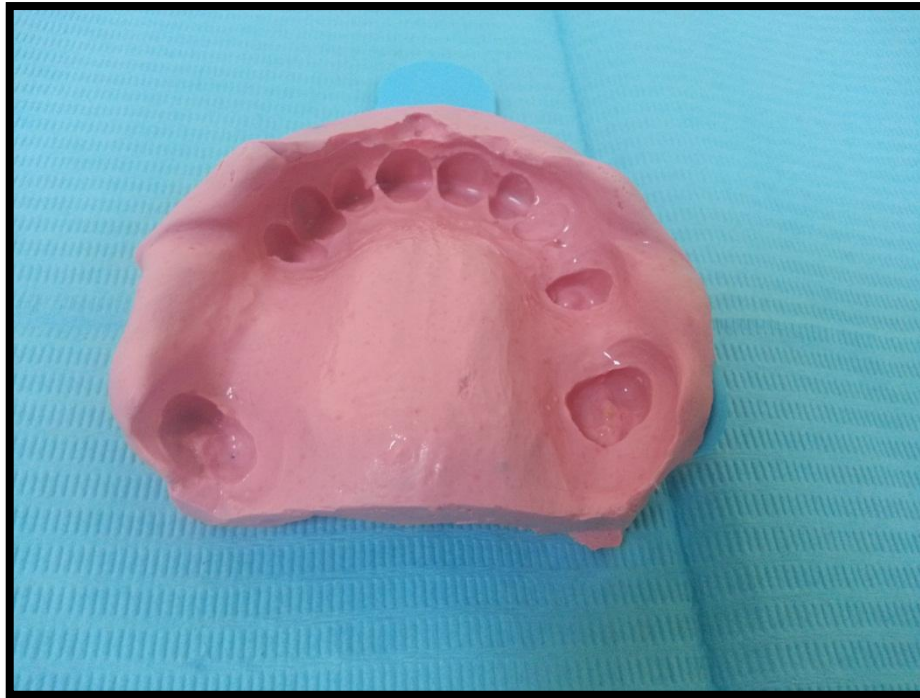Try in



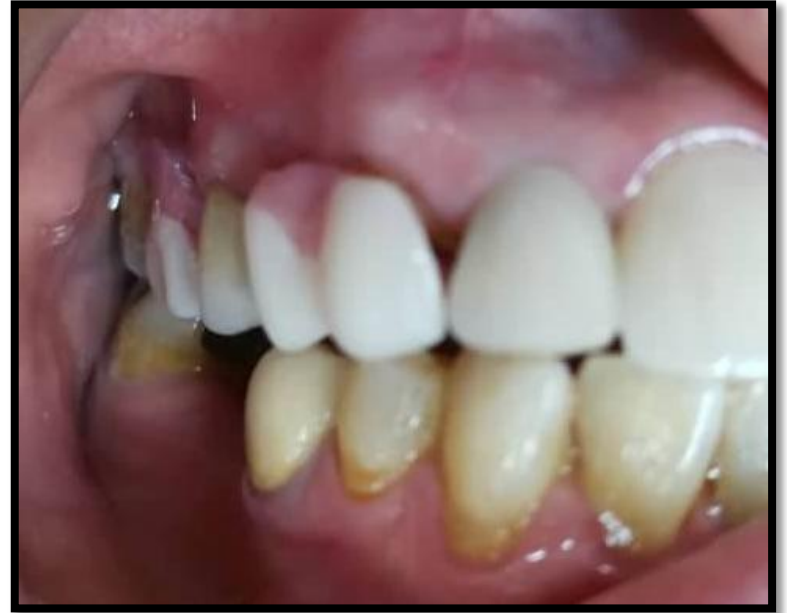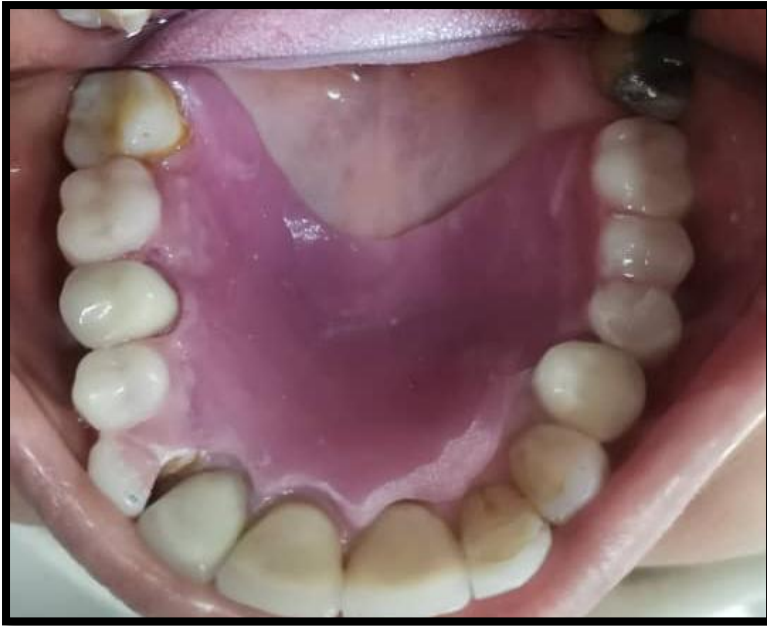Insertion

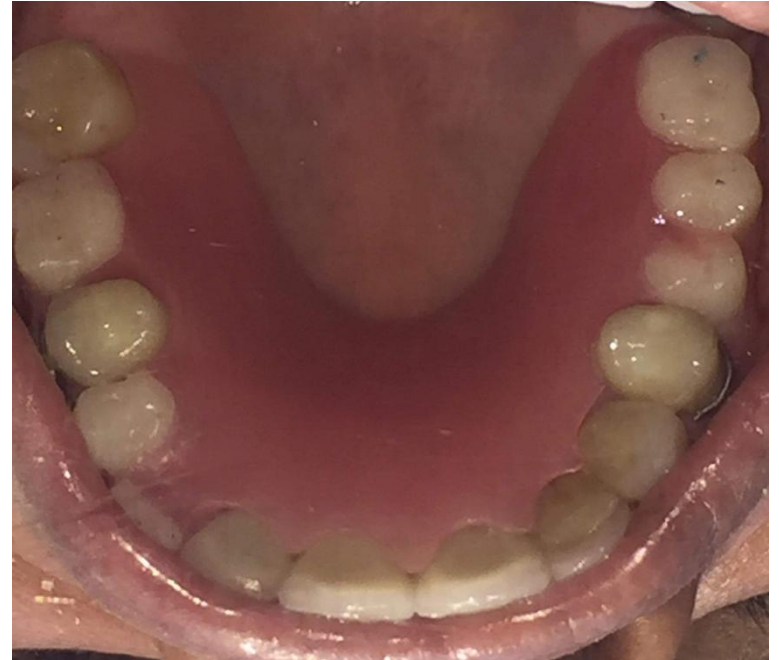
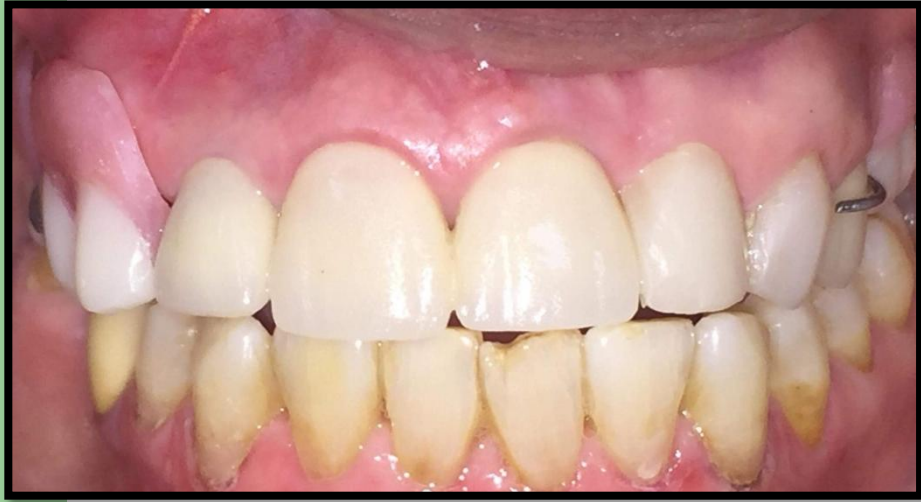
Primary impression



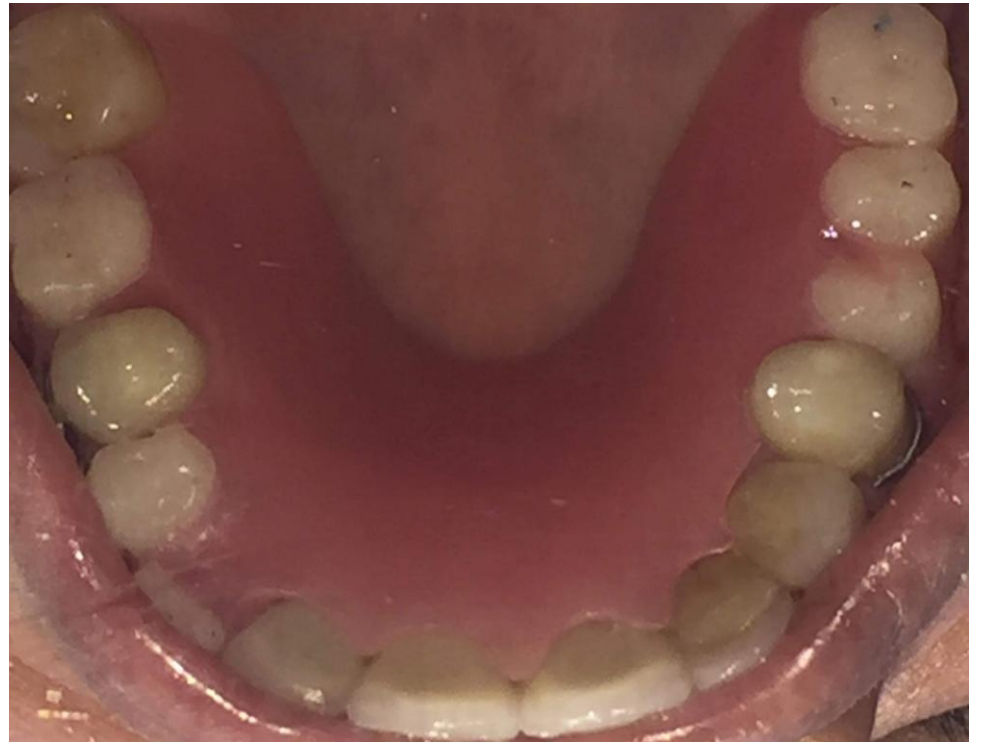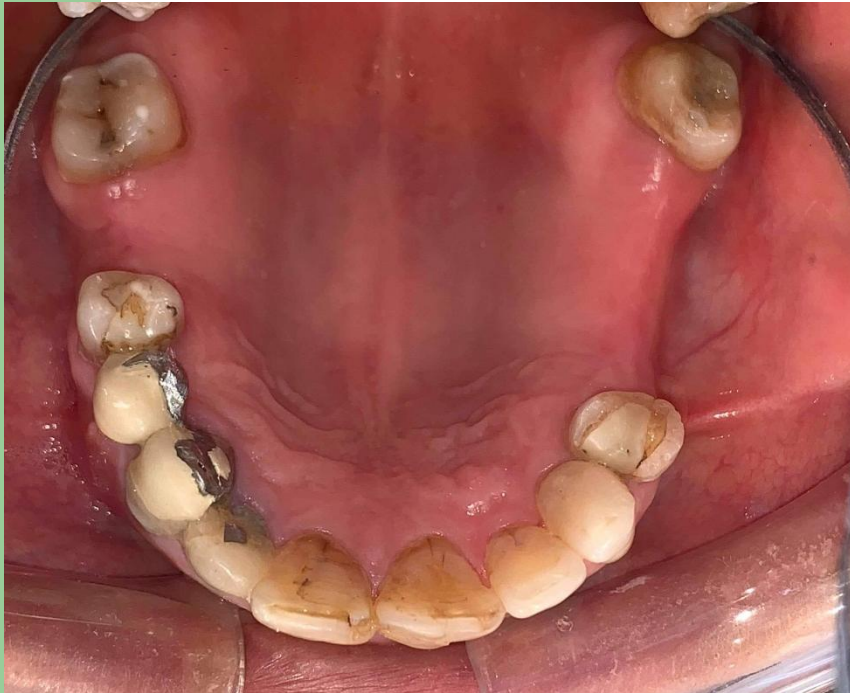Try In





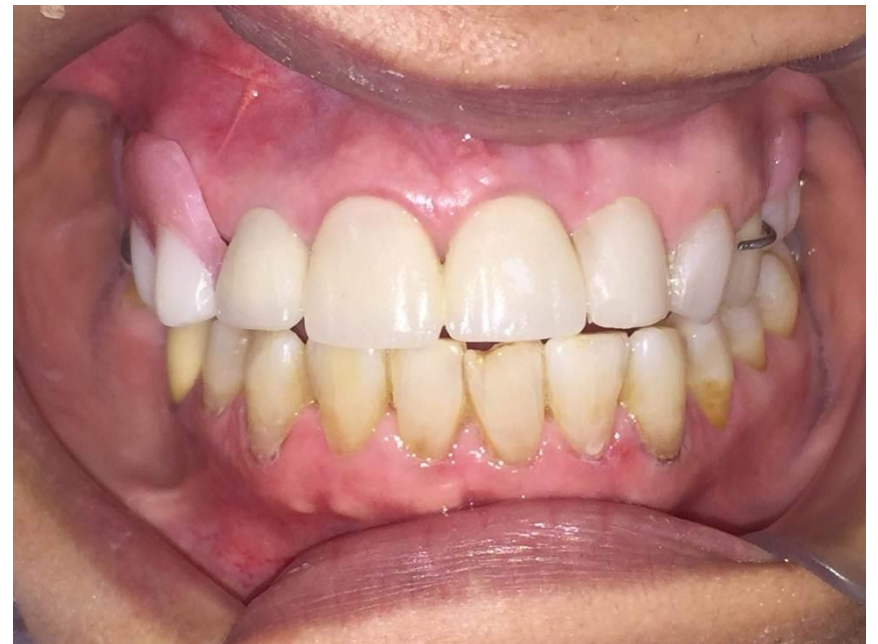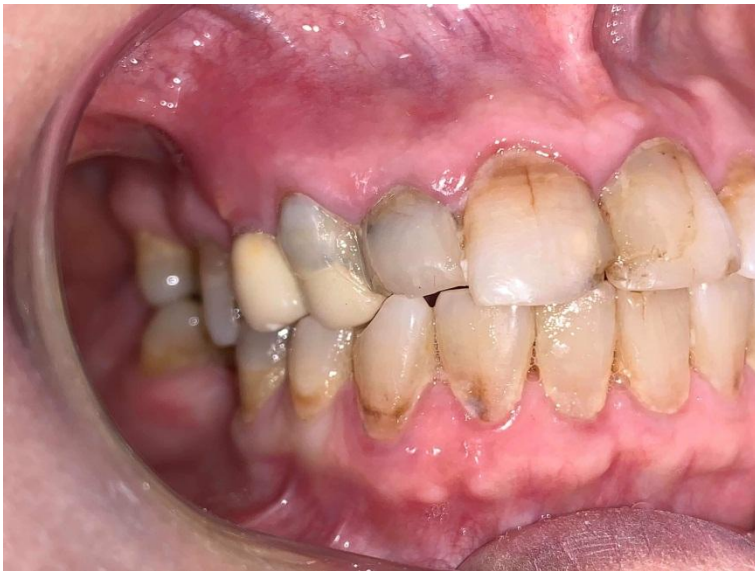Before

After



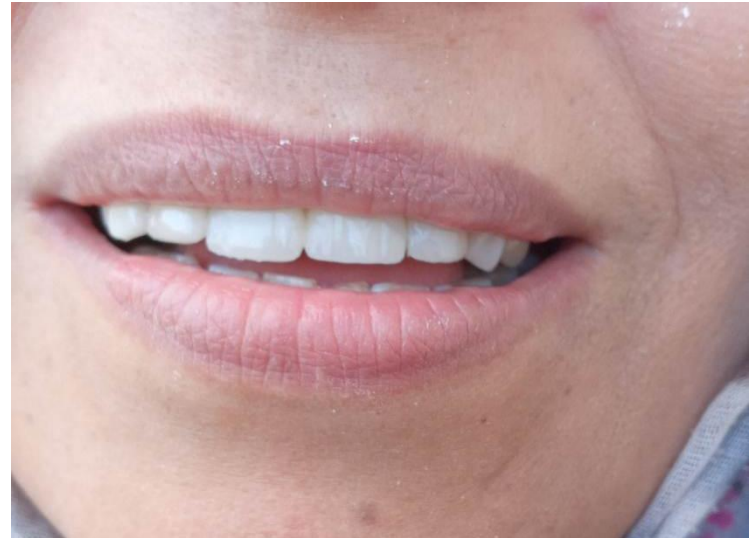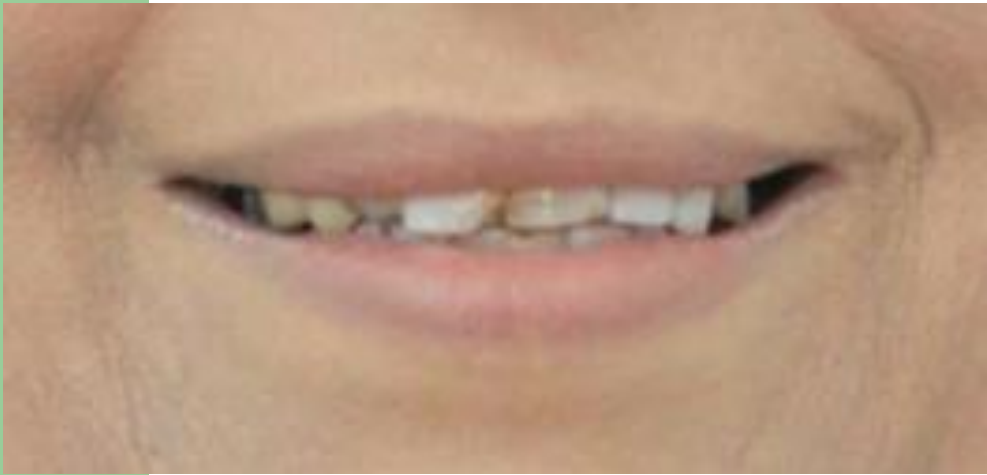Before

After



Before

After





Thank You