



*Libyan International Medical University*



Faculty of Dentistry

# Comprehensive Case Presentation

Presented by :

Alla Abdallah Elswedik

878

# Under Supervision of :

- Dr. Rafik Alkowafi.
- Dr. Abdelmonem Abdelnabi
- Dr. Omar Alhuni.
- Dr. Khadiga Elfallah.
- Dr. Masoud Deihoum.
- Dr. Amal Elawami.
- Dr. Ali Bosnina.
- Dr. Sara Elkilani
- Dr. Hashem Alobidi
- Dr. Nuha Elkadiki.

# Personal Data

Patient's name : A.H.A

Date of birth : 9/10/1994

Gender : Male

Occupation : Engineer student

Address : Al-Gwarsha

Nationality : Libyan

# Chief Complaint

Patient complains of pain in his lower left backward side of the mouth started two months ago.

# History of Chief Complain

Moderate well localized electric shock like pain related to the lower left backward teeth, initiated only by biting on it ,lasts for few minutes, relieved by removal of stimulus, no sleeping disturbance, no associated signs and symptoms, non radiating nature ,no previous treatment attempts.

# Medical History

- ❖ Free of any chronic illness.
- ❖ Systemic review : No abnormality detected.

# Drug History

- ❖ No medications are taken currently.

# Allergic History

- ❖ No allergic history.

# Dental History

- ❖ Symptomatic patient.
- ❖ Last visit : one year ago.
- ❖ No abnormal, destructive habits.
- ❖ History of :
  - ✓ Extraction with no complications
  - ✓ Restorations
  - ✓ RCT

# Family History

- ❖ Diabetes from father's side.

# Social History

- ❖ Single.
- ❖ Student.
- ❖ Patient is smoker since (8 years ) ( 2 packs/ day )
- ❖ No alcohol consumption.
- ❖ No drug abuse.



# General Examinations

- ❖ Asthenic body built.
- ❖ Normal gait, posture, mental status, and speech.

# Clinical Examinations

## ❖ **Extra Oral**

- ✓ Face symmetry : symmetrical.
- ✓ Skin : Normal color, no scars.
- ✓ TMJ : Average mouth opening, No tenderness, clicking, deviation or dislocation detected.
- ✓ Lymph nodes : Not palpable.
- ✓ Lips : competent.
- ✓ Dental relation to facial mid line : coinciding.
- ✓ Face form : Ovoid.
- ✓ Facial profile : Straight.

# Clinical Examinations.

## ❖ **Intra Oral**

- ✓ Severe halitosis.
- ✓ Oral mucosa : gingiva is pigmented , Leukodema on the buccal mucosa bilaterally .
- ✓ Tongue and palate : Hairy tongue, no abnormality detected in relation to palate.

# Clinical Examinations Co.

## ❖ Oral hygiene index :

Patient has poor oral hygiene.

### ✓ Plaque

16	11	26
3	2	3
3	1	3
46	31	36

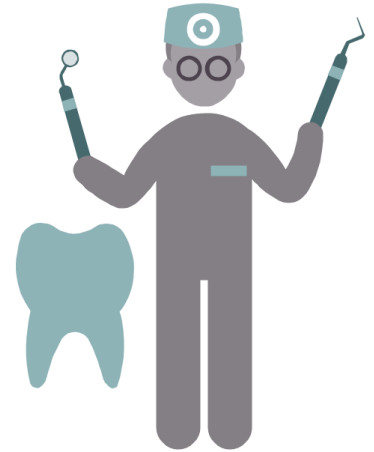$$P.I = 15/6 = 2.5.$$

### ✓ Calculus

16	11	26
2	0	2
2	2	2
46	31	36

$$C.I = 10/6 = 1.6.$$

$$OHI-S = 2.5 + 1.6 = 4.1$$



# Gingival status

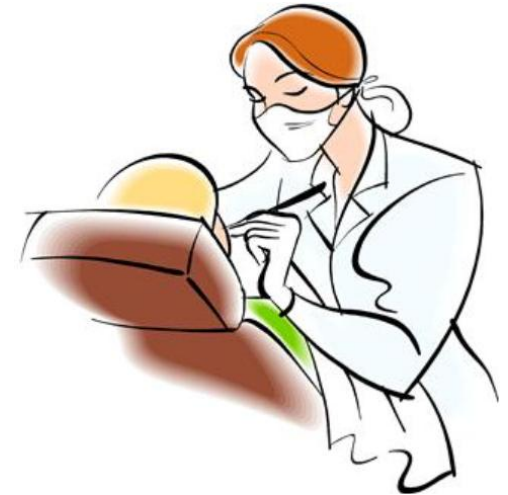**Frenal attachment** : Normal.

**Fermitus test** : -ve.

**attached gingiva** : Adequate.

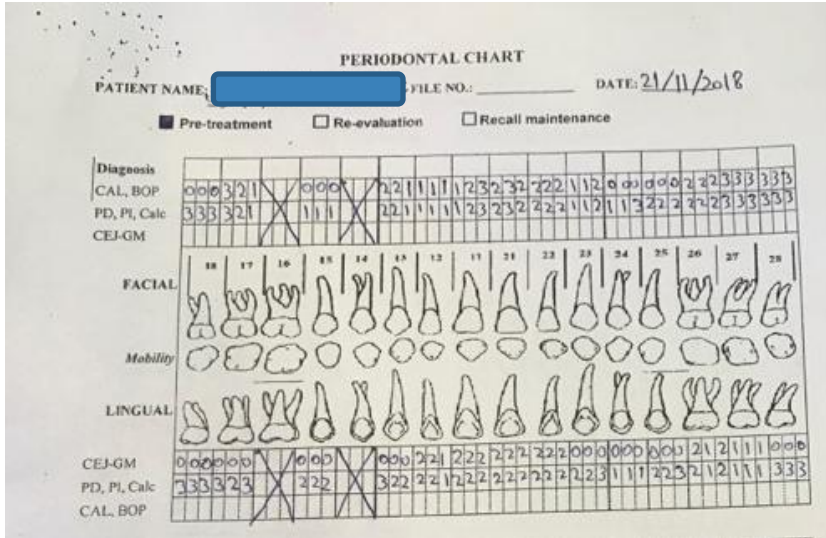
	Mand. Rt Posteriors	Mand. Anteriors	Mand. Lt Posteriors
Colour	Bluish red	Bluish red	Bluish red
Contour	Rolled margins with blunt IDP	Rolled margins with blunt IDP	Rolled margins with blunt IDP
Size	No enlargement	Slight enlargement	No enlargement
Consistency	Soft and edematous	Soft and edematous	Soft and edematous
Stippling	Absent	Absent	Absent
Position	At CEJ	At CEJ	At CEJ
Bleeding on probing	Present	Present	Present
Exudation	Absent	Absent	Absent

	Max. Rt Posteriors	Max. Anteriors	Max. Lt Posteriors
Colour	Bluish red	Bluish red	Bluish red
Contour	Rolled margins with blunt IDP	Rolled margins with blunt IDP	Rolled margins with blunt IDP
Size	No enlargement	Slight enlargement	No enlargement
Consistency	Soft and edematous	Soft and edematous	Soft and edematous
Stippling	Absent	Absent	Absent
Position	At CEJ	At CEJ	At CEJ
Bleeding on probing	Present	Present	Present
Exudation	Absent	Absent	Absent

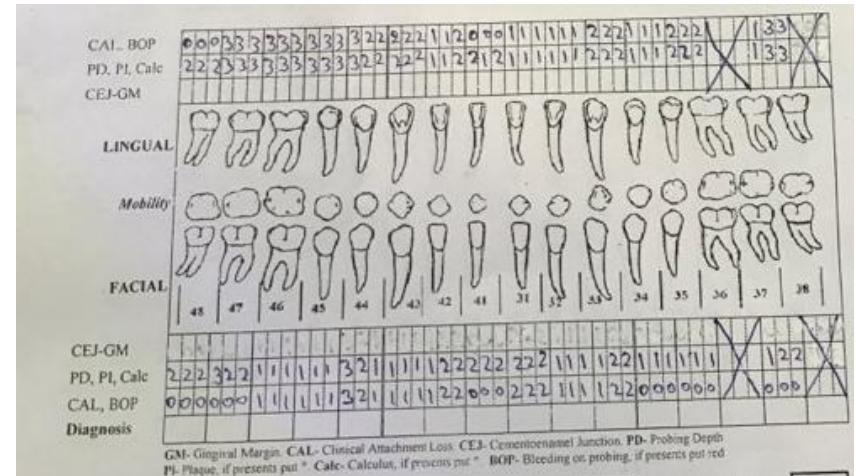


# Periodontal status

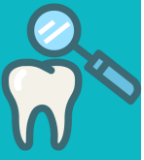- **Diagnosis :**
  - ✓ Generalized mild chronic periodontitis.
- **Overall prognosis :**
  - ✓ Good.



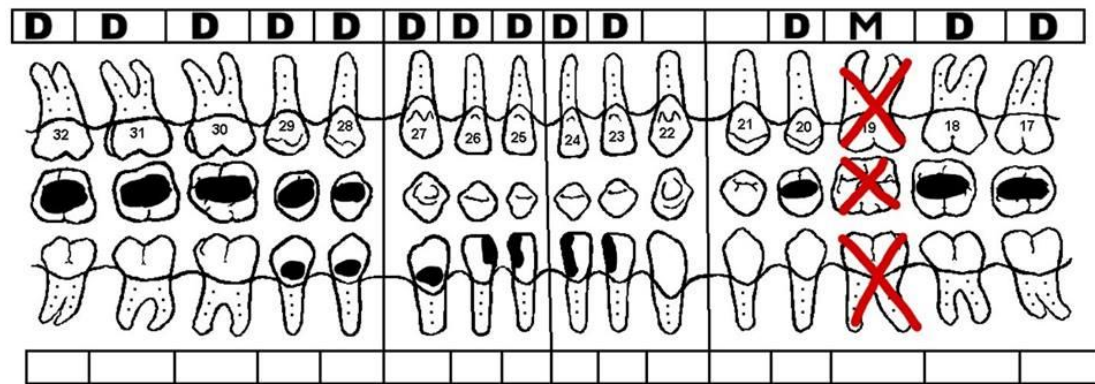
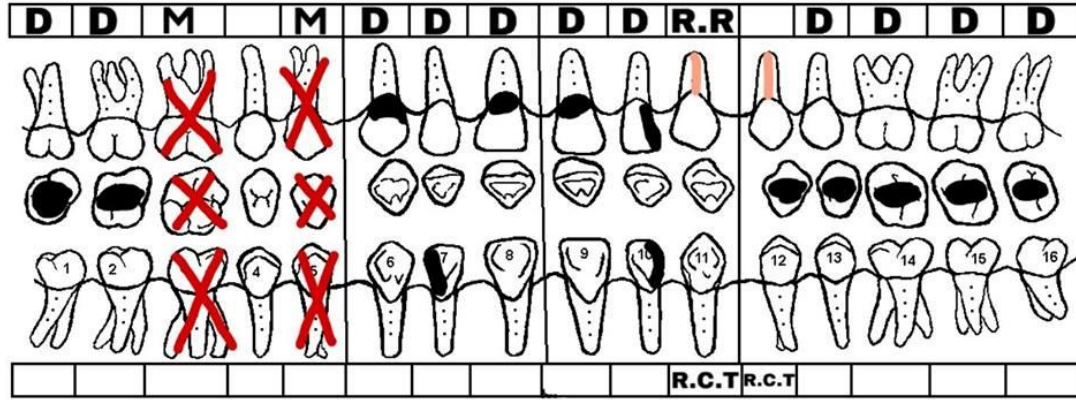
Upper arch



Lower arch



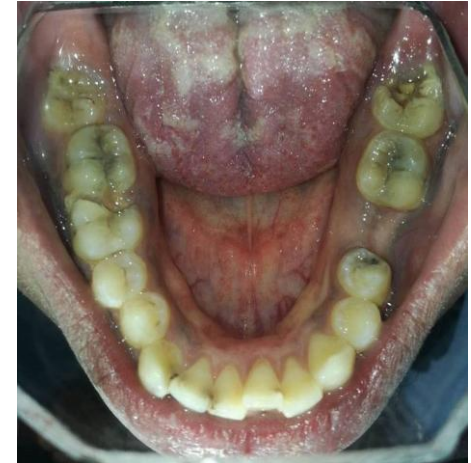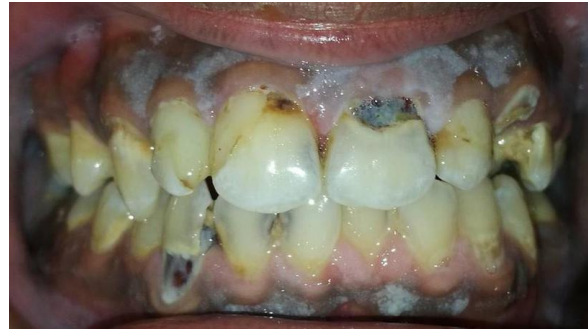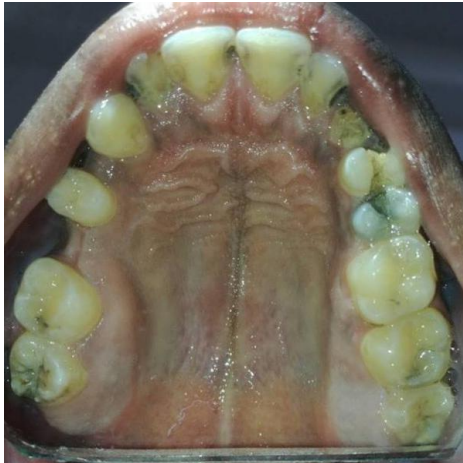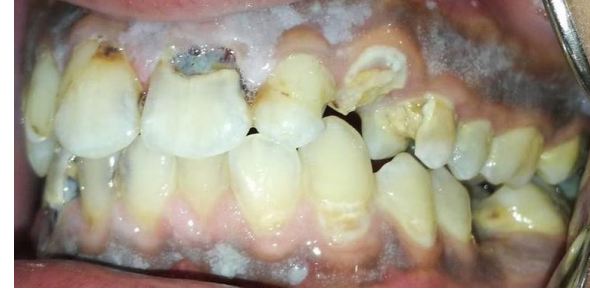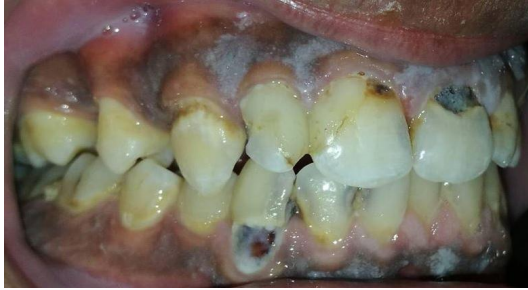# Hard Tissue Examinations



**Tenderness to palpation ( 23 )**

**Tenderness to percussion ( 38 - 25 - 24 - 23 - 46 )**

# Pre-operative Photographs





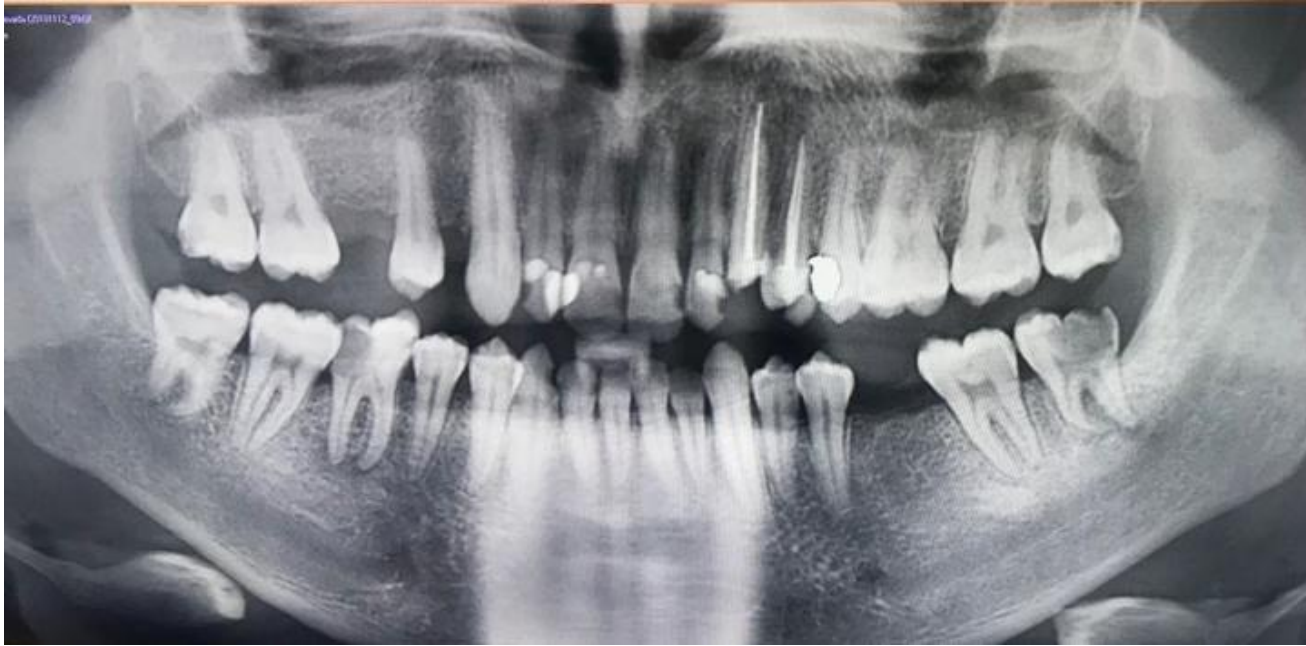# Differential Diagnosis

- ✓ Chronic periapical periodontitis.
- ✓ Chronic periapical abscess.
- ✓ Periapical granuloma.

# Investigations

- ✓ IOPA
- ✓ Bitewing
- ✓ Orthopantomogram ( OPG )

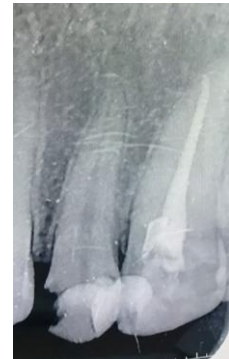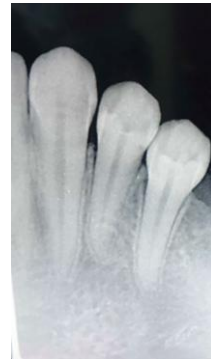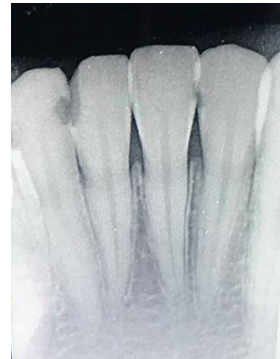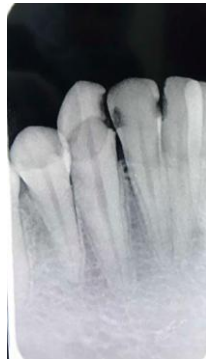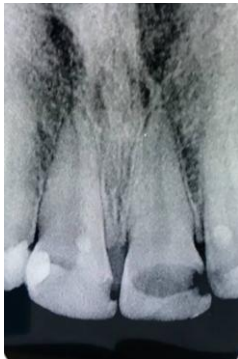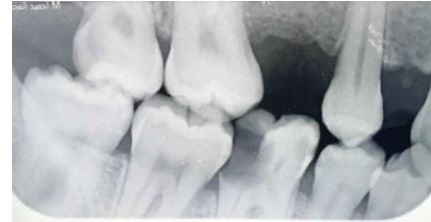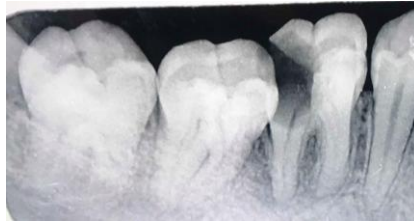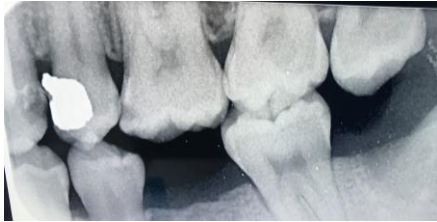# Orthopantomogram



- Orthopantomogram showing upper and lower jaws .
- Mild bone loss.
- Teeth present ( 18-17-15-13-12-11-21-22-23-24-25-26-27-28-38-37-35-34-33-32-31-41-42-43-44-45-46-47-48 )
- Missing teeth ( 16-14-36 )
- Filled teeth ( 12-23-24 )

❖ IOPA

❖ Bitewing



# Final Diagnosis

- ✓ Chronic periapical periodontitis. ( 38 )
- ✓ Generalized mild chronic periodontitis.
- ✓ Dental caries  
( 18-17-13-12-11-21-22-23-24-25-26-27-28-38-37-35-31-32-41-42-43-44-45-46-47-48 )



# Treatment Plan

- ❖ Emergency Phase
  - ✓ Extraction ( 38 )
  
- ❖ Phase I Therapy
  - ✓ Patient motivation and education toward the importance of plaque control.
  - ✓ Diet control.
  - ✓ Supra and subgingival scalling
  
- ❖ Re-evaluation of Phase I Therapy



# Treatment Plan

- ❖ Phase II Therapy
- ✓ Extraction ( 18-28-48-46 )
- ✓ Gingivoplasty.
- ✓ Gingival depigmentation ( anterior upper and lower )
- ✓ Crown lengthening ( 23-24 )
- ✓ Site preparation. ( 46 )
- ✓ Apicectomy. ( 24 )



# Treatment Plan

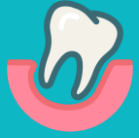- ❖ Phase III Therapy/ Restorative Phase
  - ✓ RCT ( 12-11-21-22-25 )
  - ✓ Retreatment ( 23-24 )
  - ✓ Composite restoration  
( 37-42-43-44-45-41-42-31-32-35-47-27-26 )
  - ✓ Post, core and crown  
( 12-11-21-22-23-24-25 )
  - ✓ Replacement of missing teeth “Bridge” ( 16-46-36 )





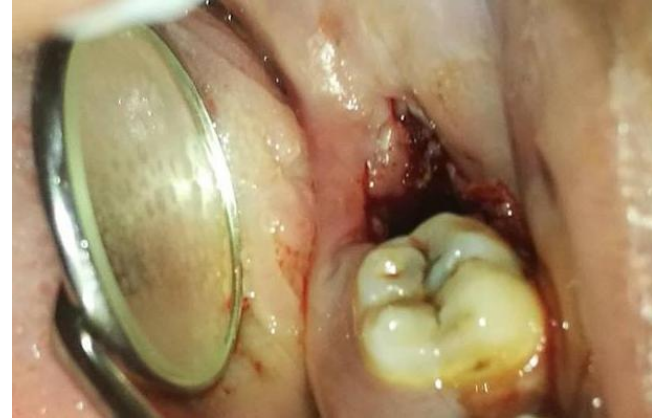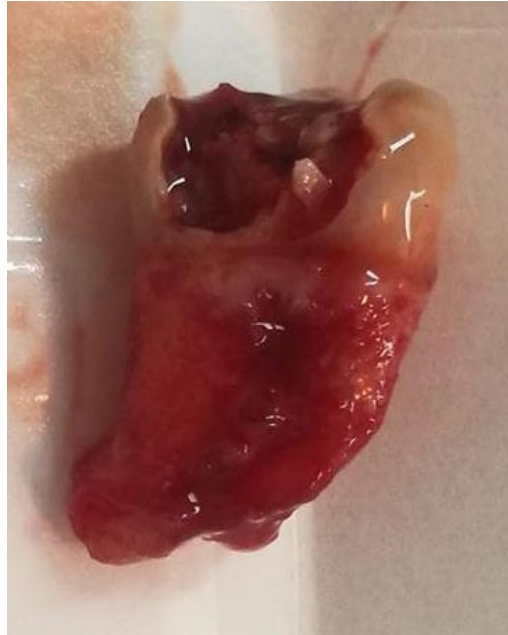
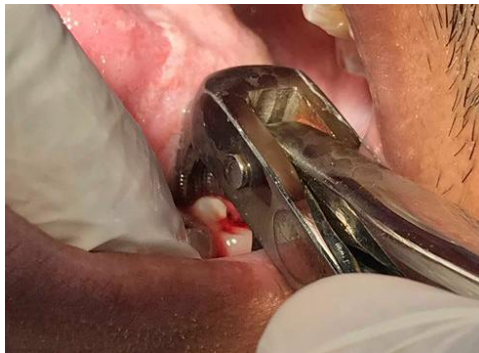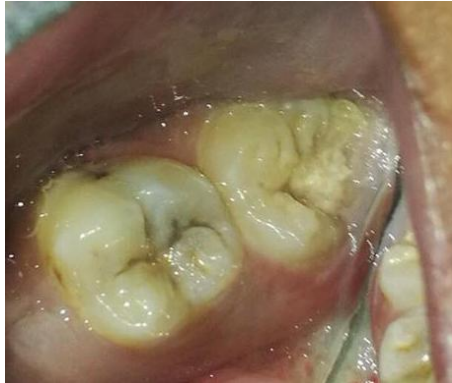# Treatment Plan

- ❖ Phase IV Therapy/ Maintenance & Recall
- ✓ Periodic checking 1<sup>st</sup> after 3 months, then after every 6 months if maintenance achieved.



# Extraction of ( 38 )

## Chief Complain



# Diet Sheet Analysis



نوع الوجبة	المأكولات و المشروبات	الساعة	اليوم
فطور	قهوة	7:30	الخميس
	مياه	8:25	
	سندوتش تن + دحي + مشروب غازي	9:30	
غداء	أرز + دجاج + عصير طبيعي	2:15	
	قهوة	5:00	
	قهوة + مياه	8:10	
عشاء	سندوتش برجر + مشروب غازي	9:20	
	مياه	10:15	
	سندوتش شيش + بطاطا + مشروب غازي	11:45	

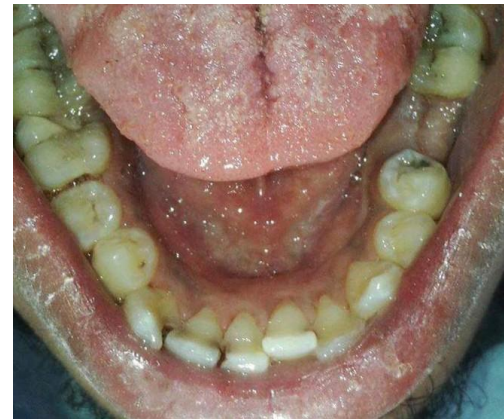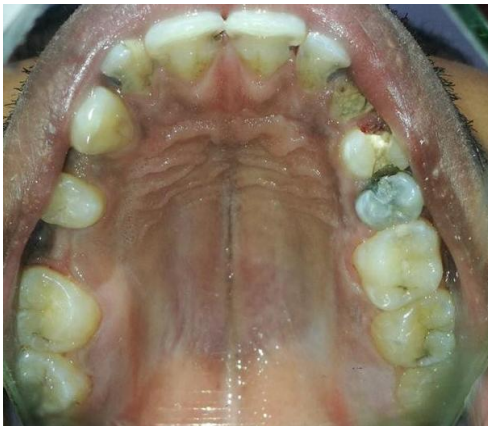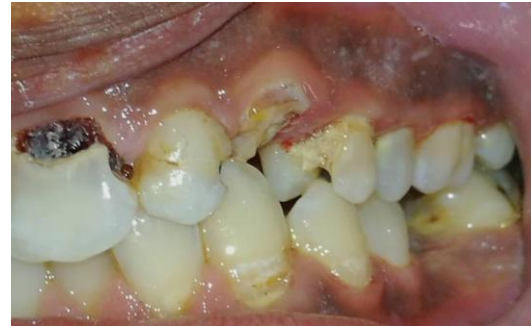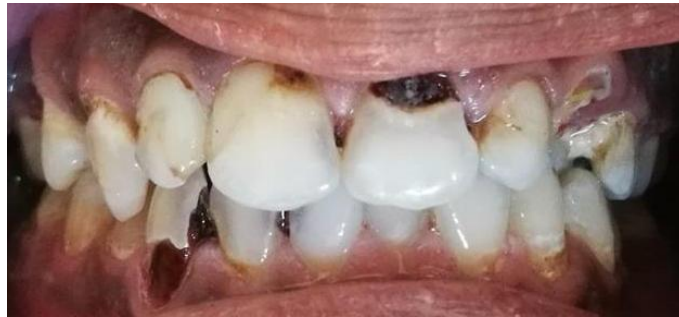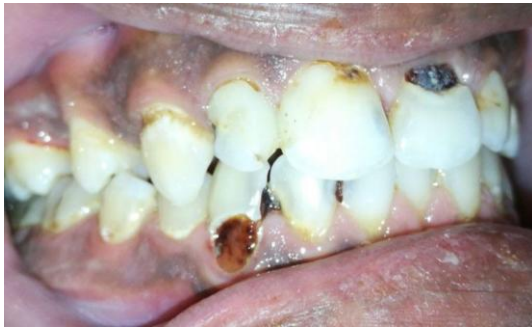نوع الوجبة	المأكولات و المشروبات	الساعة	اليوم
فطور	قهوة + مياه	10:00	الجمعة
غداء	كسكسي + عصير ليمون طبيعي	2:00	
	قهوة	4:45	
عشاء	قهوة	7:30	
	مياه	8:00	
	طبق بيتزا + مشروب غازي + بطاطا	9:40	
	قهوة	10:30	
	سندوتش برجر + مشروب غازي + مياه	11:30	

✓ The diet sheet was discussed with the patient, supporting their good habits & explaining the effect of the bad ones on their oral health and how to decrease and stop that effect.



نوع الوجبة	المأكولات و المشروبات	الساعة	اليوم
فطور	قهوة	9:00	السبت
غداء	برجر + مشروب غازي	1:00	
	عصير طبيعي	3:15	
عشاء	قهوة	5:00	
	مشروب غازي	6:30	
	مياه	8:30	
	طبق بيتزا + مشروب غازي + بطاطا	9:00	
	قهوة	11:00	
	عصير طبيعي	12:30	
	مياه	1:00	

# Scaling

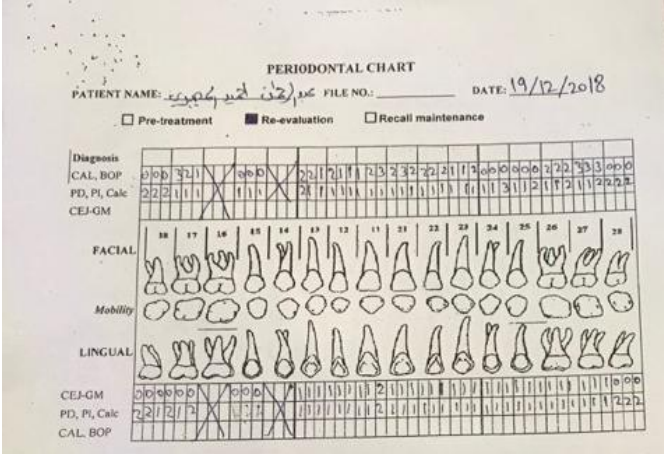




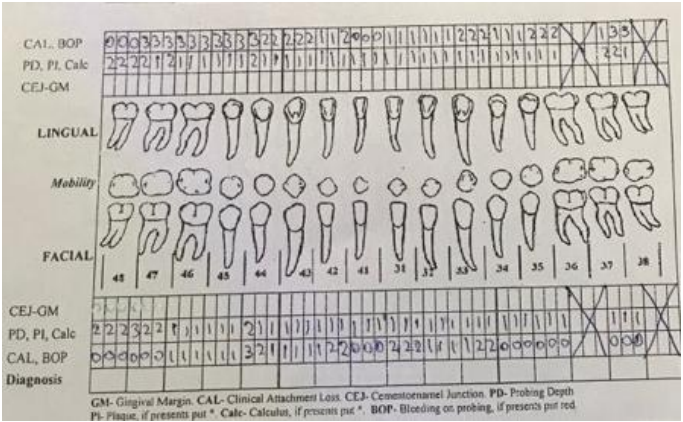
# Re-evaluation of Phase I Therapy

- ✓ Patient showed significant improvement of oral hygiene.
- ✓ Improved gingival status.
- ✓ Less bleeding upon probing.
- ✓ Generalized probing depth reduction.

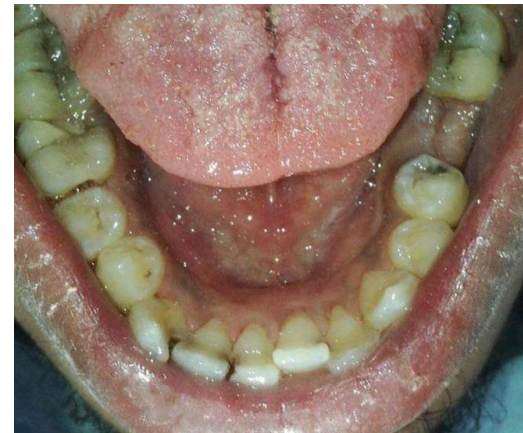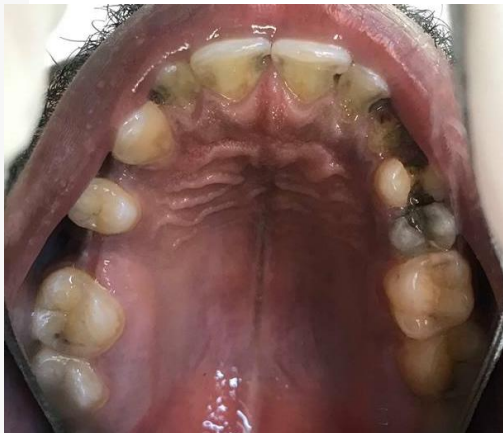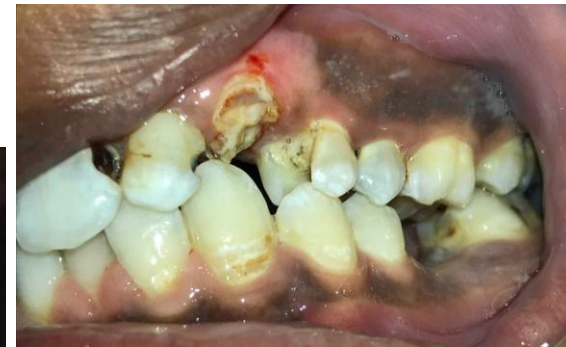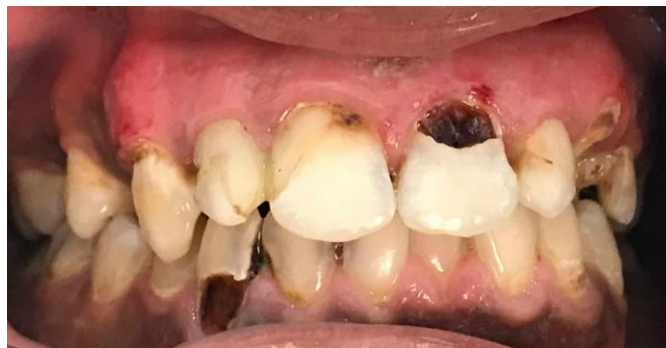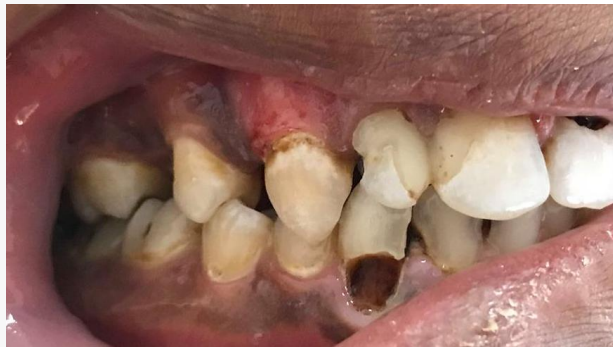Upper arch



Lower arch



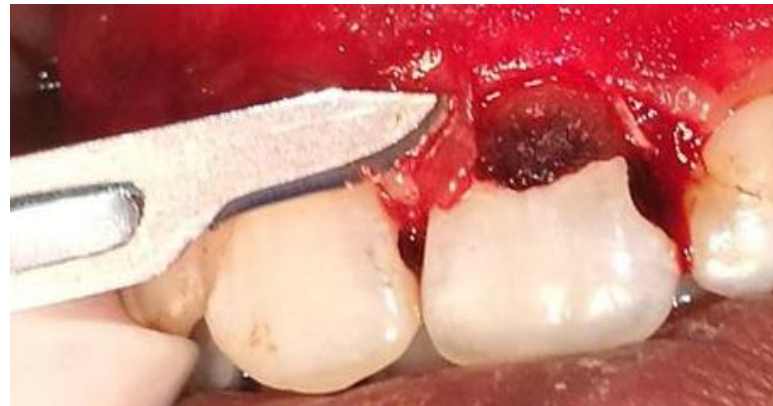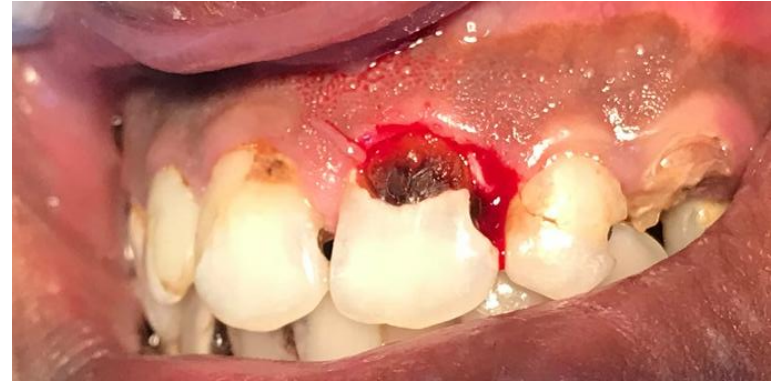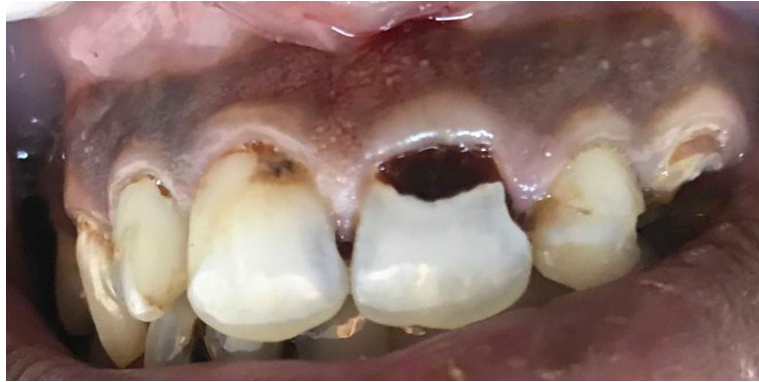# Re-evaluation of Phase I Therapy Co.



# Surgical Phase

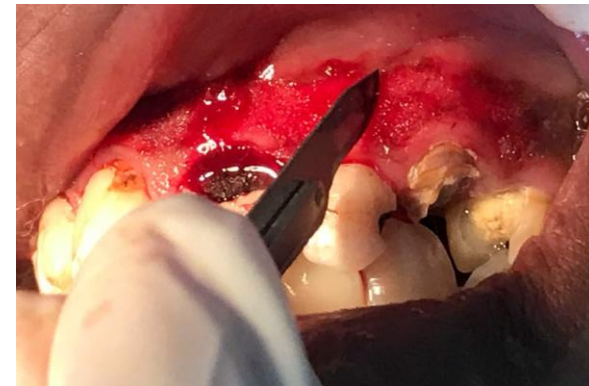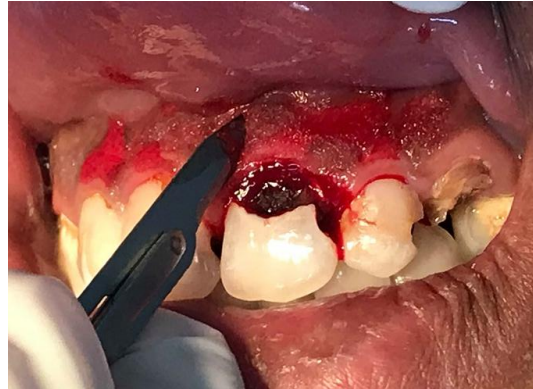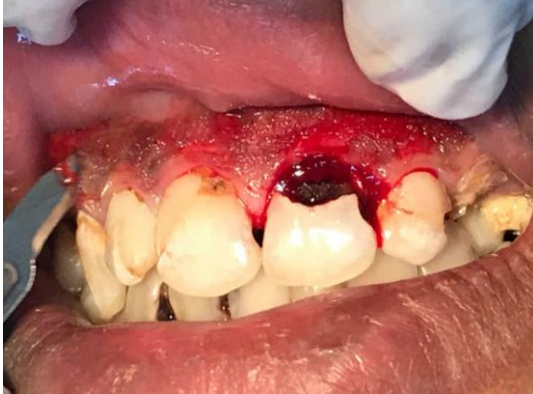- ✓ Extraction ( 18-28-48-46 )
- ✓ Gingivoplasty.
- ✓ Gingival depigmentation ( anterior upper and lower )
- ✓ Crown lengthening ( 23-24 )
- ✓ Site preparation. ( 46 )

# Gingivoplasty & Gingival Depigmentation



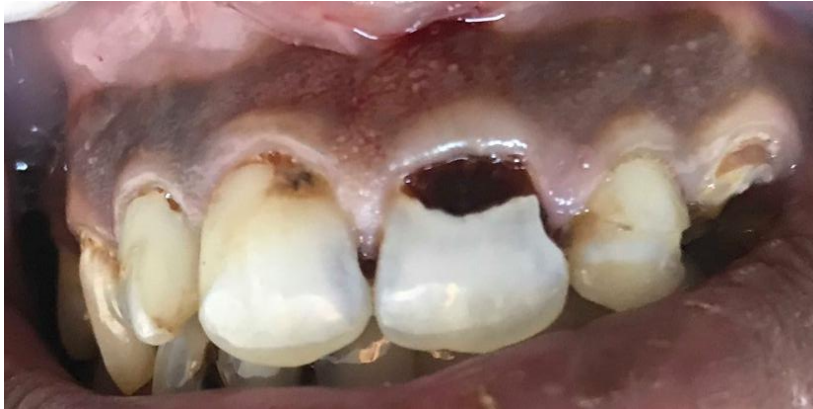

# Gingivoplasty & Gingival Depigmentation.

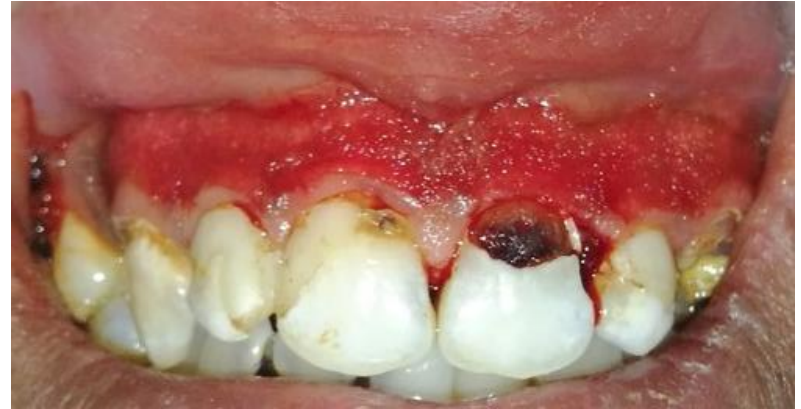

# Gingivoplasty & Gingival Depigmentation.

Before

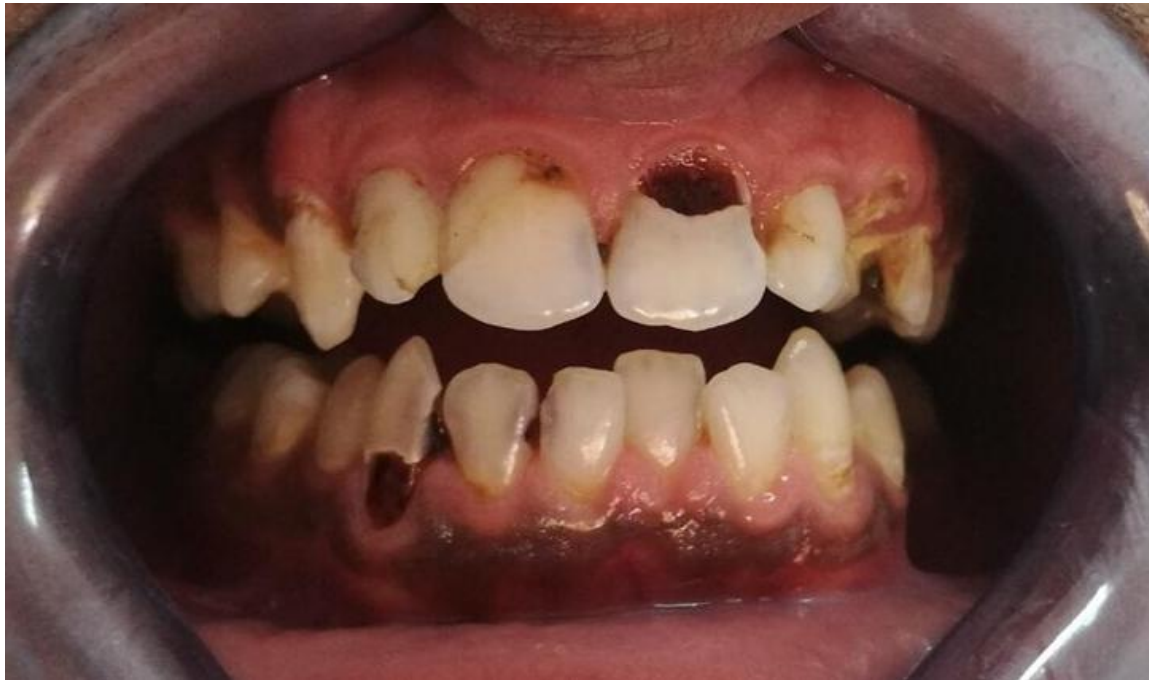

After

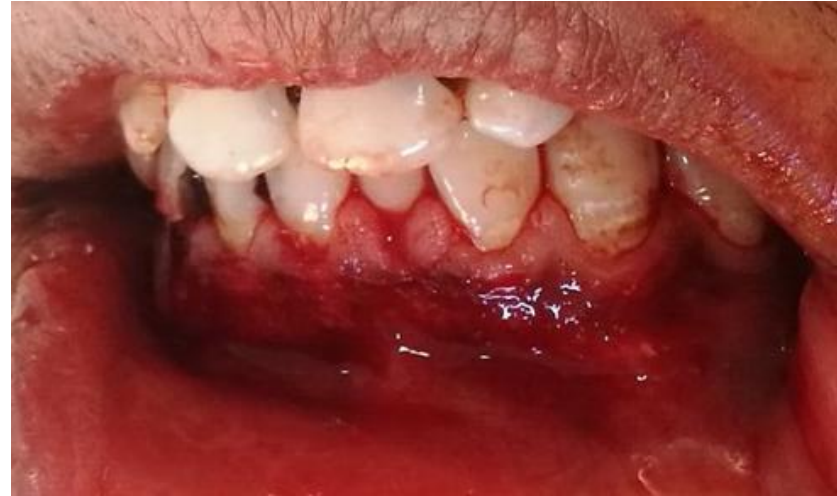
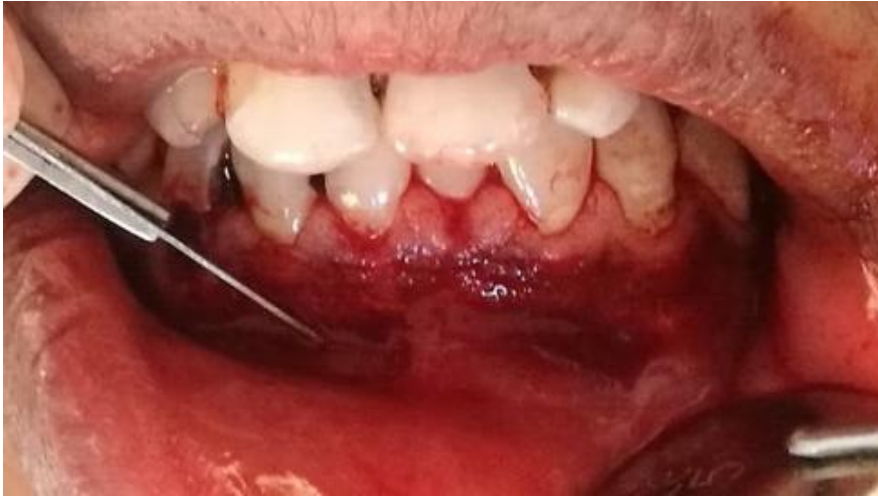
# Gingivoplasty & Gingival Depigmentation.

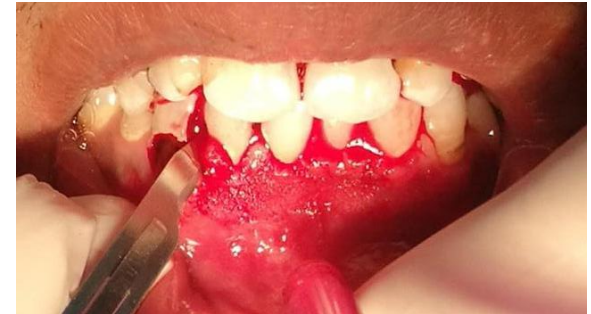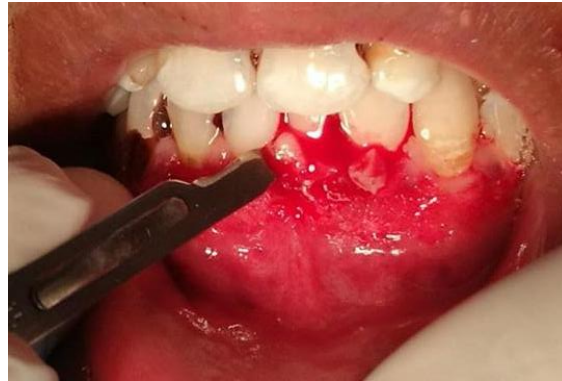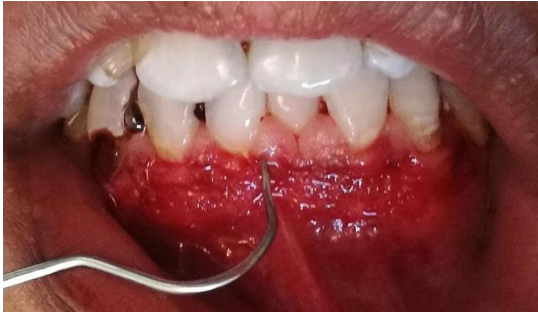Follow up after one week



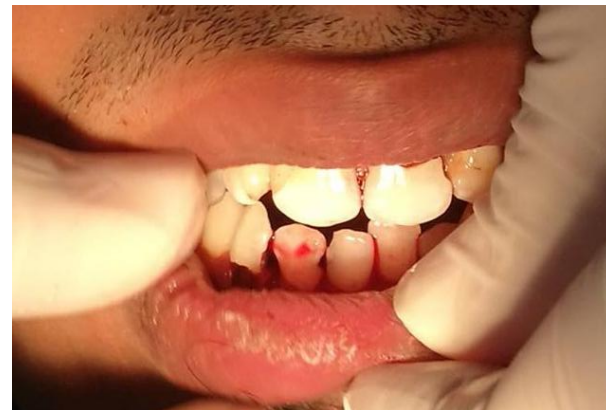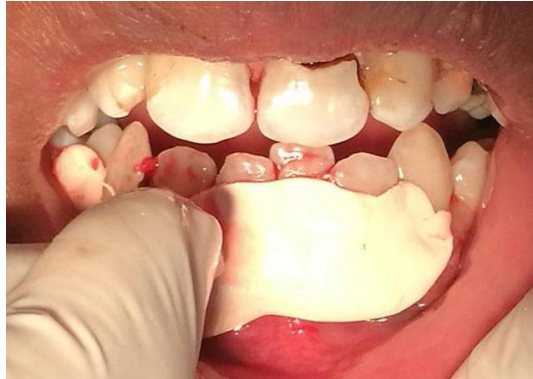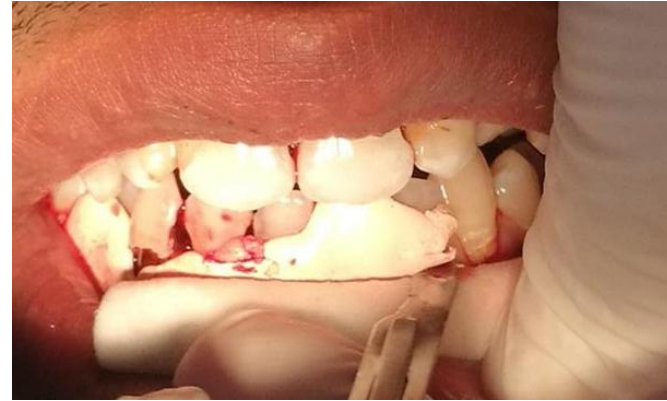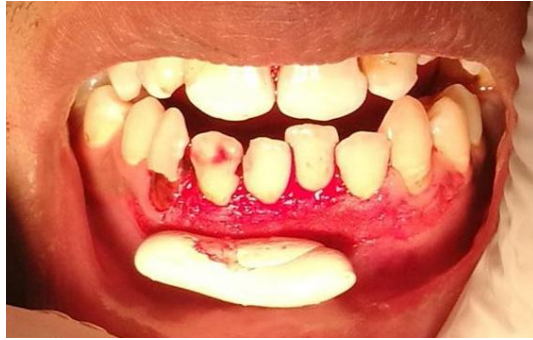# Gingivoplasty & Gingival Depigmentation.



# Gingivoplasty & Gingival Depigmentation.

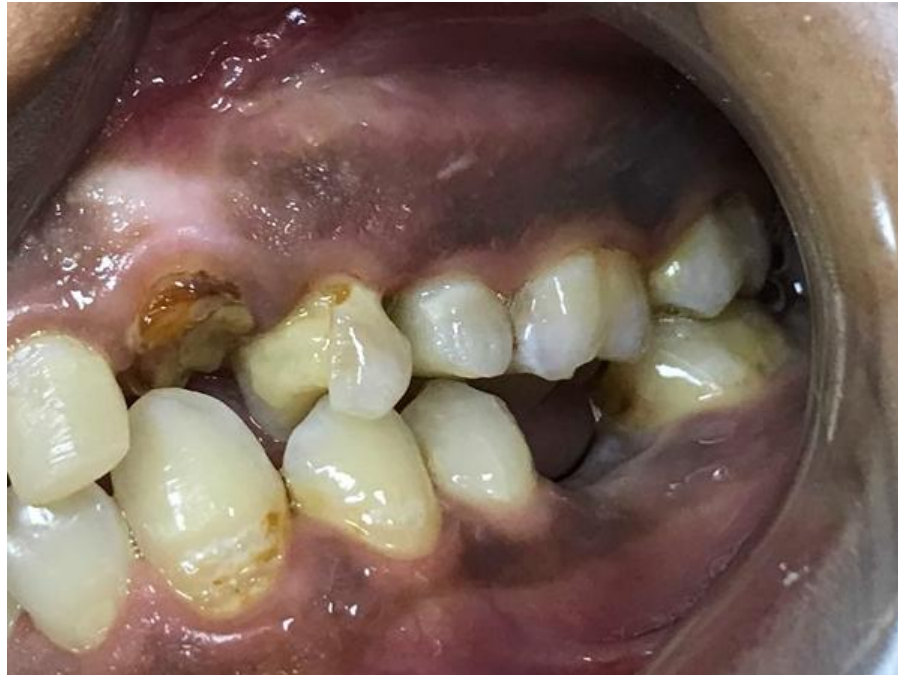

# Gingivoplasty & Gingival Depigmentation.

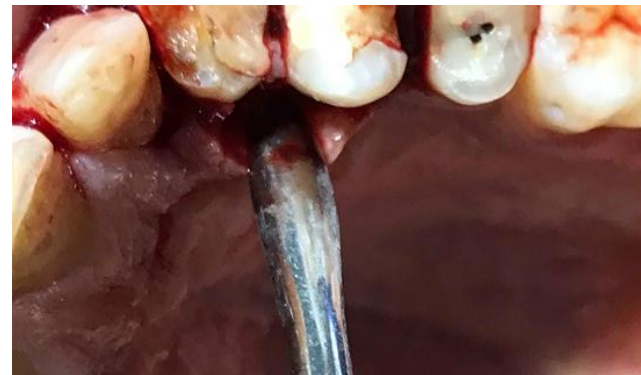
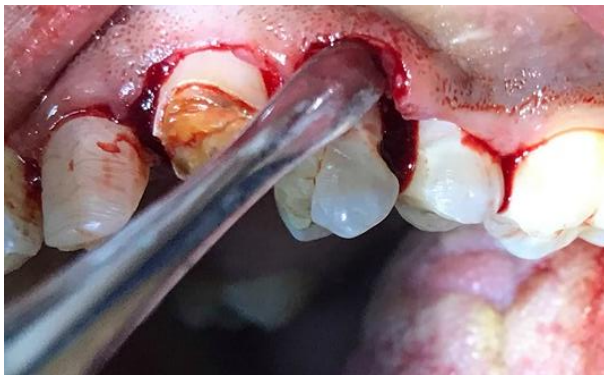
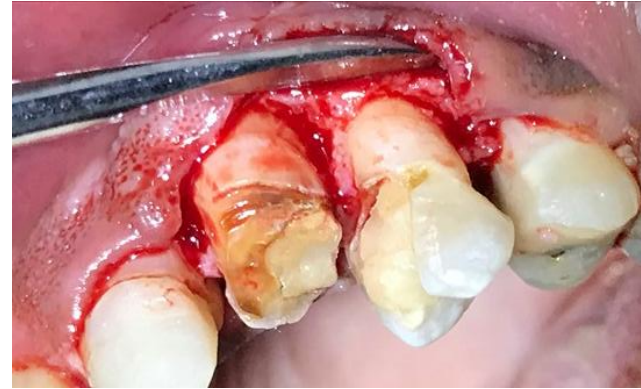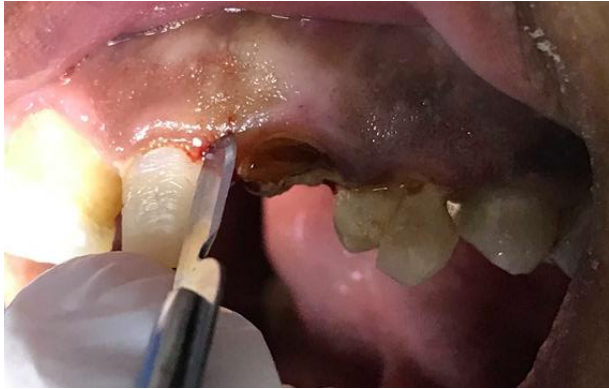# Crown Lengthening [ 23 ] [ 24 ]

## Pre-Operative Photograph

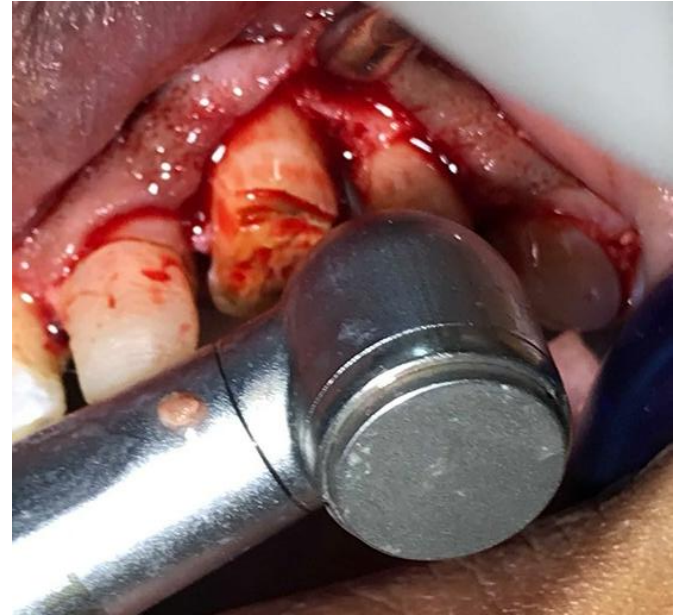
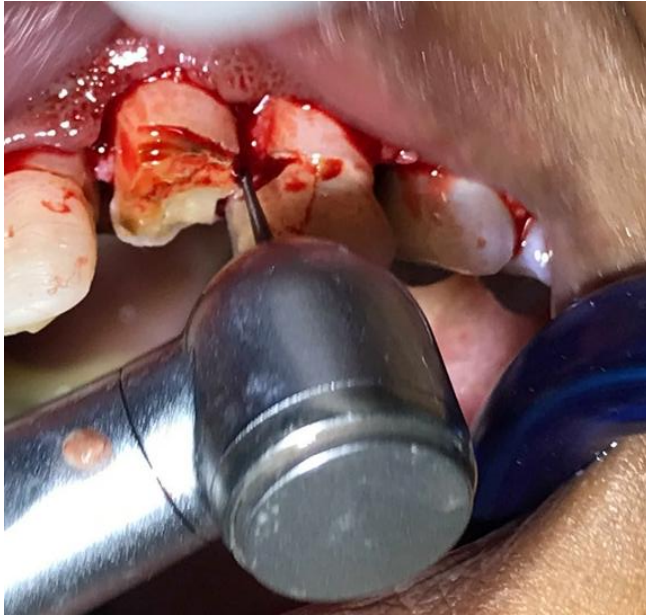
# Crown Lengthening ( 23 ) ( 24 )

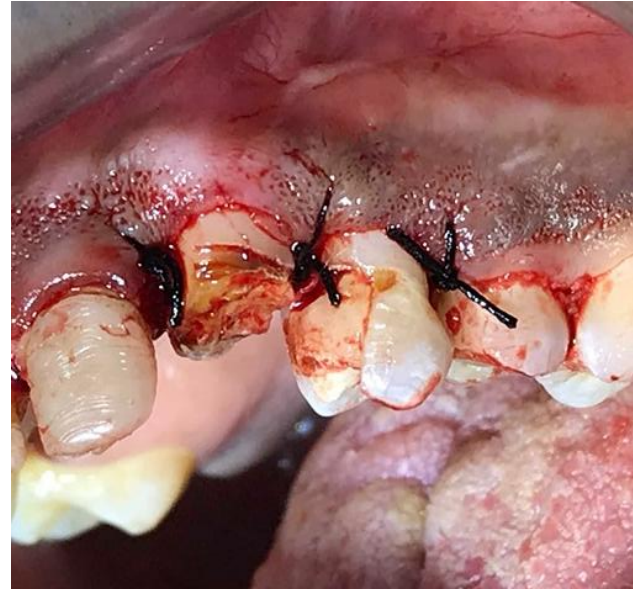
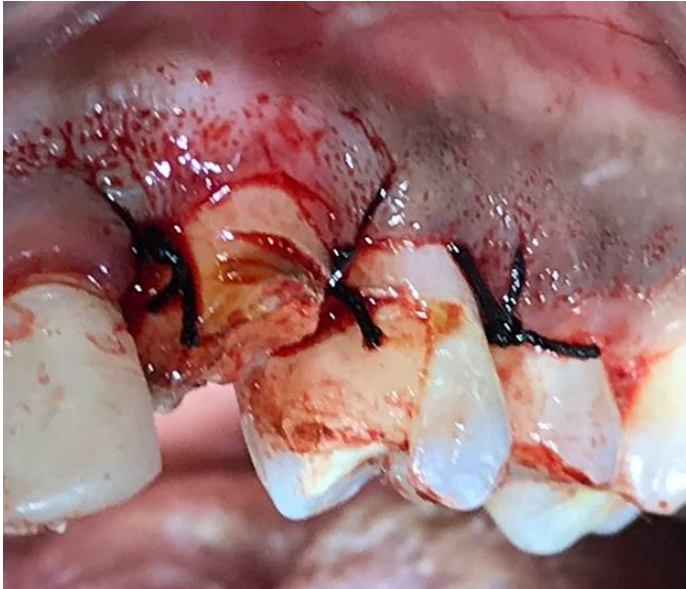


# Crown Lengthening ( 23 ) ( 24 )

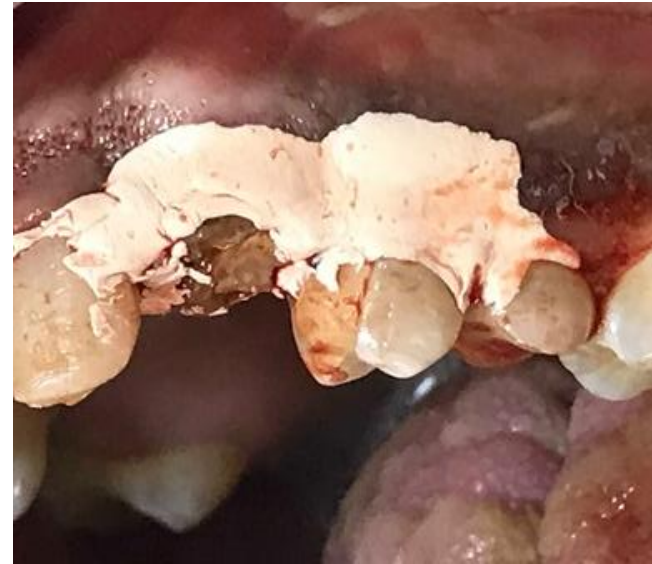
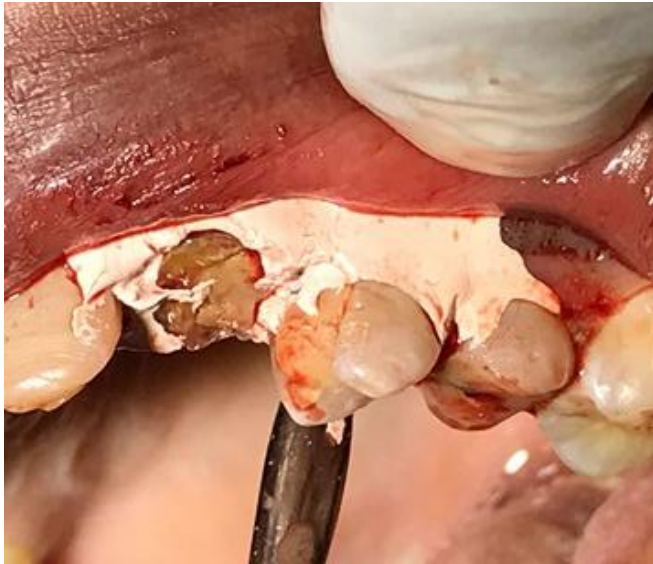
# Crown Lengthening ( 23 ) ( 24 )



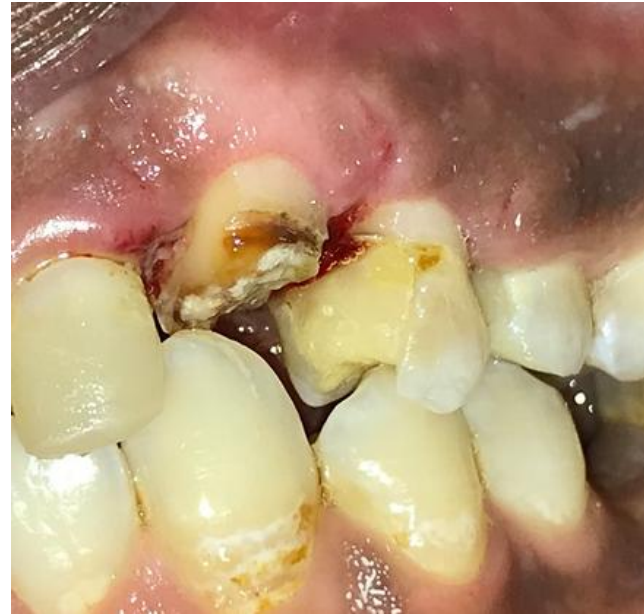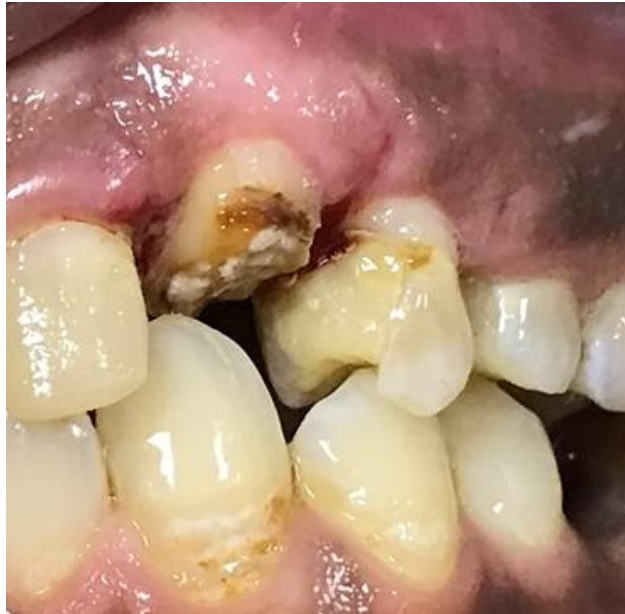# Crown Lengthening ( 23 ) ( 24 )

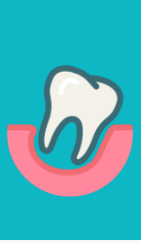## PerioPack



# Crown Lengthening ( 23 ) ( 24 )

## Post-Operative Photograph

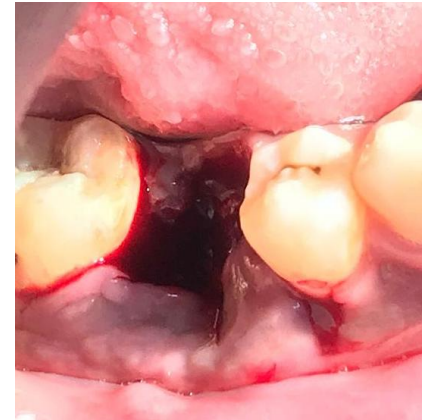
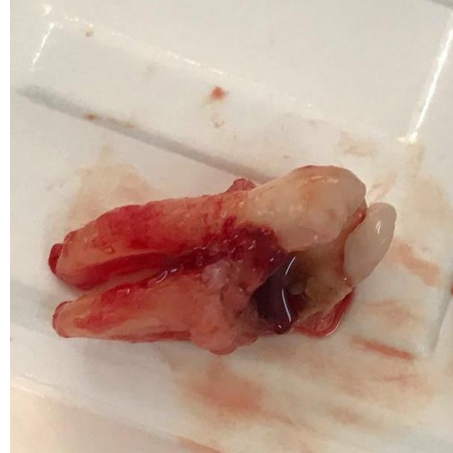
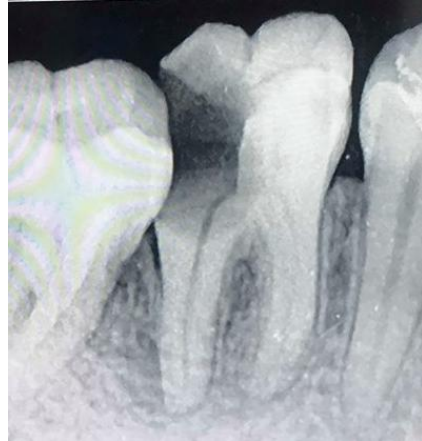
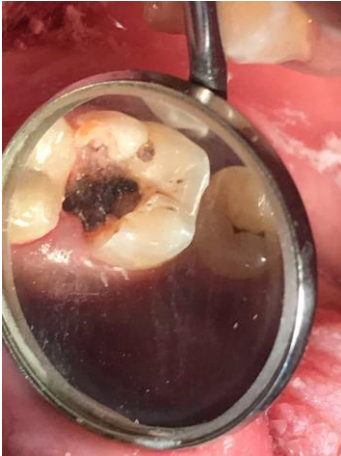
# Extraction of Non-restorable Teeth

( 18 / 28 / 46 / 48 )

- ✓ Intentions to treat the tooth endodontically was failed due to extensive carious lesion that was not clearly seen in a 2D x-ray.

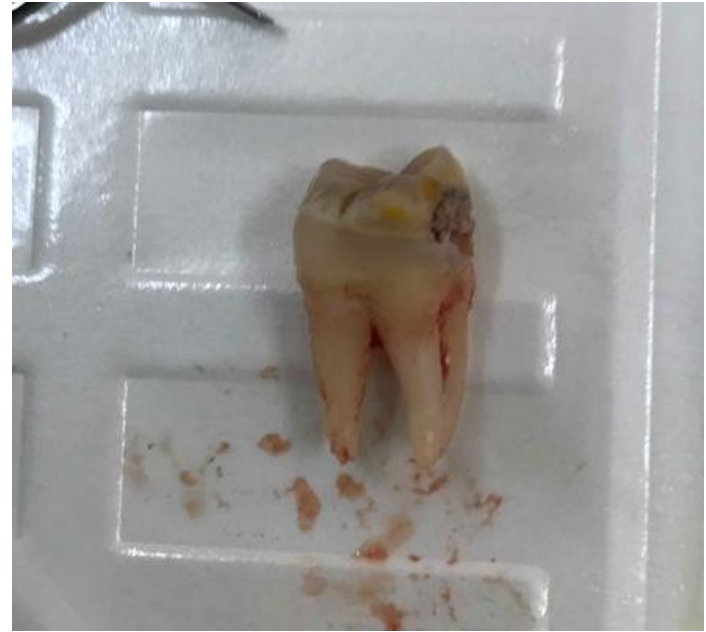
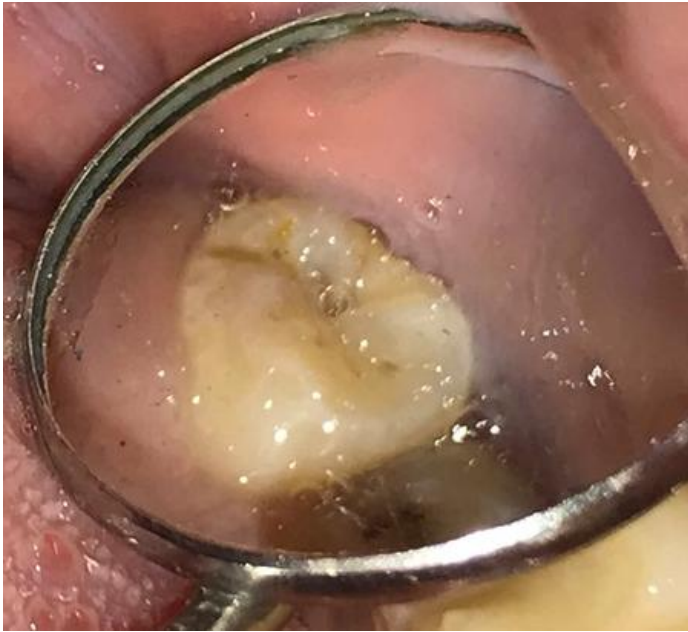


- Phase II Therapy  
Surgical Phase

# Extraction of Non-restorable Teeth

( 18 / 28 / 46 / 48 )

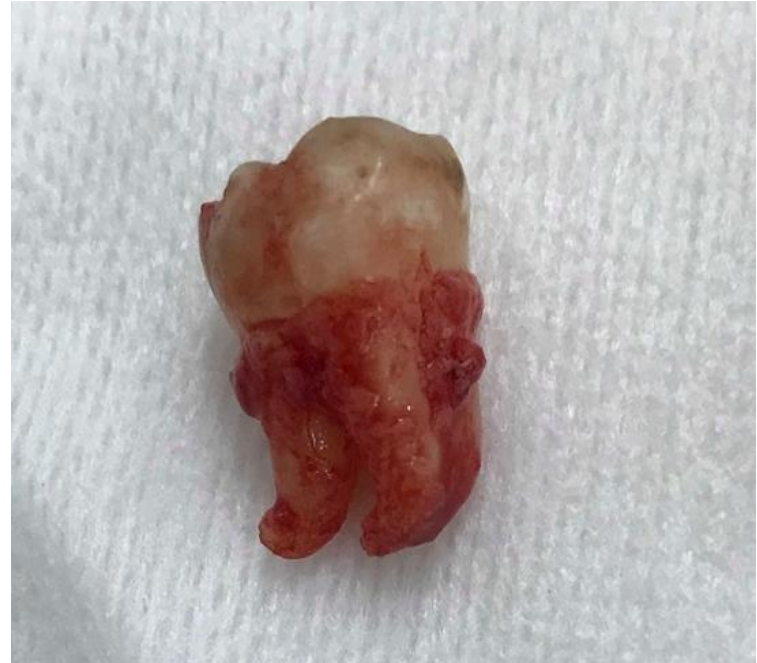
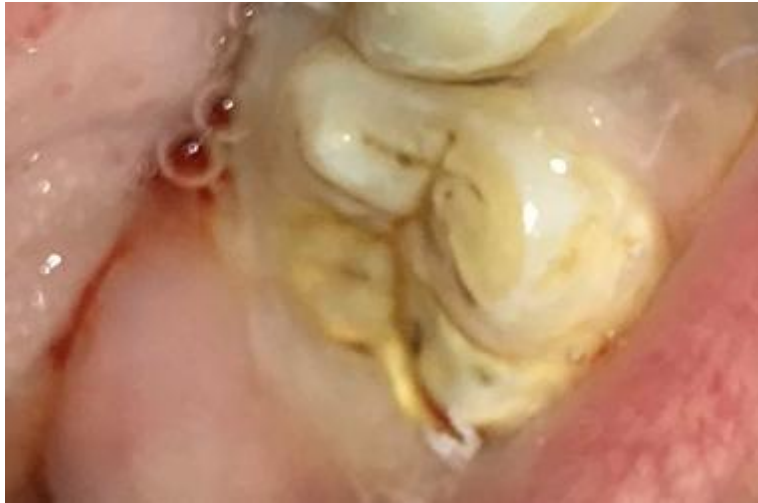


- Phase II Therapy  
Surgical Phase

# Extraction of Non-restorable Teeth

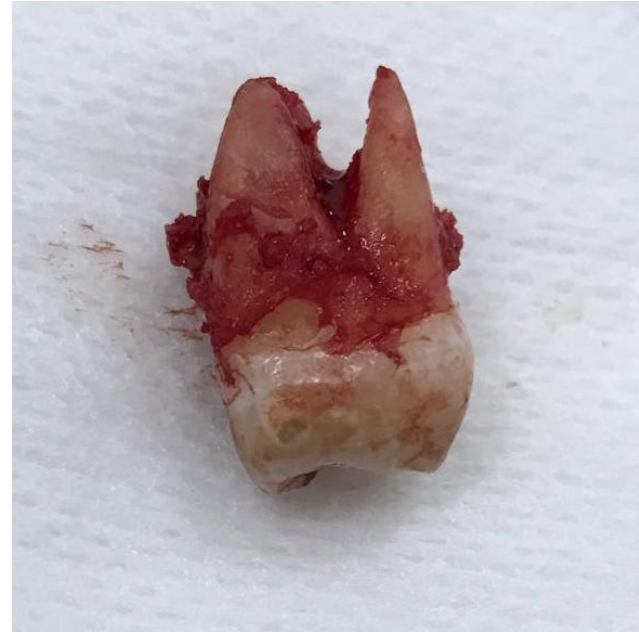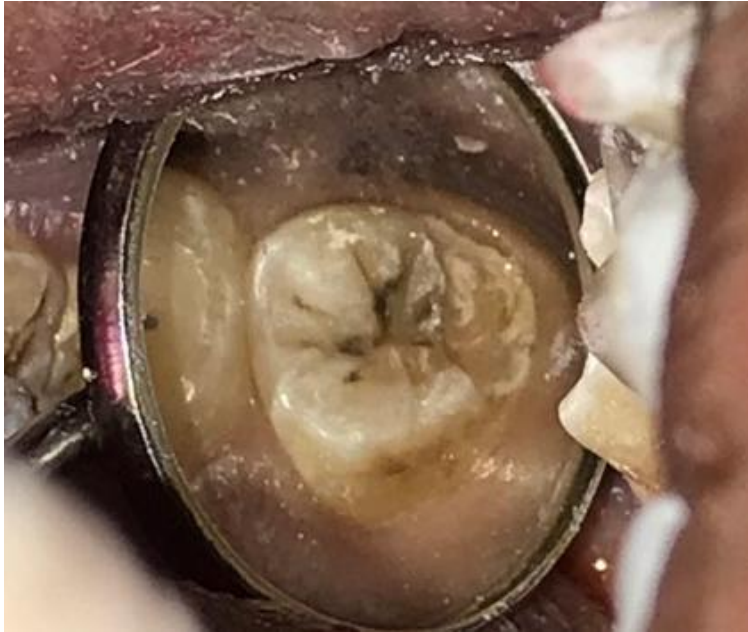( 18 / 28 / 46 / 48 )





# Extraction of Non-restorable Teeth

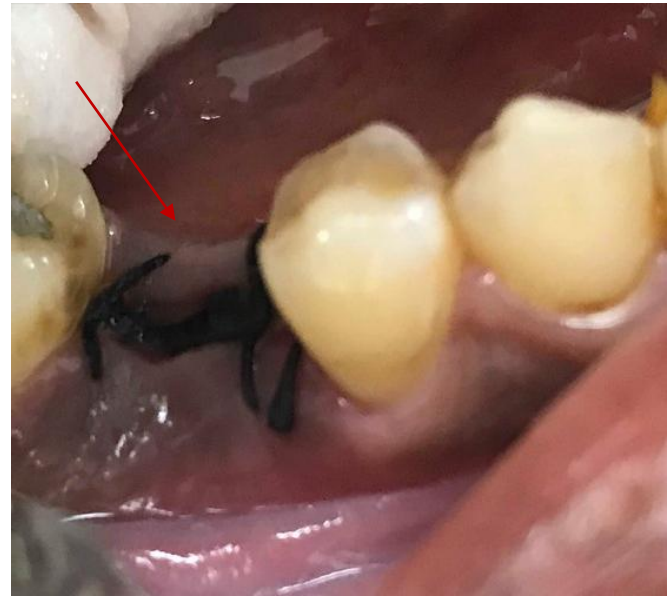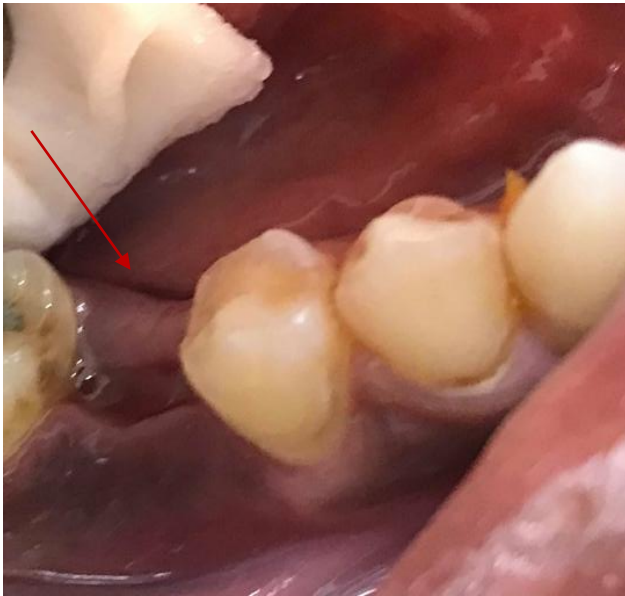
( 18 / 28 / 46 / 48 )







# Site Preparation ( 46 )



# Restorative Phase

- ❖ Root Canal Treatment
- ✓ RCT ( 12-11-21-22-25 )
- ✓ Retreatment ( 23-24 )
- ✓ Management of broken file “ Apicectomy ” ( 24 )

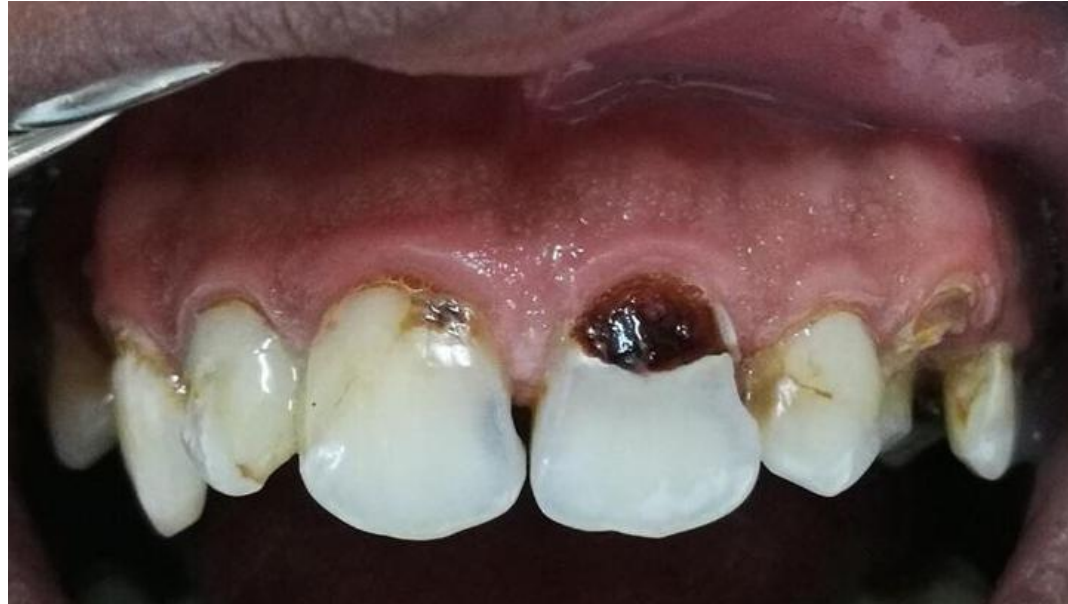

Rotary

# Root Canal Treatment (11)(12)

➤ Phase III Therapy  
Restorative Phase

Pre-operative Photograph



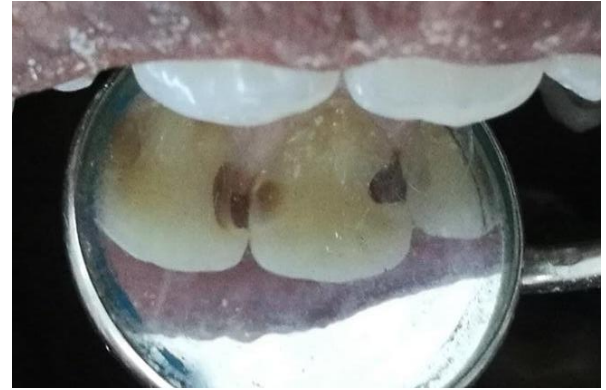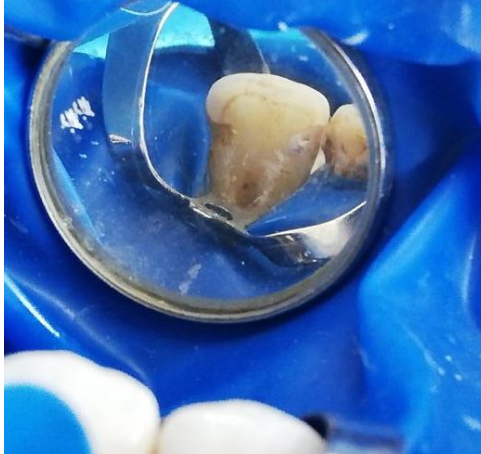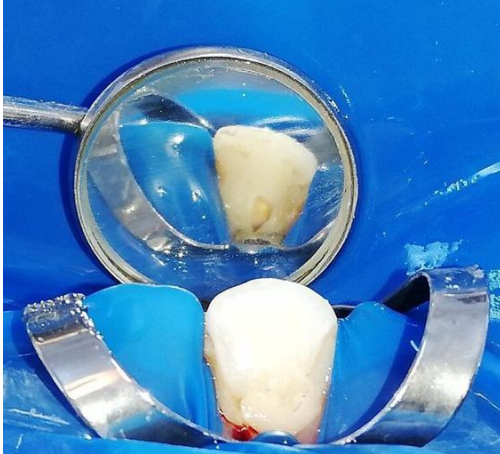


Rotary

Root Canal Treatment Co. (11)(12)

➤ Phase III Therapy  
Restorative Phase

### Access Cavity Preparation



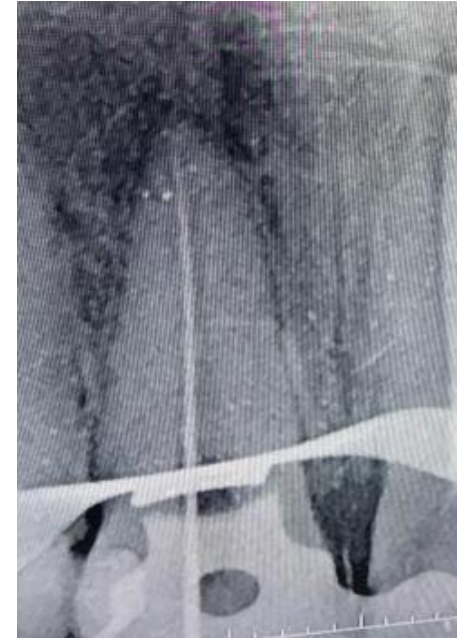
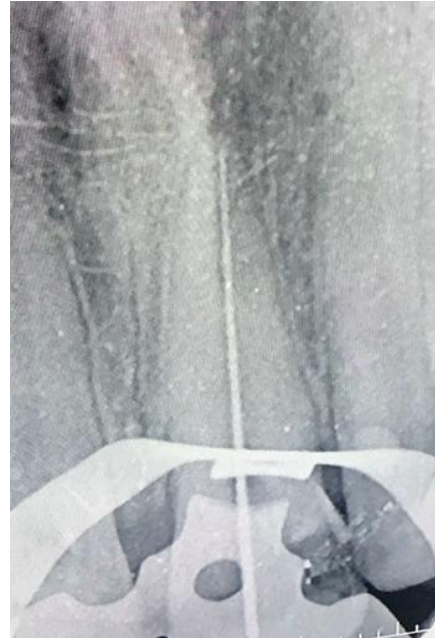
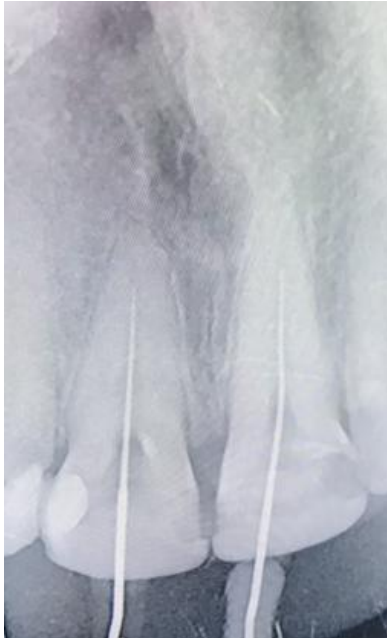Rotary

# Root Canal Treatment Co. ( 11 ) ( 12 )

➤ Phase III Therapy  
Restorative Phase

Pulp Extirpation and working length estimation  
( 26 mm )



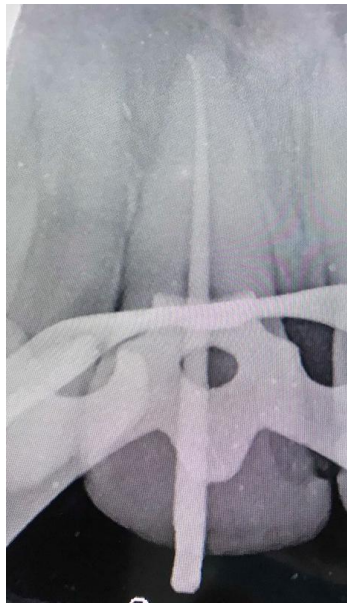

Rotary

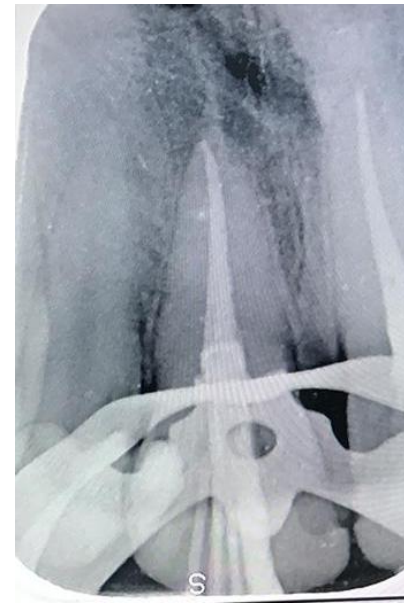# Root Canal Treatment Co. (11) (12)

➤ Phase III Therapy  
Restorative Phase

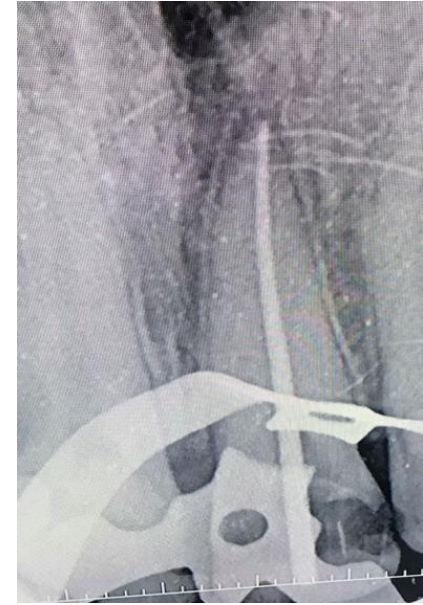Master Cone



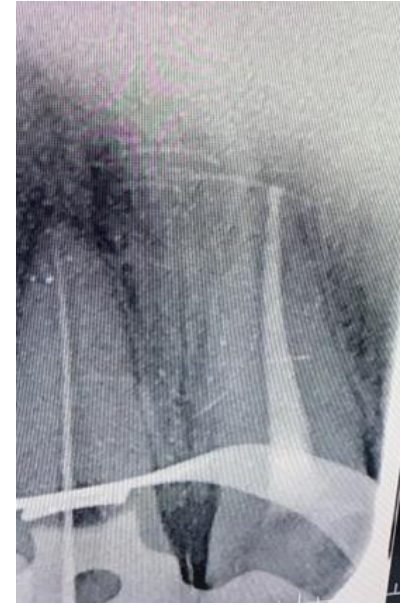Obturation



Master Cone



Obturation

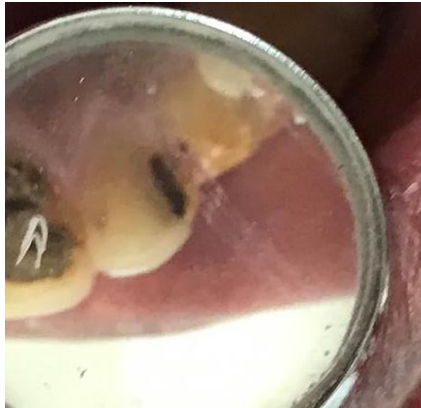
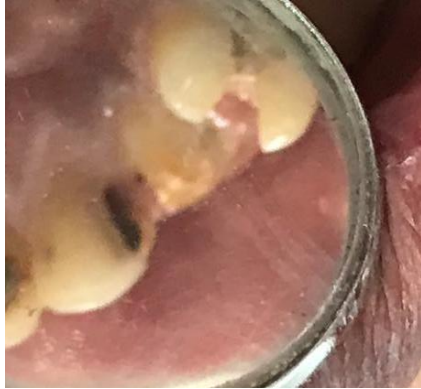


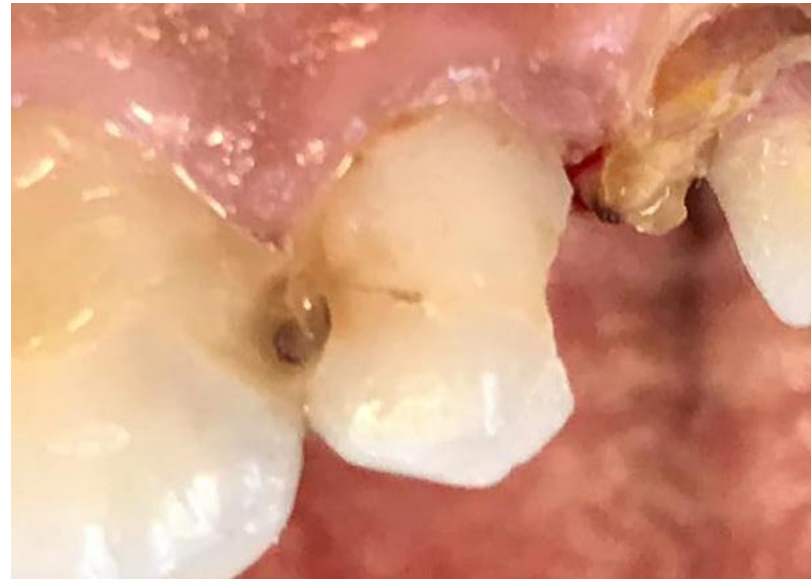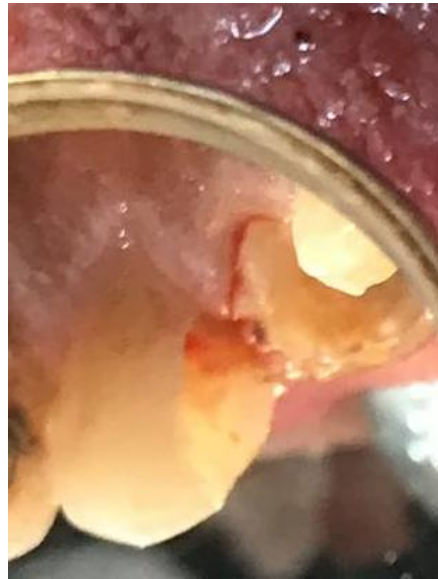Rotary

# Root Canal Treatment Co. ( 22 )

➤ Phase III Therapy  
Restorative Phase



Pre-operative Photograph



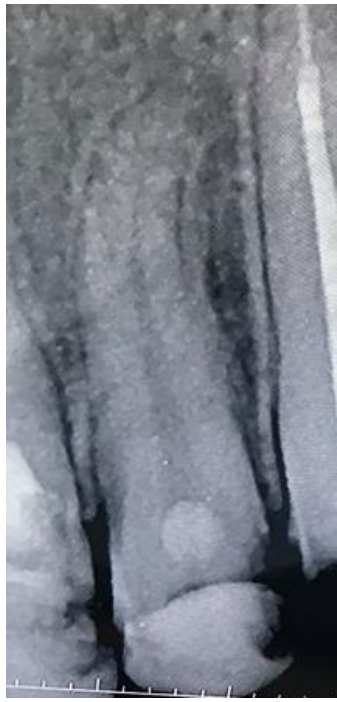

Rotary

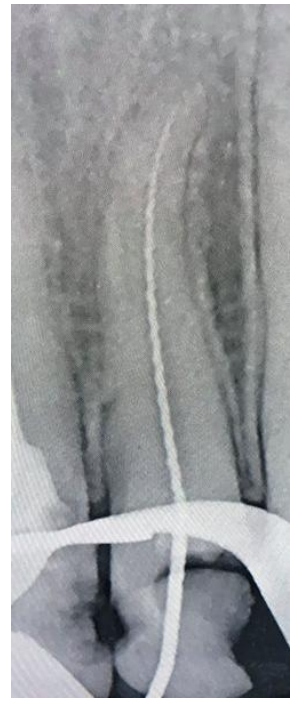# Root Canal Treatment Co. ( 22 )

➤ Phase III Therapy  
Restorative Phase

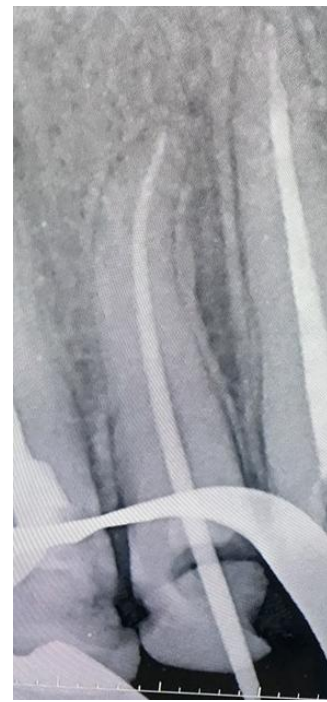Pre-operative



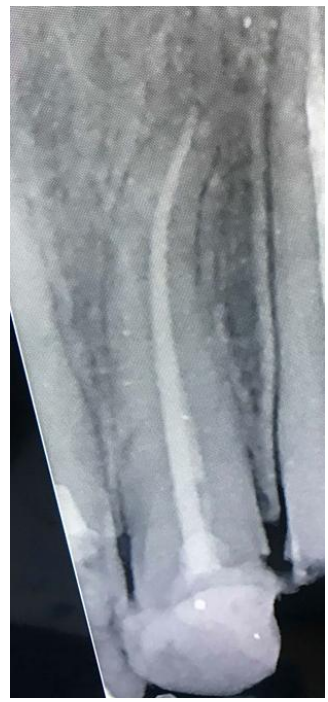W.L ( 23 mm )



Master Cone



Obturation





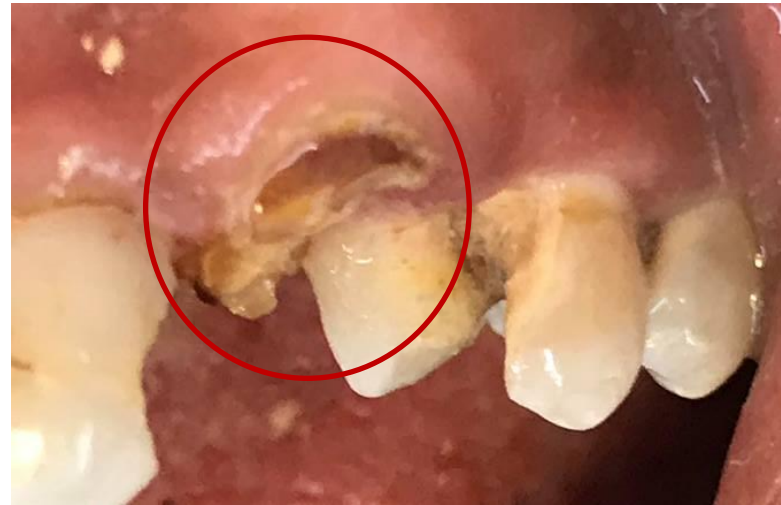
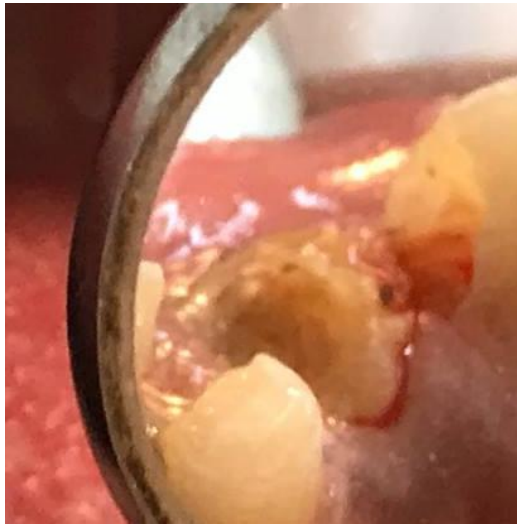
Rotary

# Root Canal Treatment Co. Retreatment ( 23 )

➤ Phase III Therapy  
Restorative Phase

Pre-operative Photograph



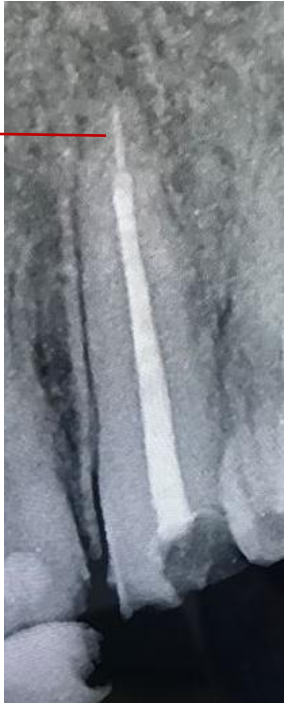


Rotary

# Root Canal Treatment Co. Retreatment ( 23 )

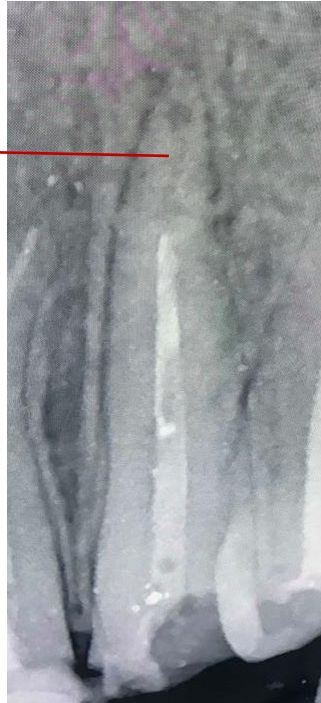➤ Phase III Therapy  
Restorative Phase

Pre-operative



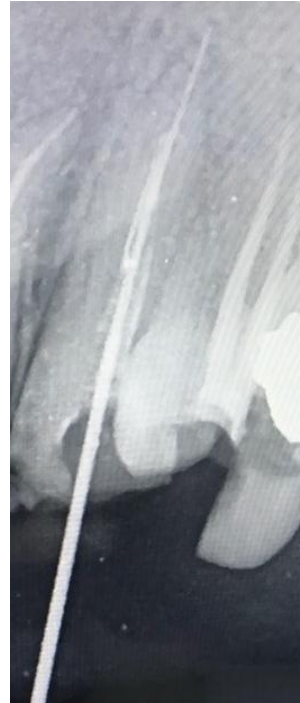Broken File

G.P removal

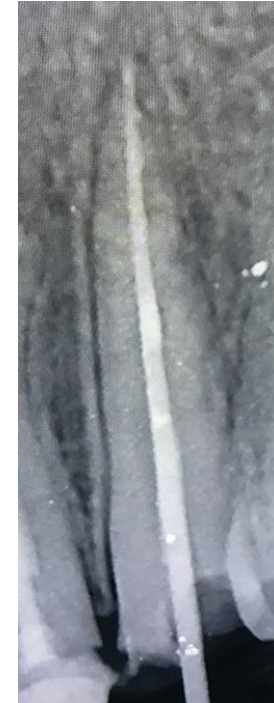

Broken File was removed

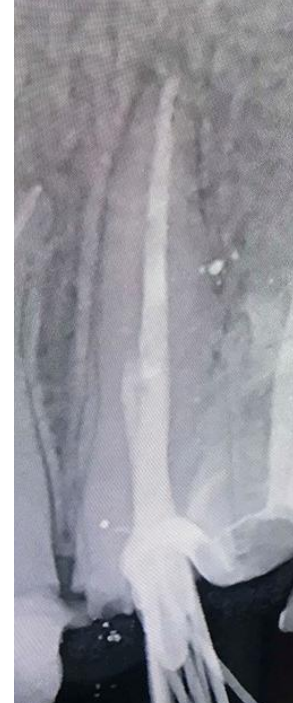W.L ( 30 mm )



Master Cone



Obturation



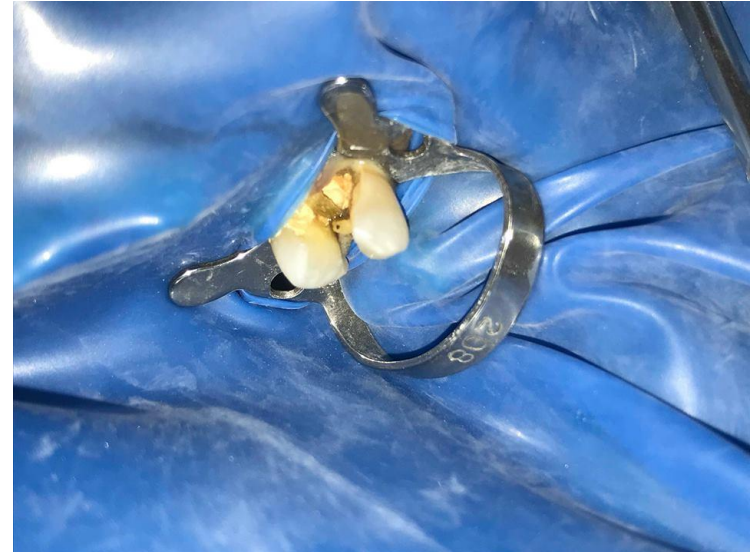
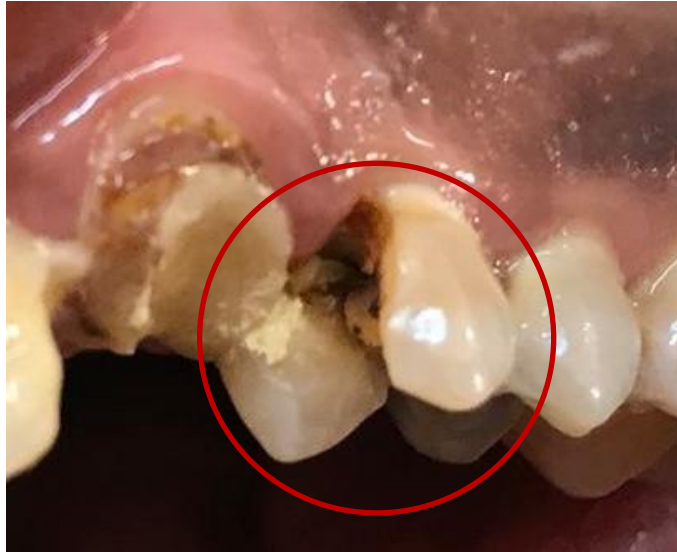
Rotary

# Root Canal Treatment Co. Retreatment ( 24 )

➤ Phase III Therapy  
Restorative Phase

Pre-operative Photograph and  
Access Cavity Preparation



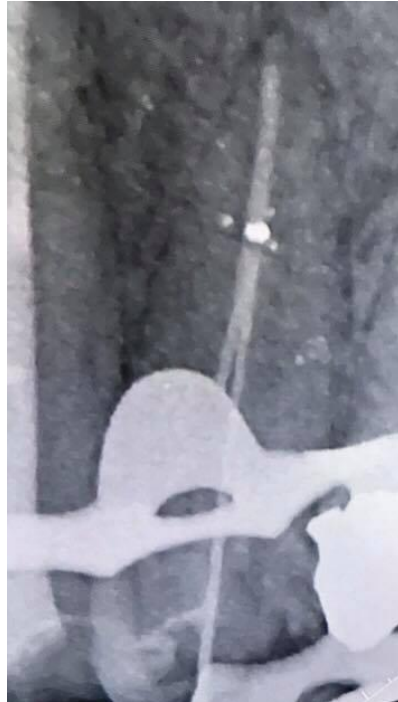

Rotary

# Root Canal Treatment Co. Retreatment ( 24 )

➤ Phase III Therapy  
Restorative Phase

Pre-operative



A broken file was found near the apical part of the canal of the buccal root.

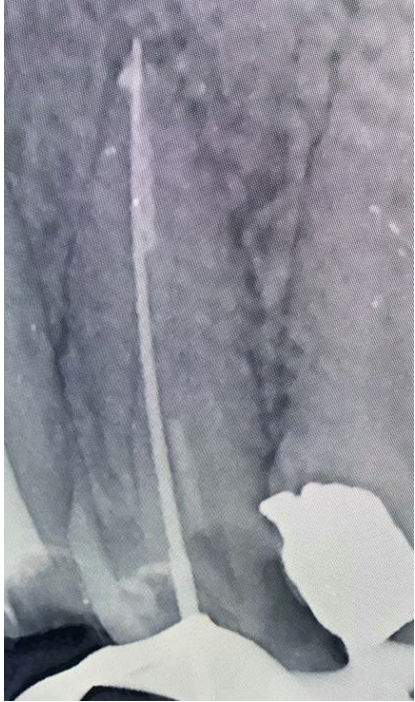


Rotary

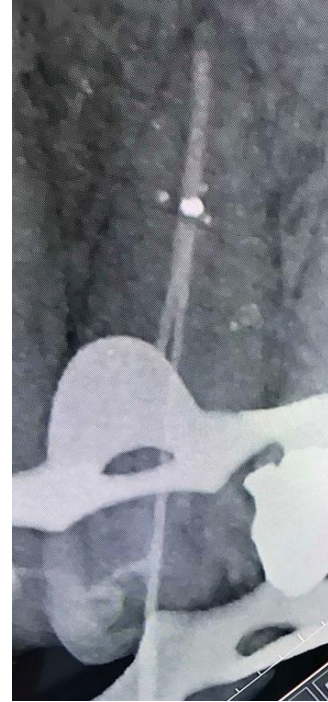# Root Canal Treatment Co. Retreatment ( 24 )

➤ Phase III Therapy  
Restorative Phase

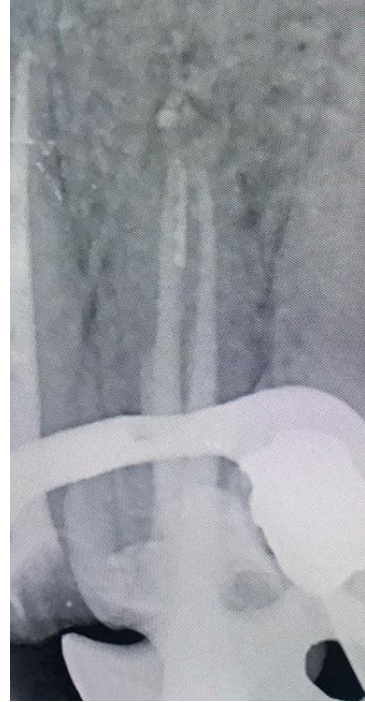Bypass



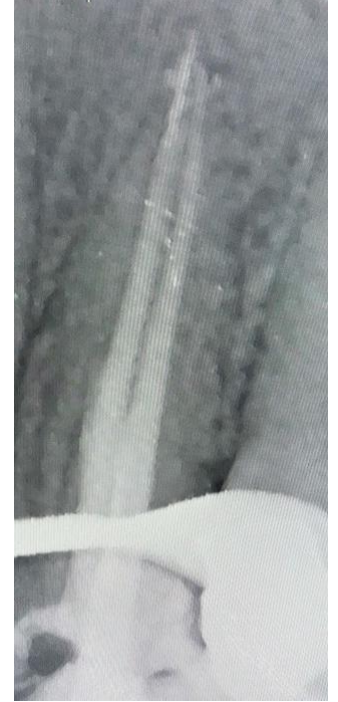W.L ( P 21 mm )  
( B 22 mm )



Master Cone



Obturation



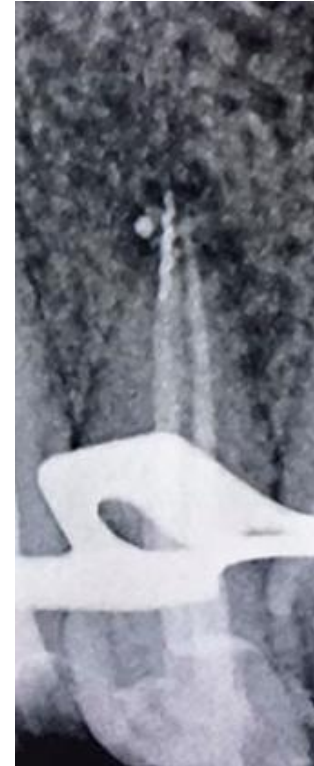
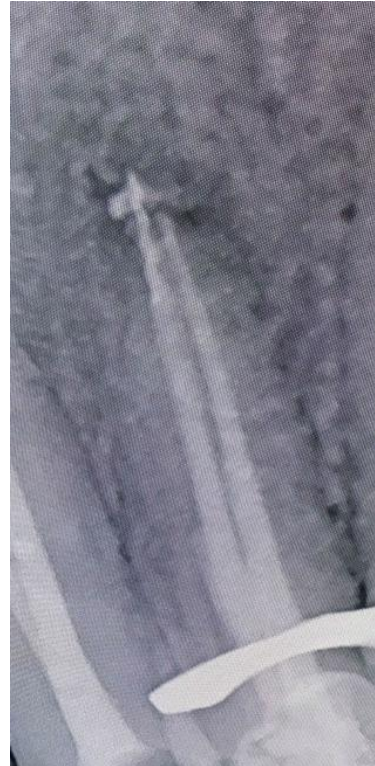
Rotary

# Root Canal Treatment Co. Retreatment ( 24 )

➤ Phase III Therapy  
Restorative Phase

- ✓ Patient returned with pain related to the previously treated upper left first premolar.
- ✓ X-ray showed that the file was pushed beyond the apex.



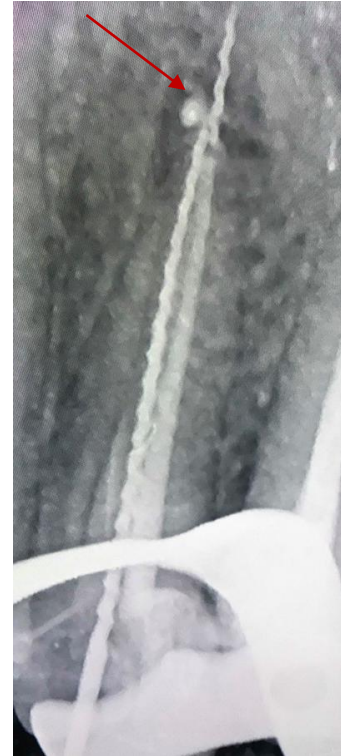
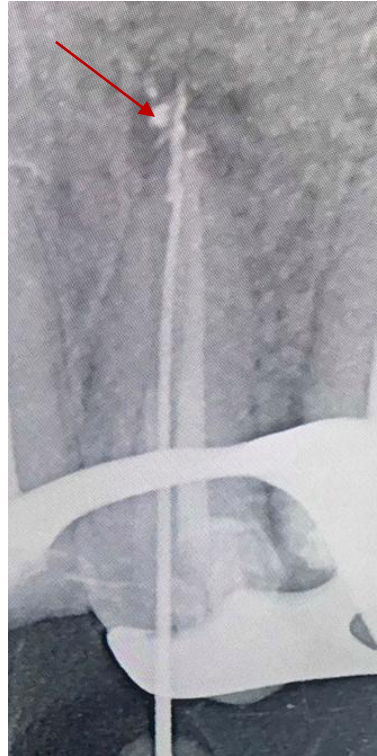
Rotary

# Root Canal Treatment Co. Retreatment ( 24 )

➤ Phase III Therapy  
Restorative Phase

- ✓ A second retreatment was started in the buccal canal.
- ✓ An apicectomy was performed to remove the broken file.

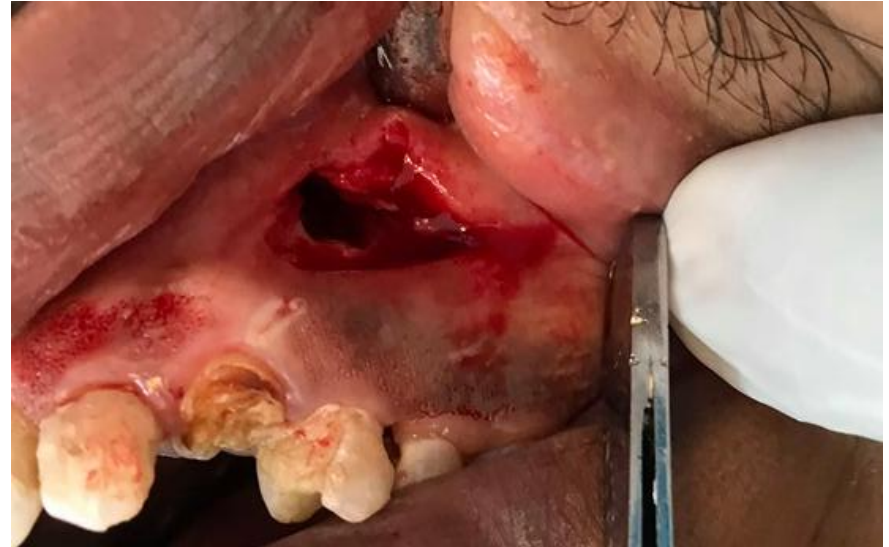
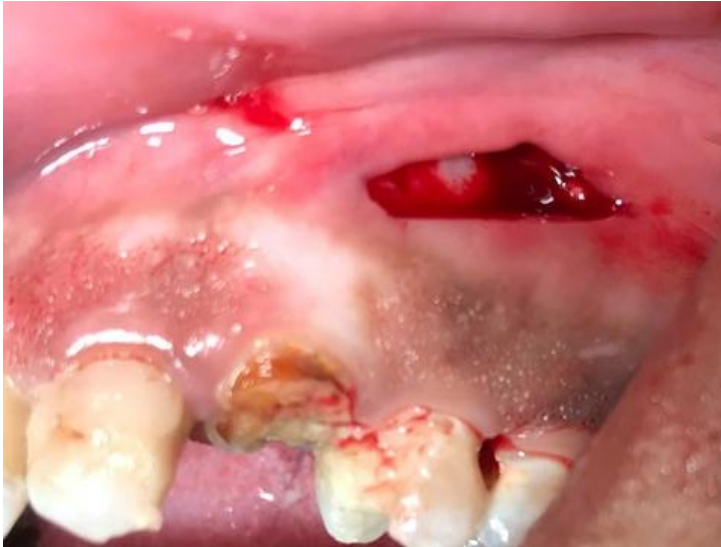


Management of Broken File

# Apicectomy ( 24 )

Semilunar flap was used

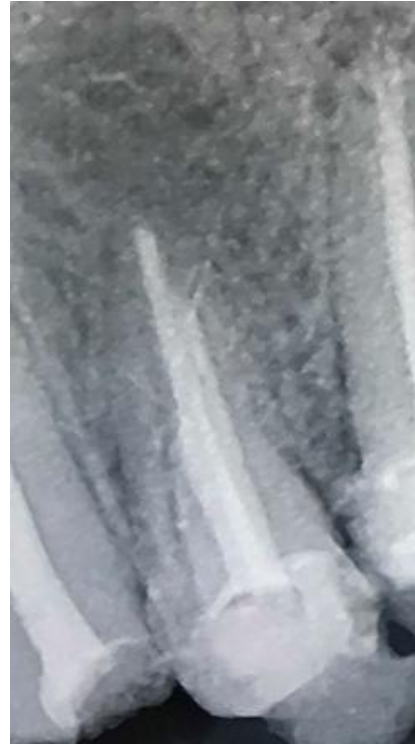
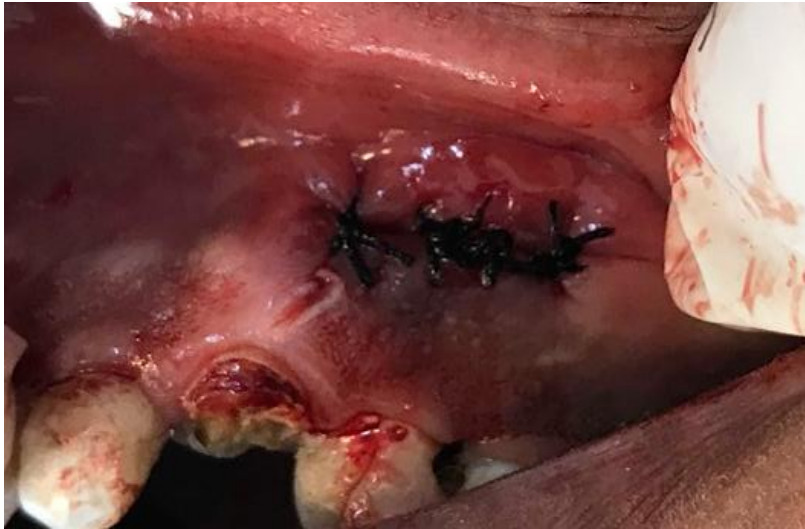




## Management of Broken File

# Apicectomy ( 24 )



- ✓ A post operative radiograph was taken.
- ✓ No retrograde filling was needed

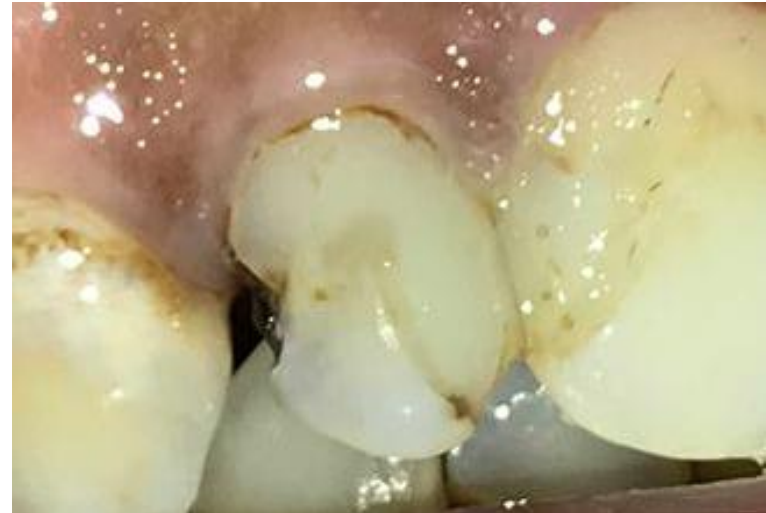
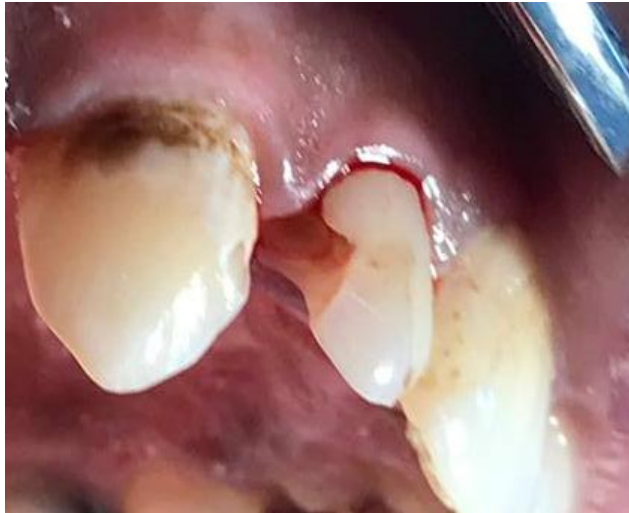
Rotary

# Root Canal Treatment Co. (12)

➤ Phase III Therapy  
Restorative Phase

Pre-operative Photograph



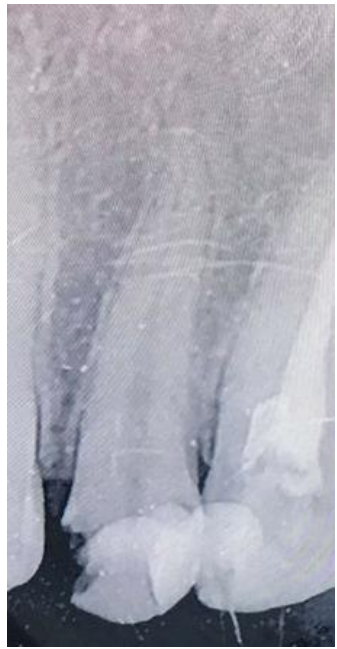

Rotary

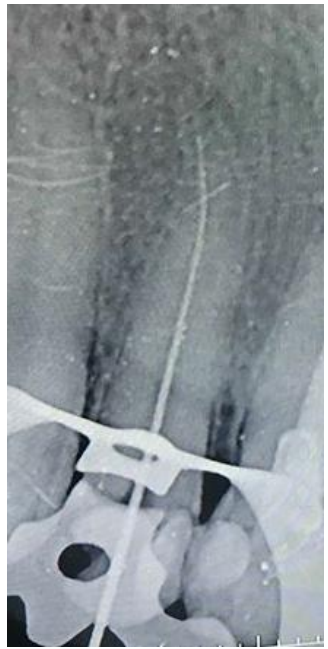
# Root Canal Treatment Co. ( 12 )

➤ Phase III Therapy  
Restorative Phase

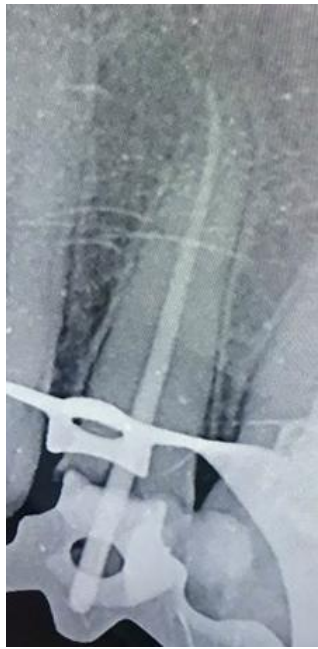Pre-operative



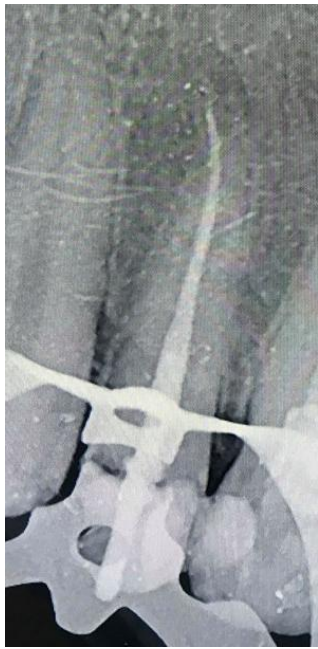W.L ( 24 mm )



Master Cone



Obturation



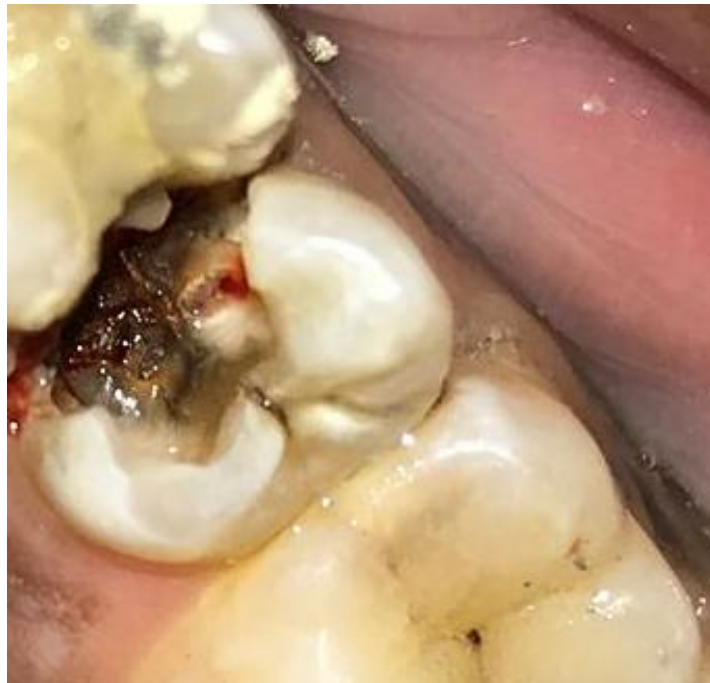

Rotary

# Root Canal Treatment Co. ( 25 )

➤ Phase III Therapy  
Restorative Phase

Pre-operative Photograph



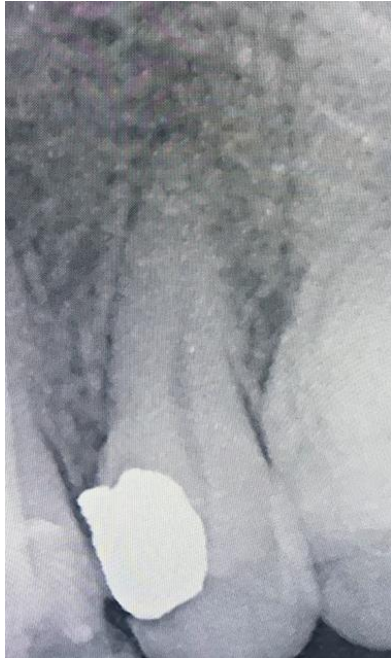

Rotary

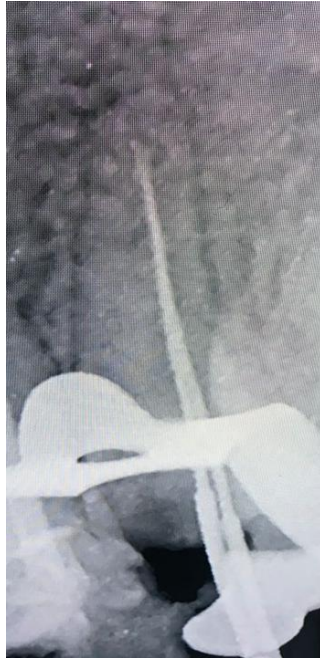# Root Canal Treatment Co. ( 25 )

➤ Phase III Therapy  
Restorative Phase

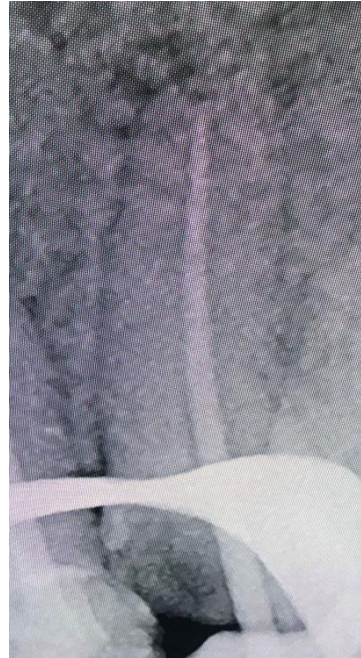Pre-operative



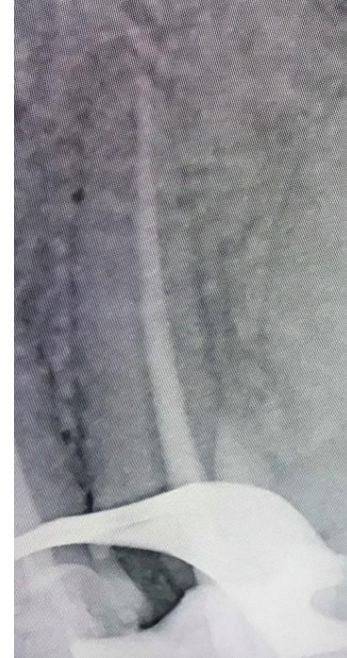
W.L ( mm )



Master Cone

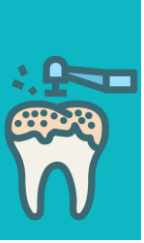

Obturation



# Restorative Phase

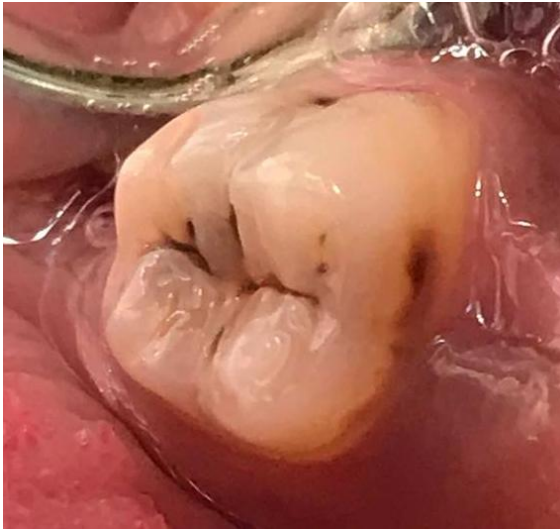- ❖ Prosthetic reconstruction of decayed teeth :
- ✓ Composite restoration ( 37-42-43-44-45-41-42-31-32-35-47-27-26 )



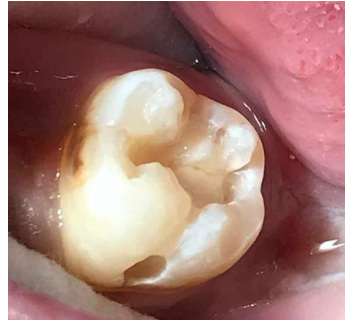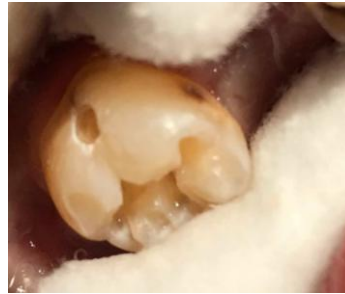# Composite Restoration ( 37 )

- ✓ Class I + Buccal pit.
- ✓ Shade : A2

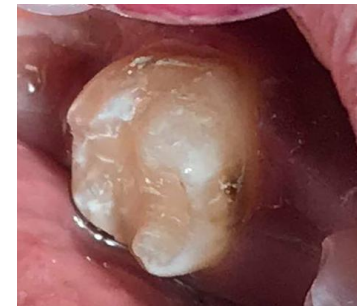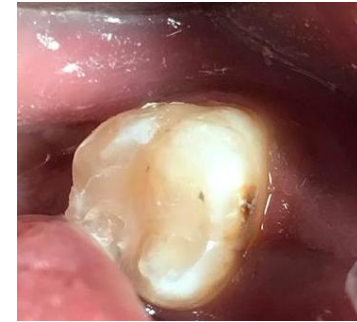Pre-operative



Caries Excavation



Post-operative

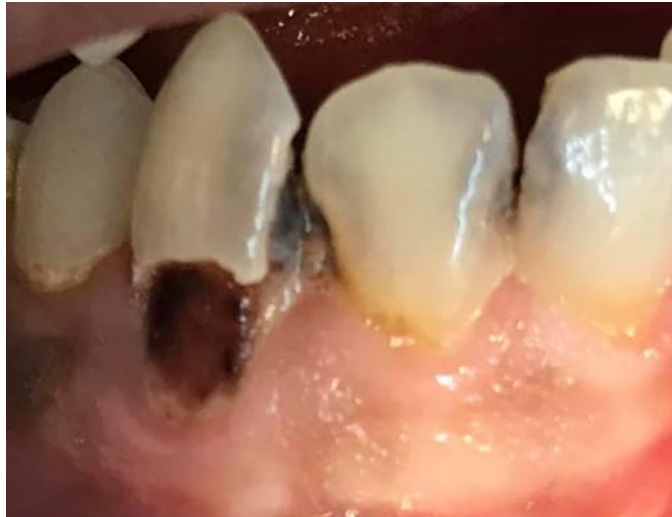



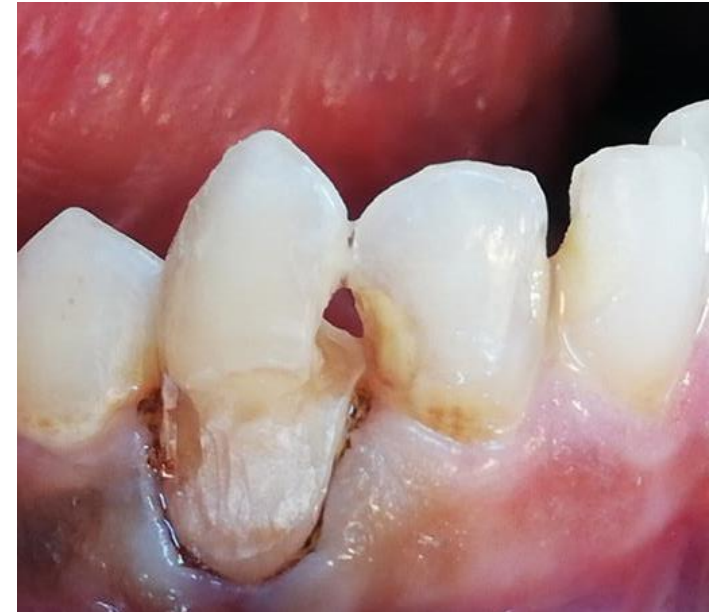# Composite Restoration ( 42 ) ( 43 )

- ✓ Class III + V.
- ✓ Shade : A2/ A3

Pre-operative



Caries Excavation

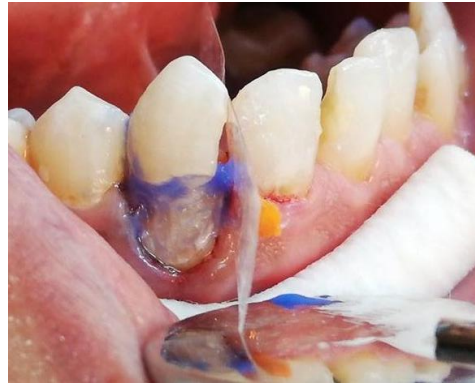
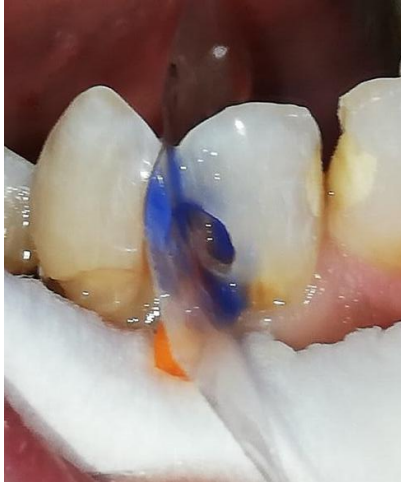




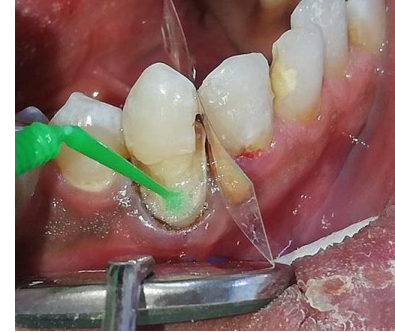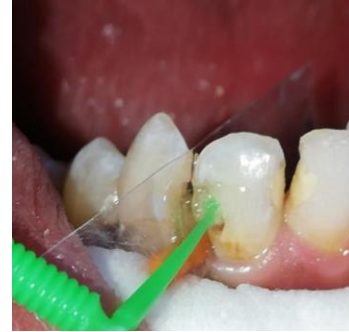# Composite Restoration ( 42 ) ( 43 )

Acid Etching



Bonding

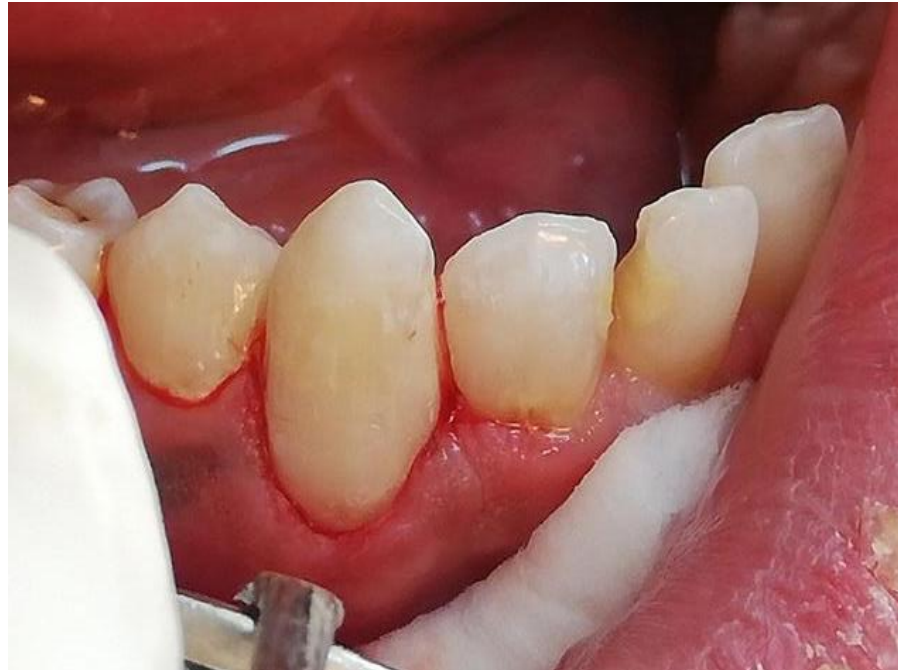



- Phase III Therapy  
Restorative Phase

# Composite Restoration (42)(43)

Post-Operative

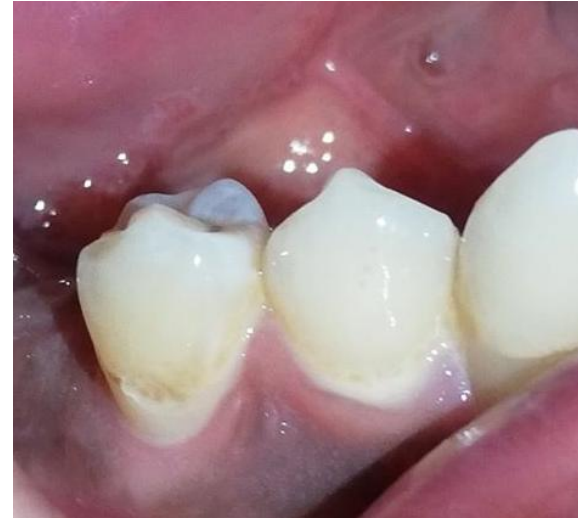
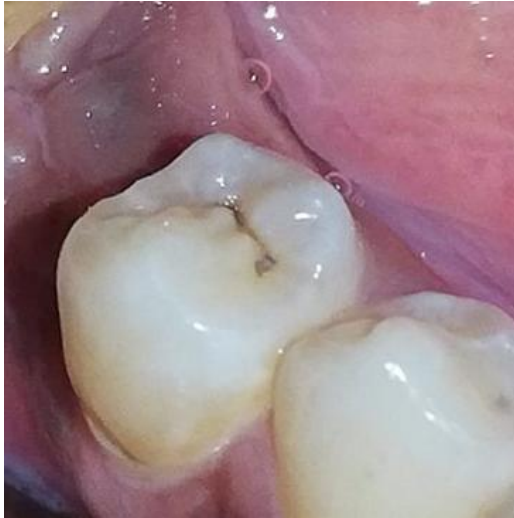


# Composite Restoration ( 45 )

- ✓ Class I + V.
- ✓ Shade : A2

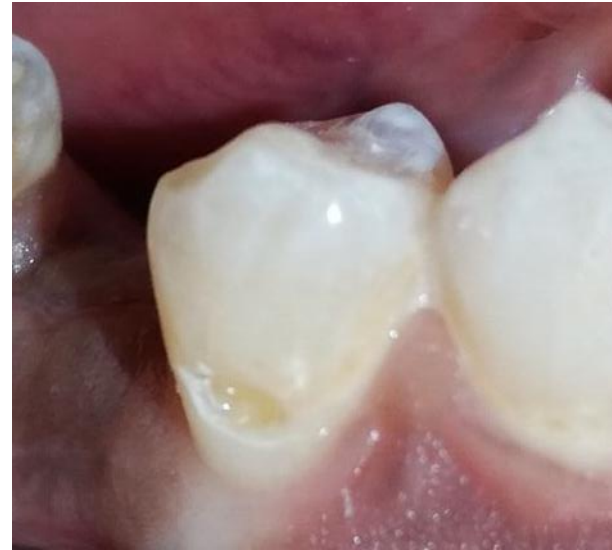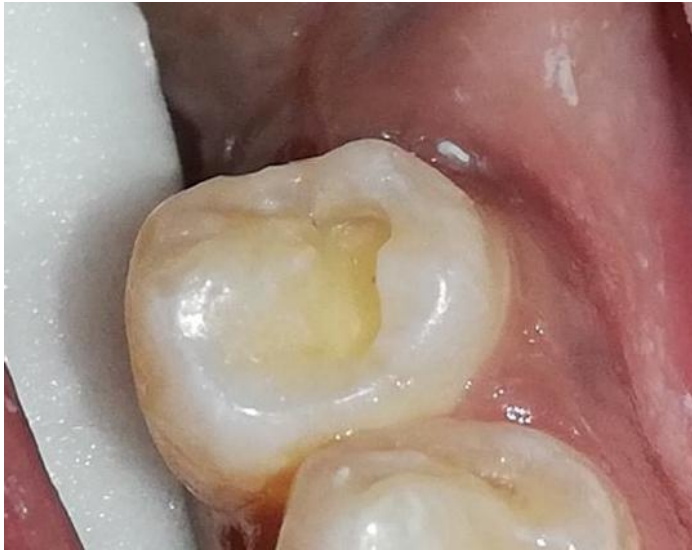Pre-Operative





# Composite Restoration ( 45 )

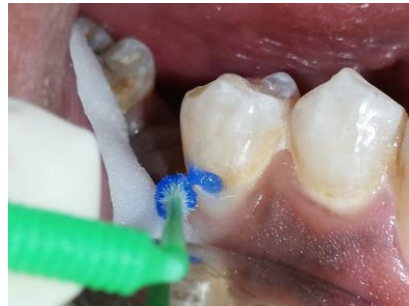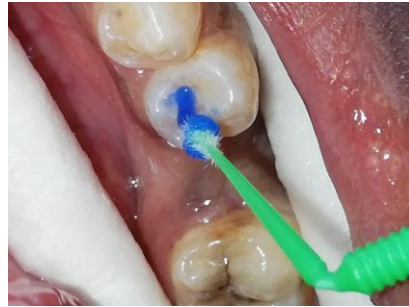
## Caries Removal



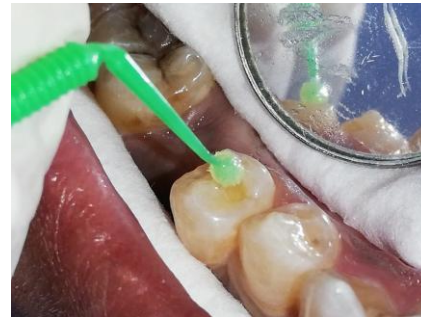
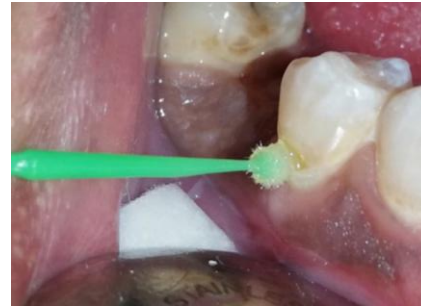
# Composite Restoration ( 45 )

Acid Etching



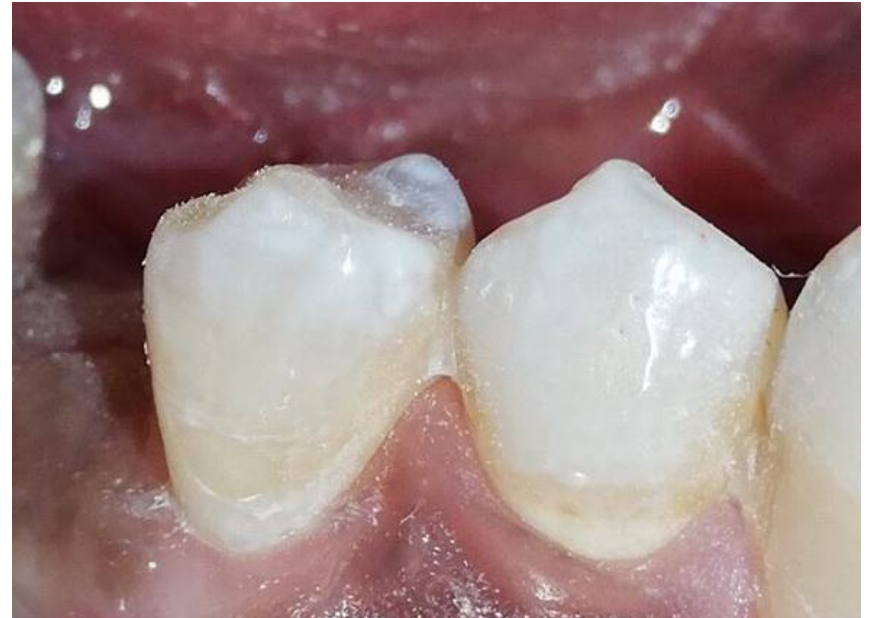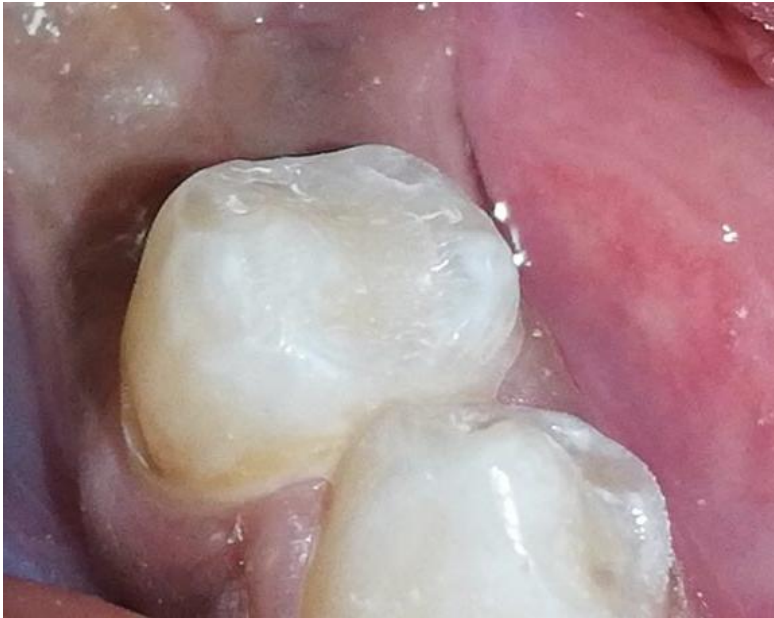Bonding





# Composite Restoration ( 45 )

Post-Operative

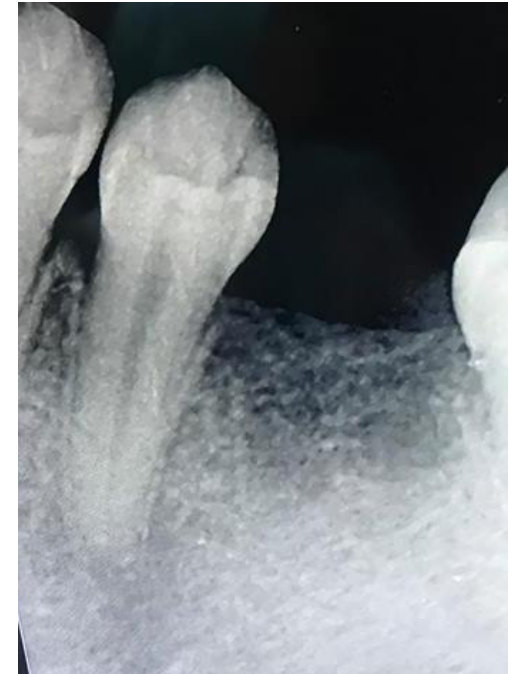
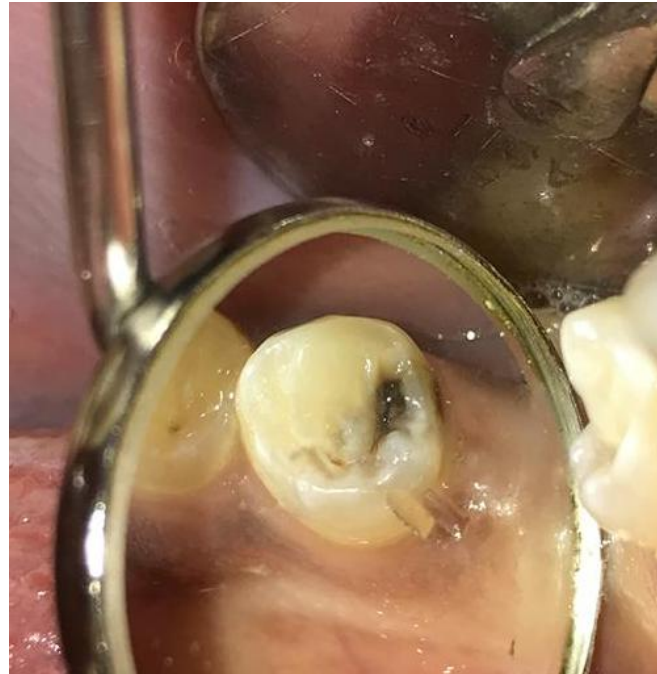


# Composite Restoration ( 35 )

- ✓ Class II
- ✓ Shade : A2

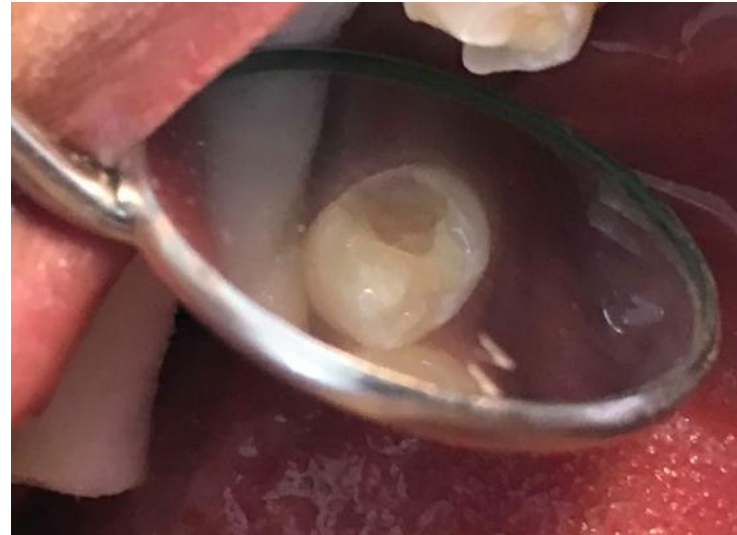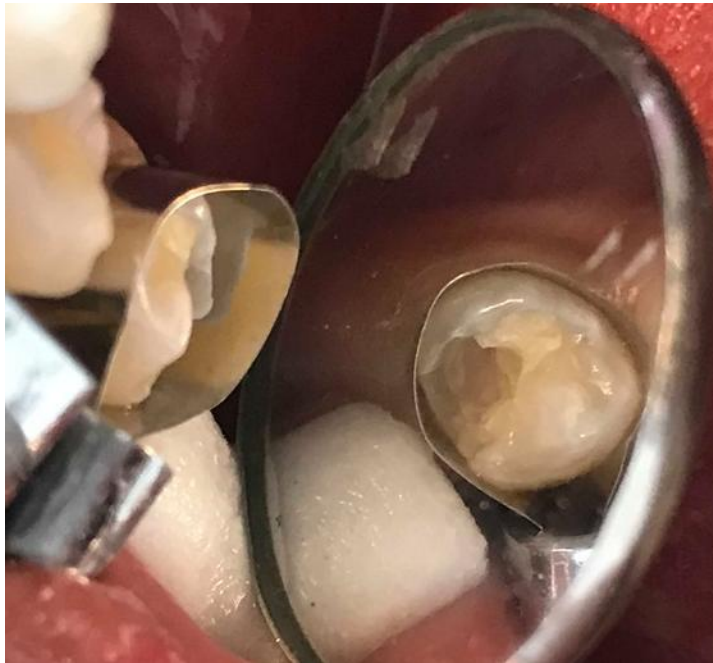## Pre-Operative



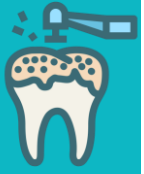

# Composite Restoration ( 35 )

## Caries Removal



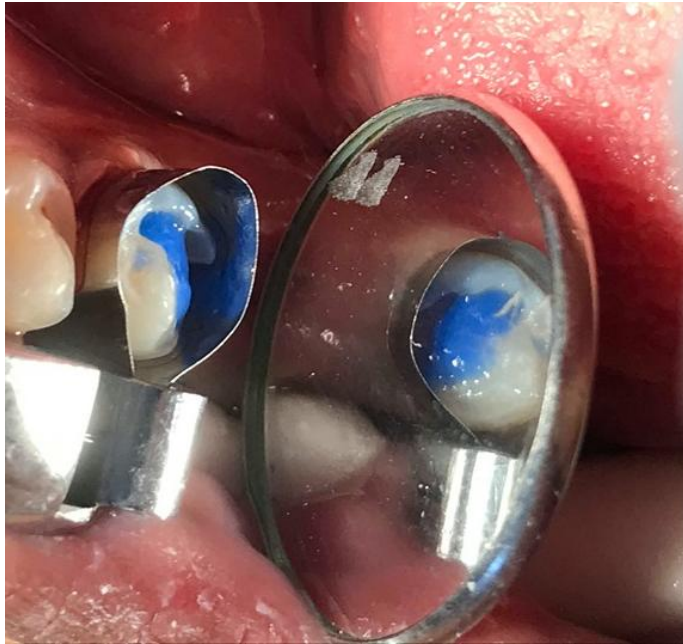



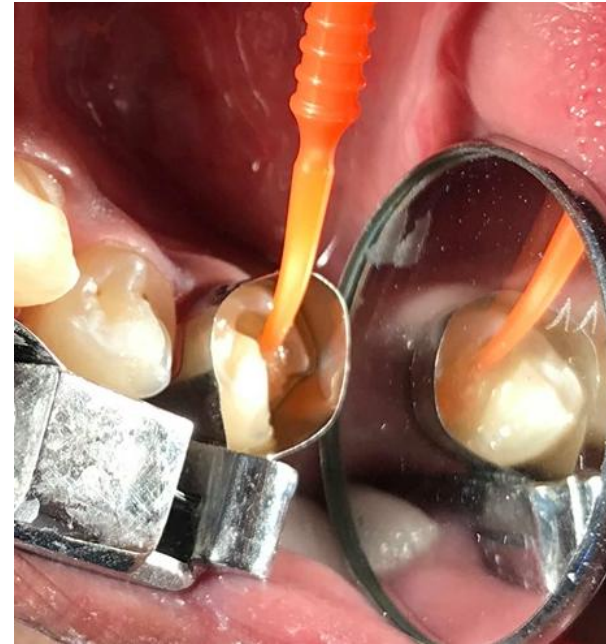# Composite Restoration

( 35 )

Acid Etching



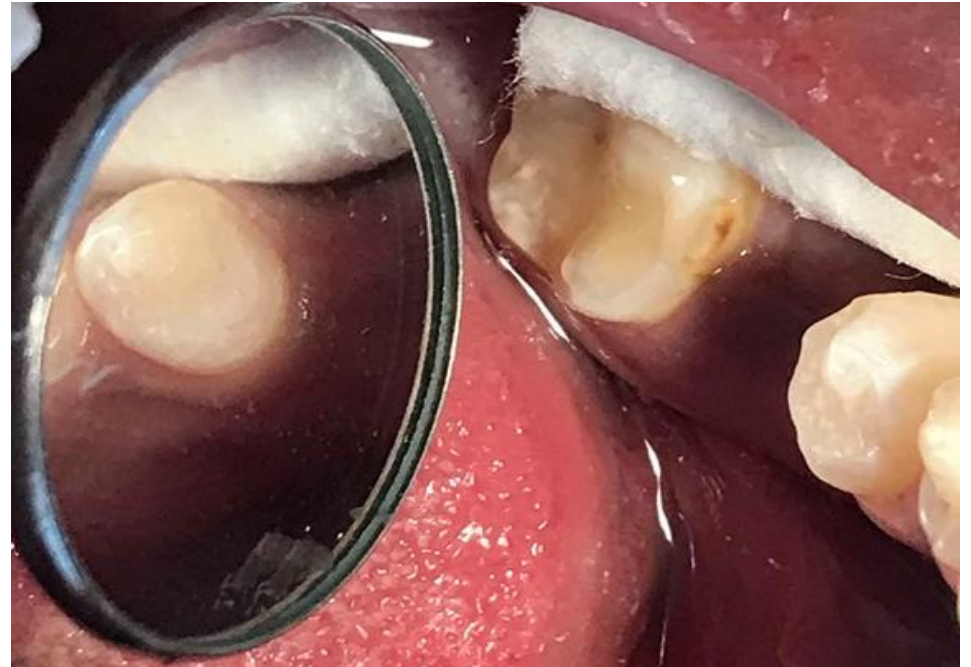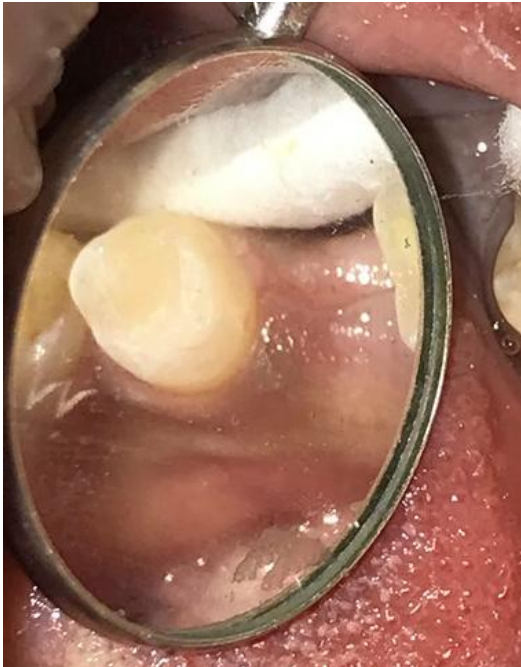Bonding





# Composite Restoration ( 35 )

Post-Operative

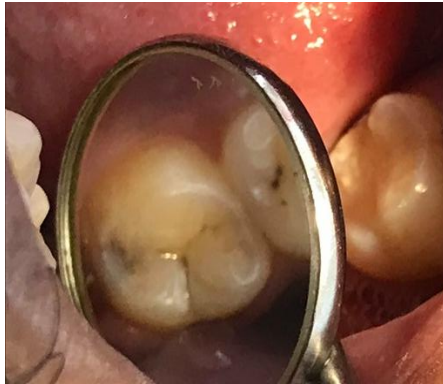



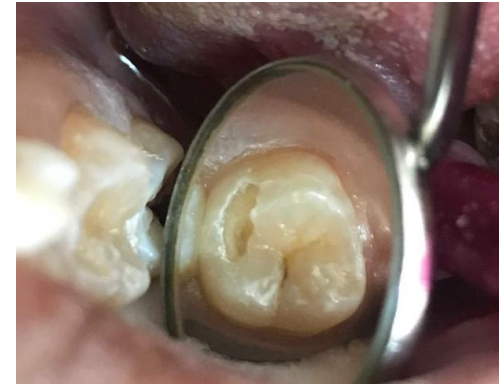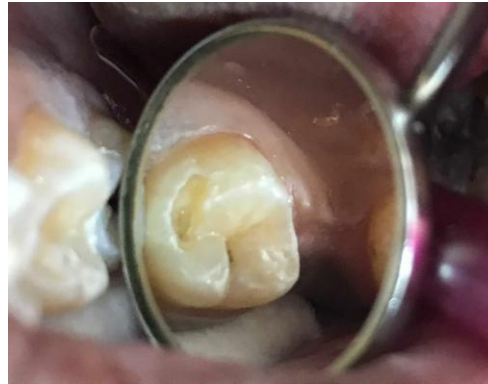# Composite Restoration ( 27 )

- ✓ Class I
- ✓ Shade : A2

Pre-Operative



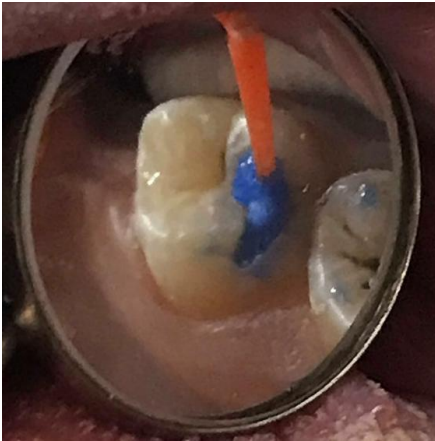
Caries Removal



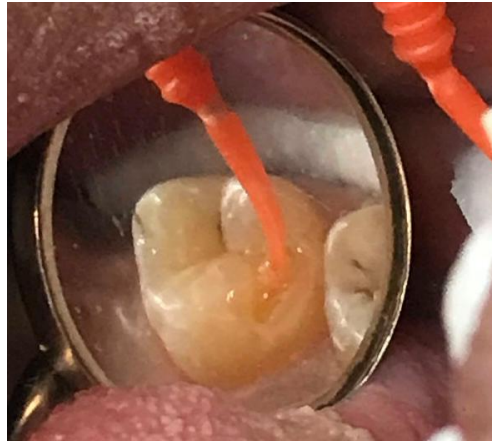

# Composite Restoration ( 27 )

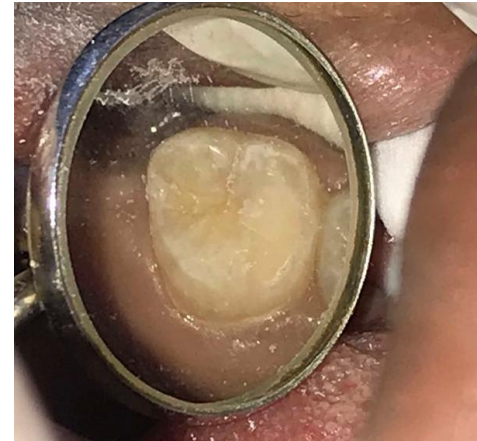Acid Etching

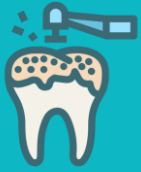

Bonding



Post-Operative

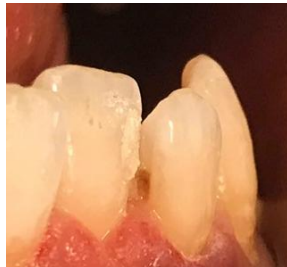
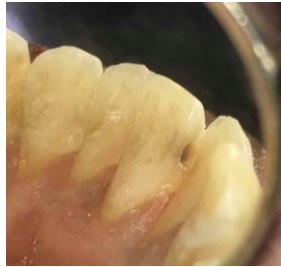


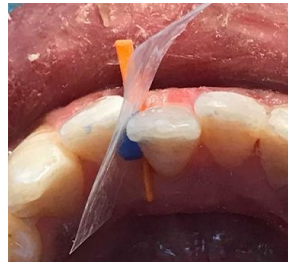
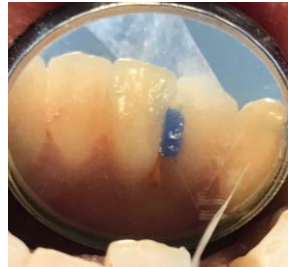
# Composite Restoration ( 31-32 )

- ✓ Class III.
- ✓ Shade : A2

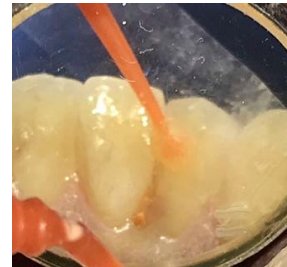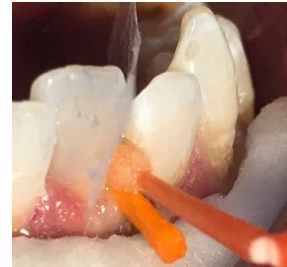Pre-Operative



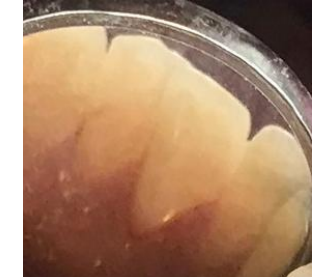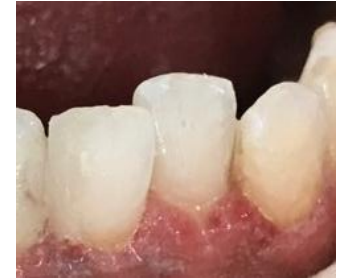Acid Etching



Bonding



Post-Operative

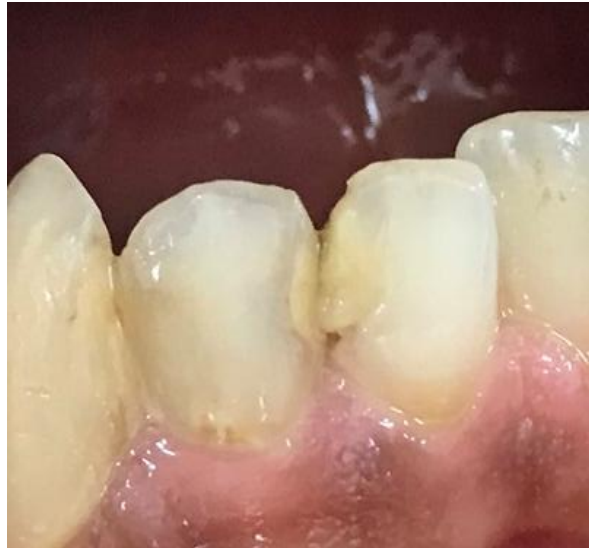



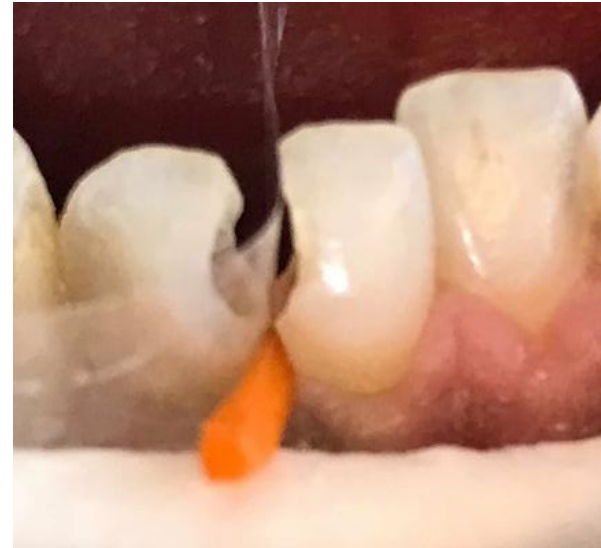# Composite Restoration ( 41 - 42 )

- ✓ Class III.
- ✓ Shade : A2

Pre-Operative



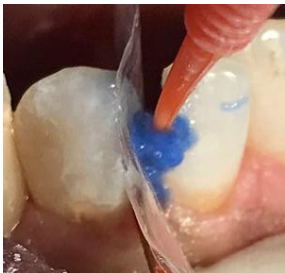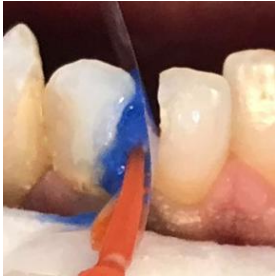Caries Removal



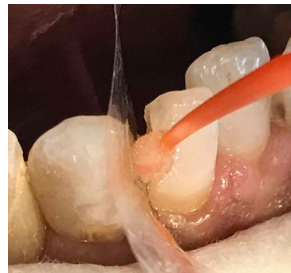
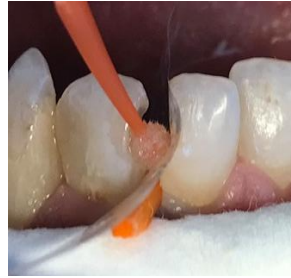
# Composite Restoration ( 41 – 42 )

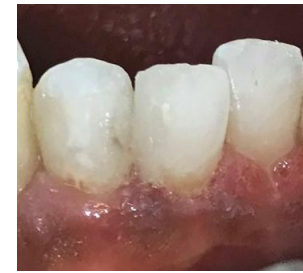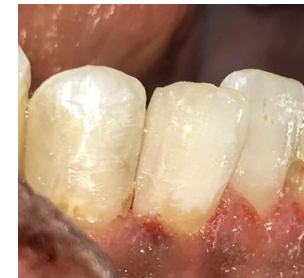Acid Etching



Bonding



Post-Operative

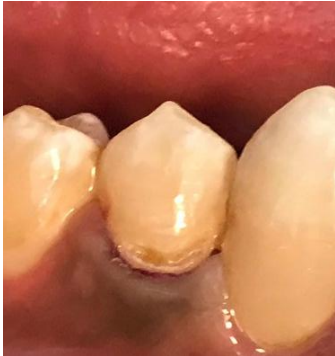



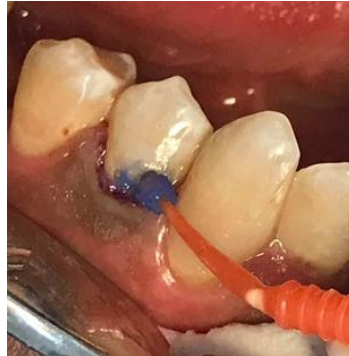# Composite Restoration ( 44 )

- ✓ Class V.
- ✓ Shade : A3

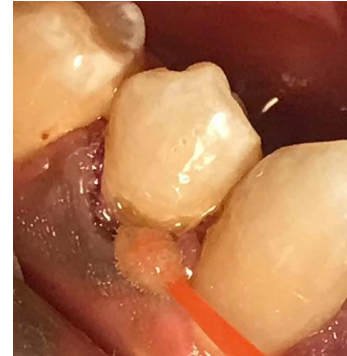Caries Removal



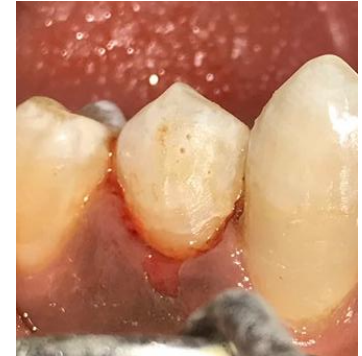Acid Etching



Bonding



Post-Operative



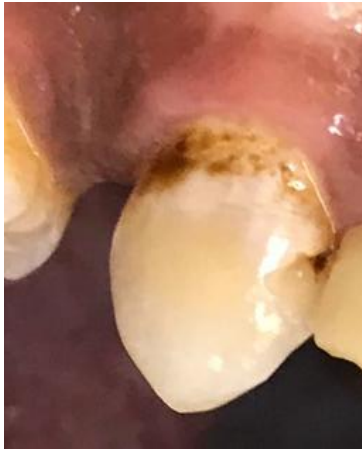



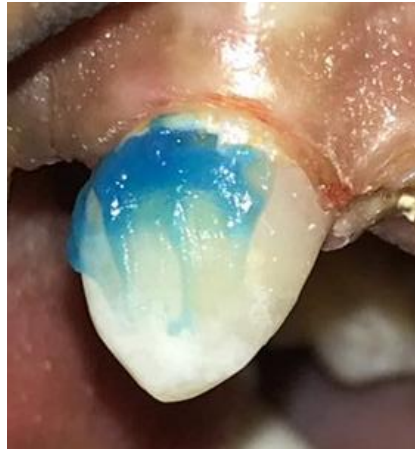# Composite Restoration ( 13 )

- ✓ Class V.
- ✓ Shade : A3

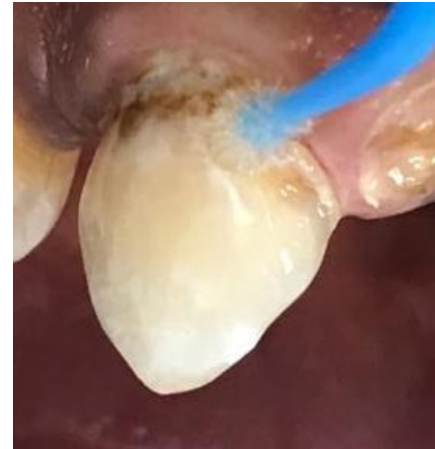Pre-Operative



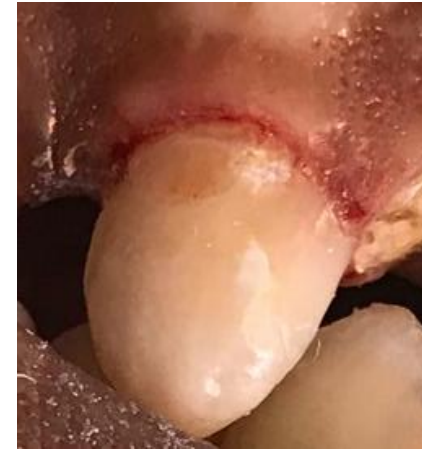Acid Etching

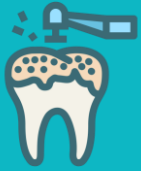

Bonding



Post-Operative



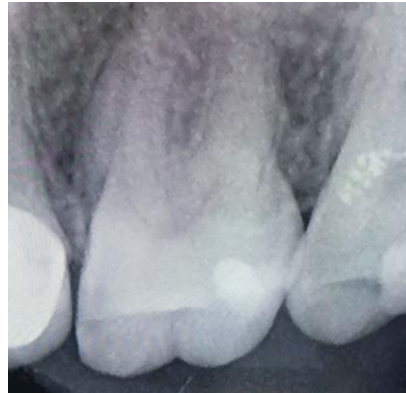
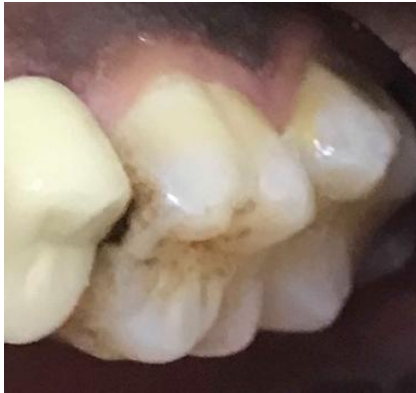
# Composite Restoration

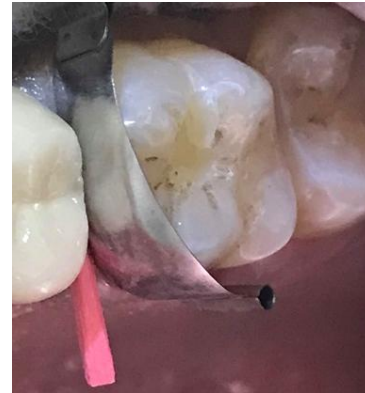( 26 )

- ✓ Class II.
- ✓ Shade : A2

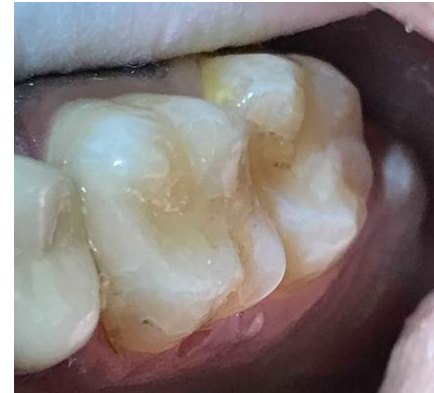Pre-Operative



Caries Removal



Post-Operative

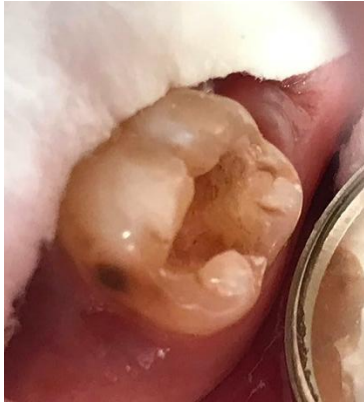



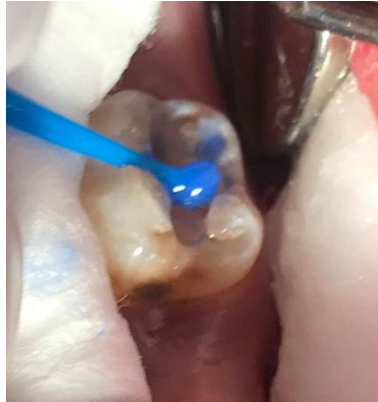# Composite Restoration ( 47 )

- ✓ Class I.
- ✓ Shade : A2

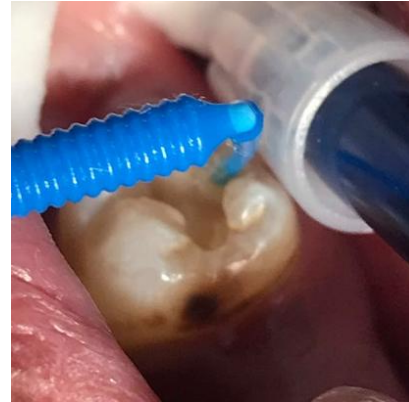Caries Removal



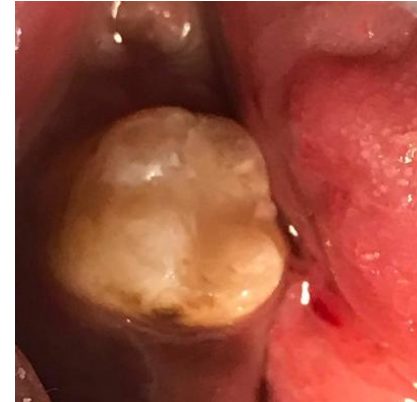Acid Etching



Bonding



Post-Operative



# Restorative Phase


## Prosthetic reconstruction of decayed teeth



Custom made post and core,  
and crown ( 12 – 23 – 24 )



Fiber post, core and  
crown ( 11 – 21 – 22 )

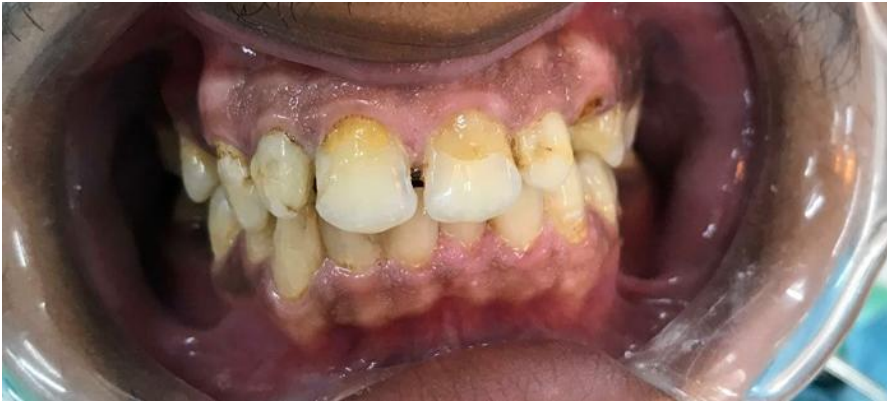

Metal post, core  
and crown ( 25 )

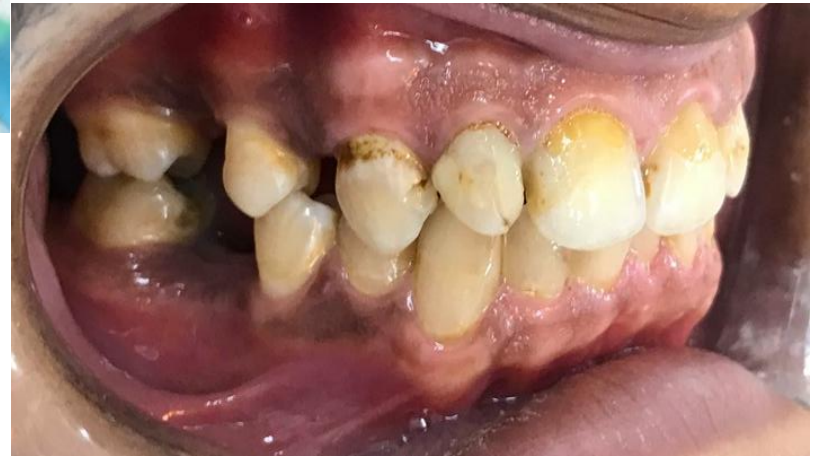

- Phase III Therapy  
Restorative Phase

## Post, Core and Crown



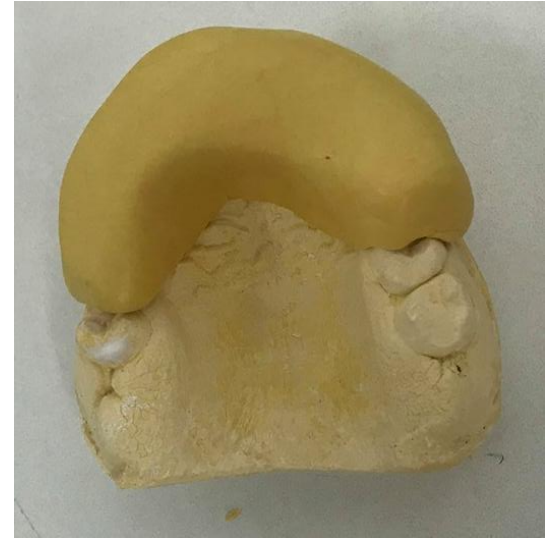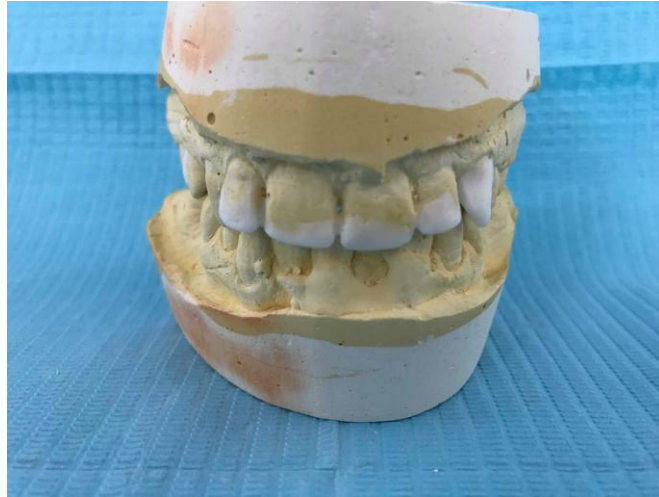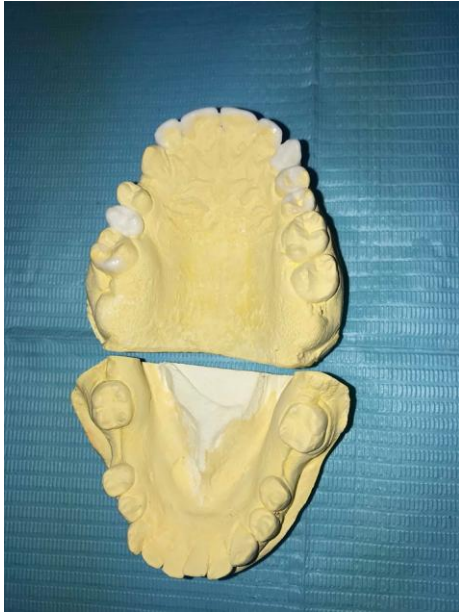Pre-Operative Photographs

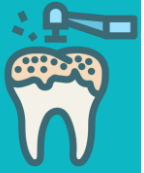



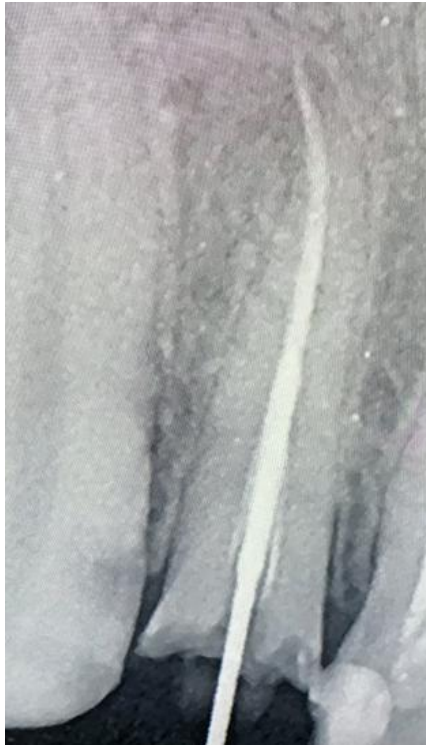- Phase III Therapy  
Restorative Phase

## Post, Core and Crown





# Post, Core and Crown

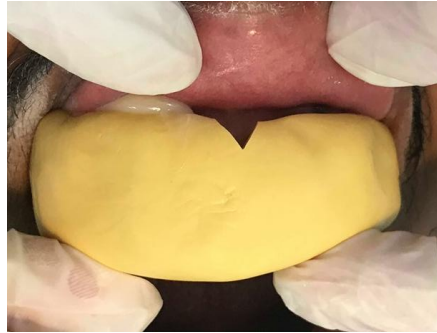
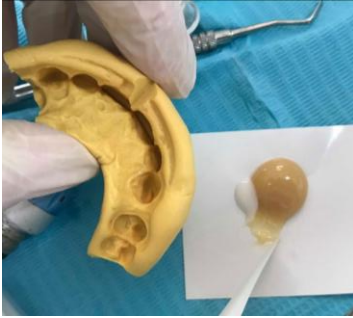
Canal Preparation  
( 12 )

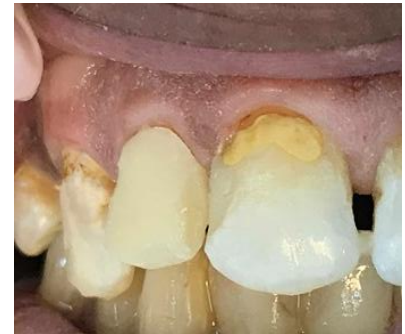
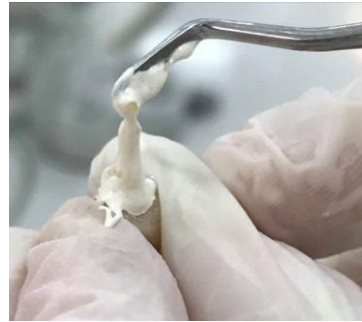
# Post, Core and Crown

- Phase III Therapy  
Restorative Phase



Temporary crown  
( 12 )

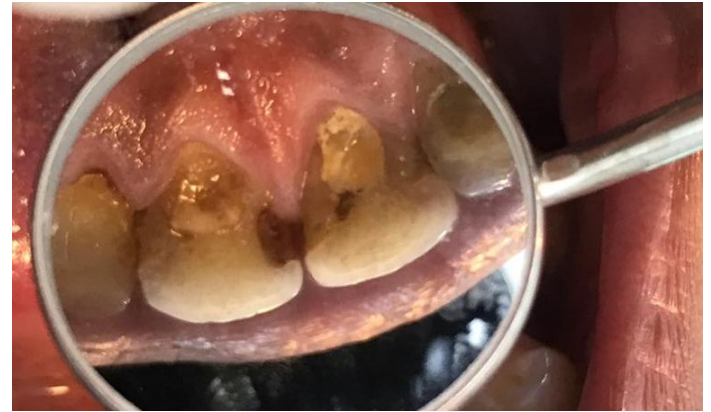
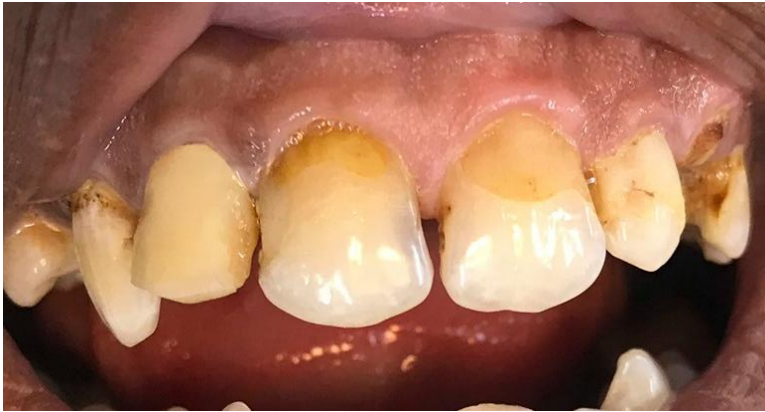





- Phase III Therapy  
Restorative Phase

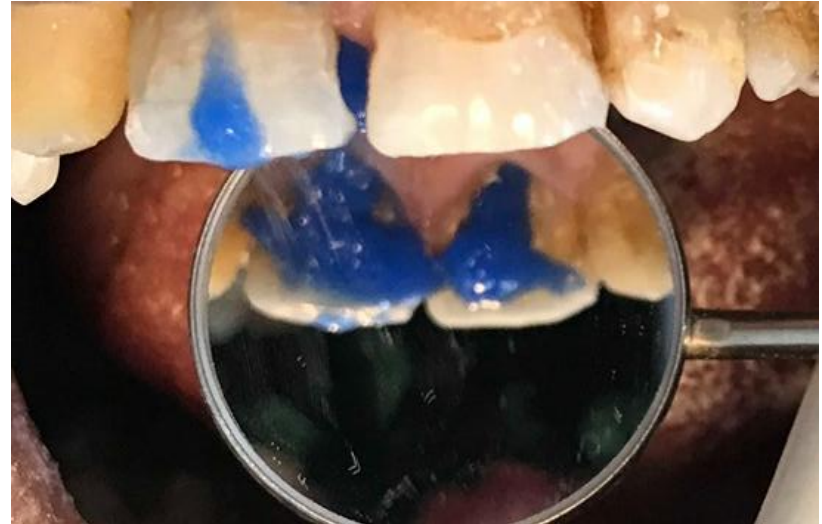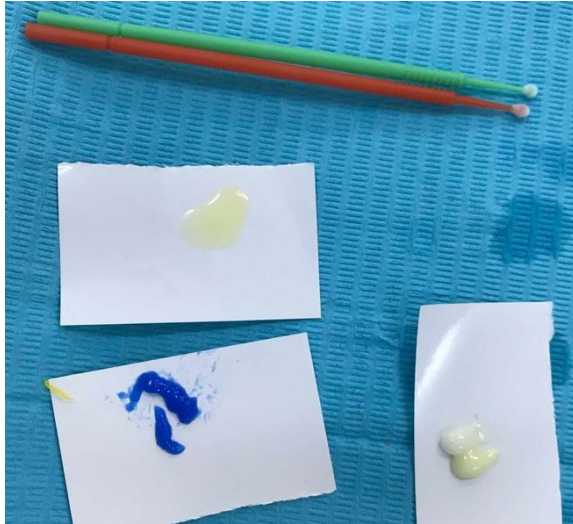
## Post, Core and Crown





- Phase III Therapy  
Restorative Phase

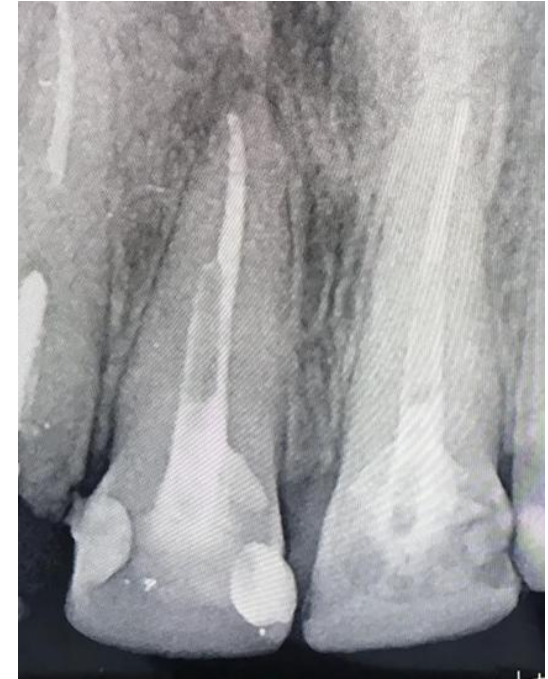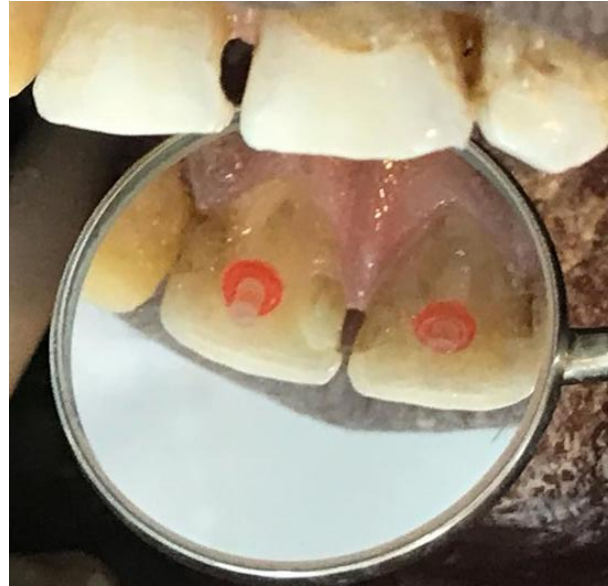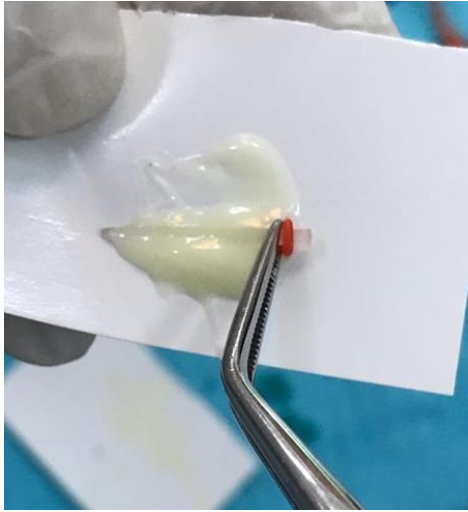
# Post, Core and Crown





- Phase III Therapy  
Restorative Phase

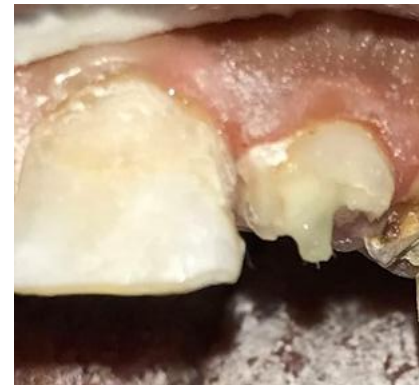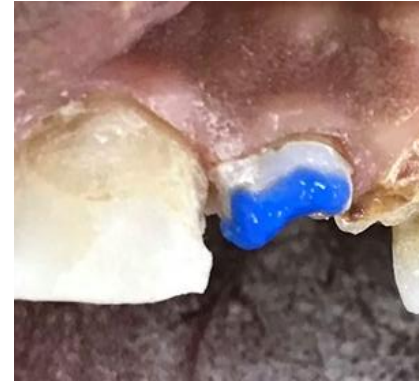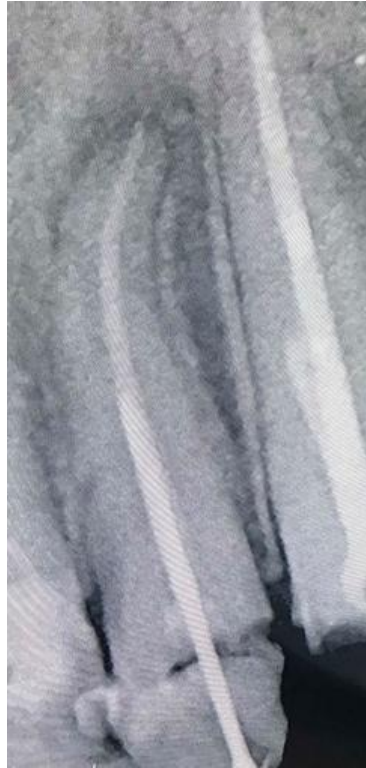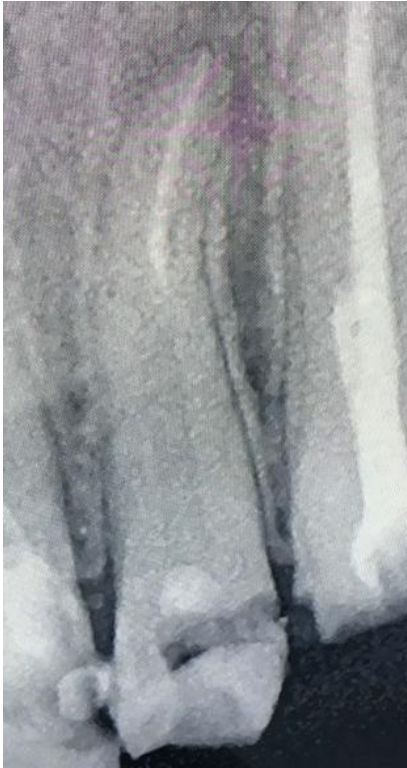# Post, Core and Crown





➤ Phase III Therapy  
Restorative Phase

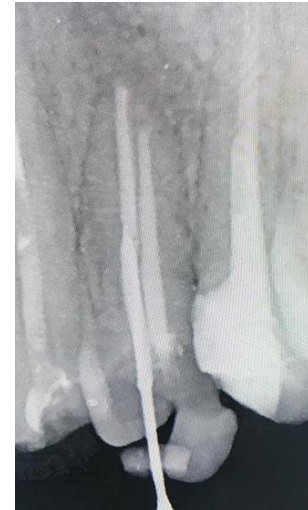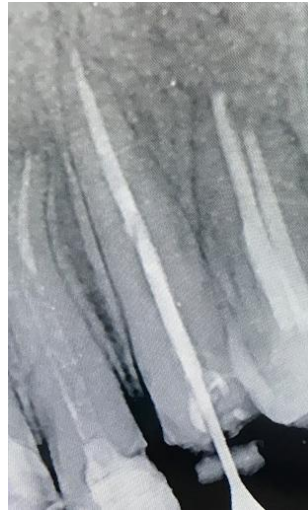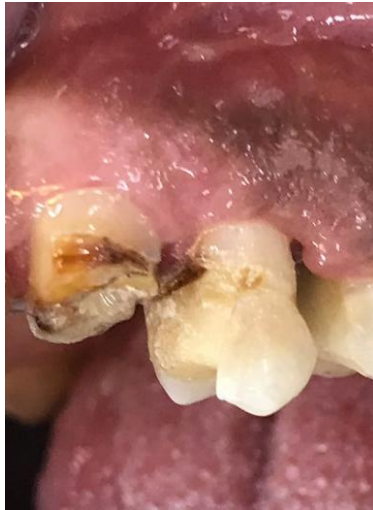# Post, Core and Crown





- Phase III Therapy  
Restorative Phase

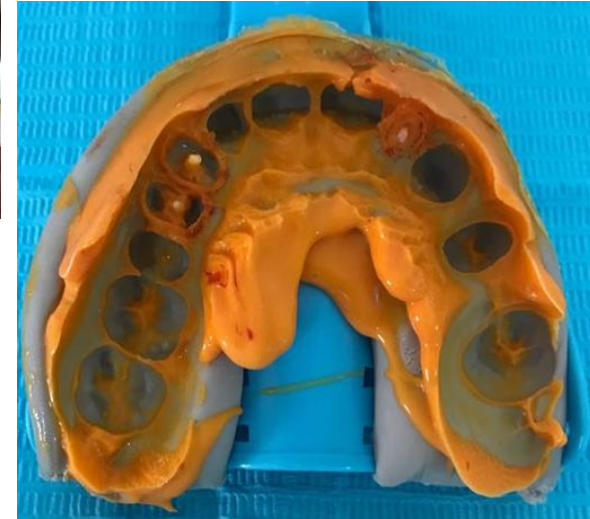
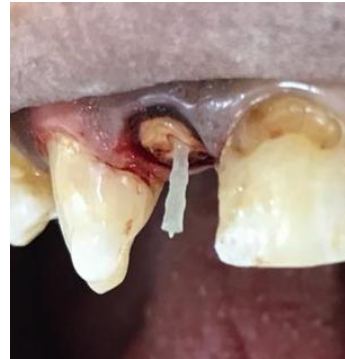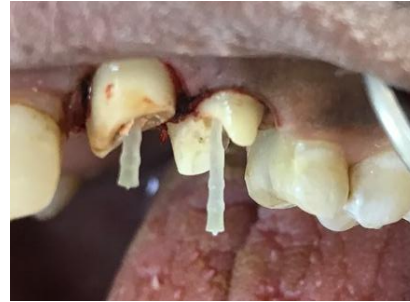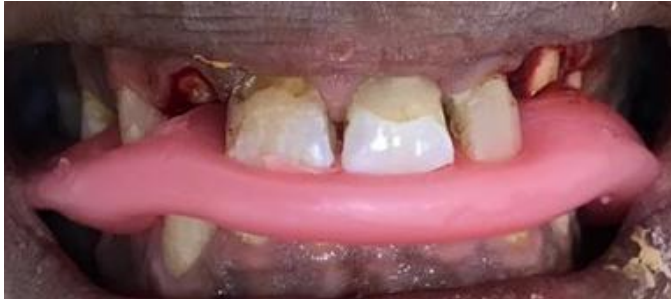# Post, Core and Crown



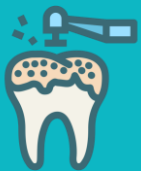

# Post, Core and Crown

Bite Registration

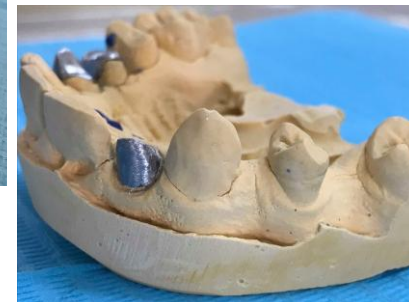
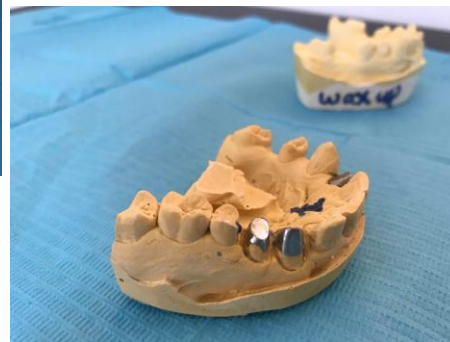
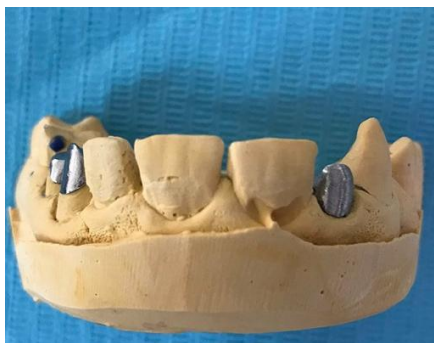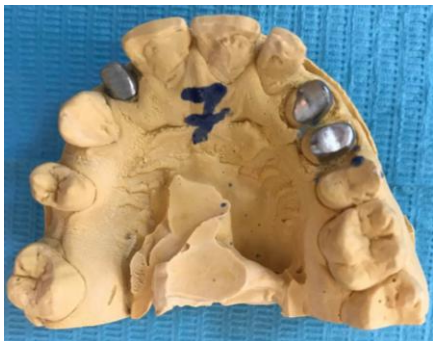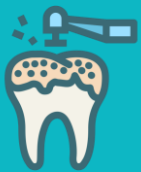Final Impression



# Post, Core and Crown

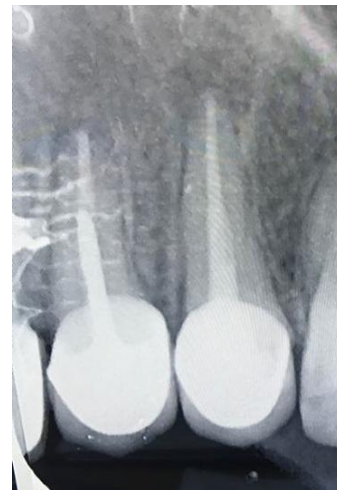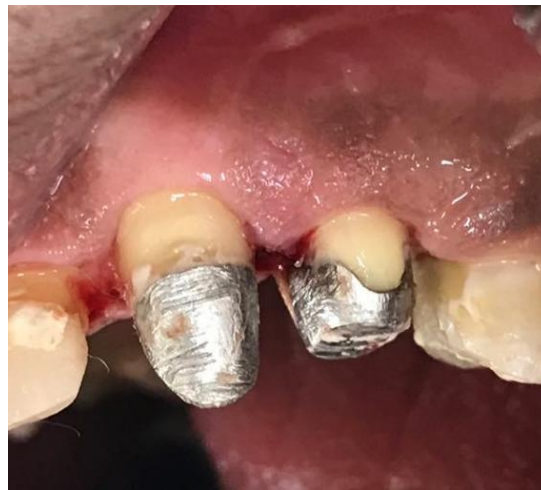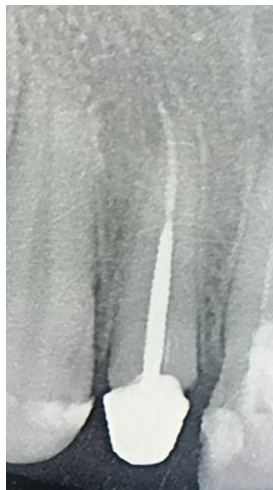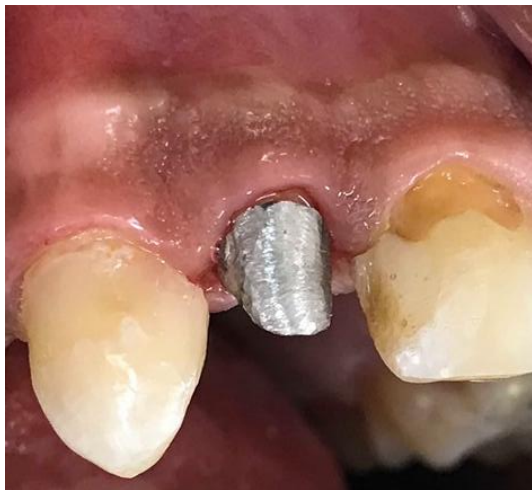- Phase III Therapy  
Restorative Phase





- Phase III Therapy  
Restorative Phase

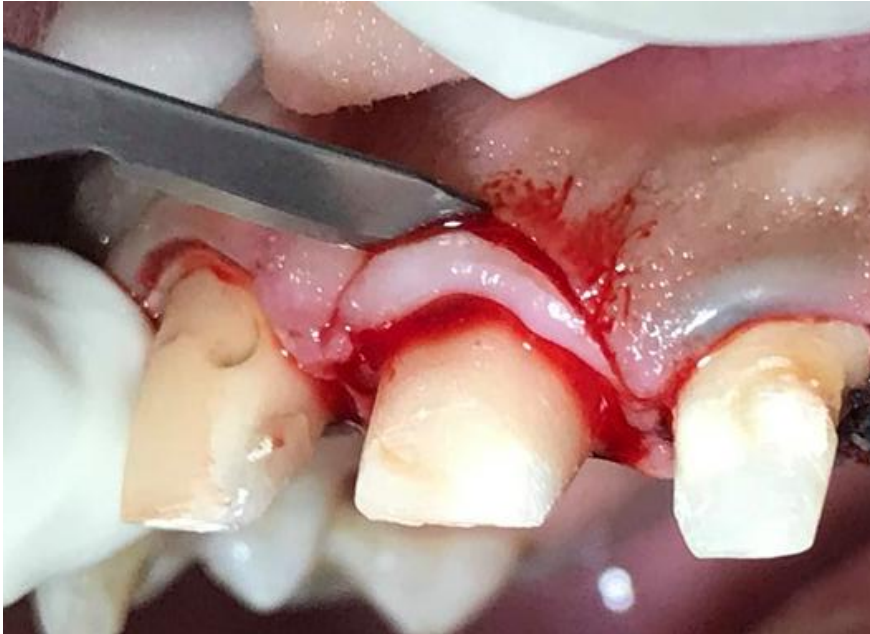## Post, Core and Crown







## Post, Core and Crown

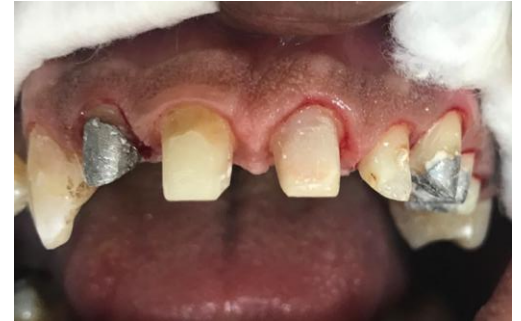
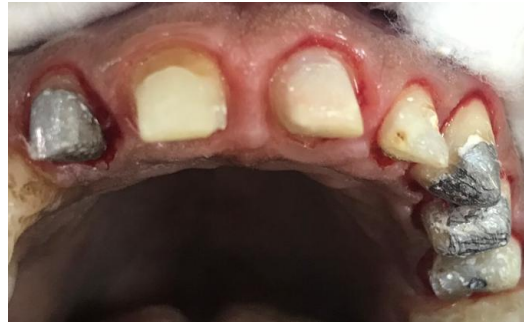
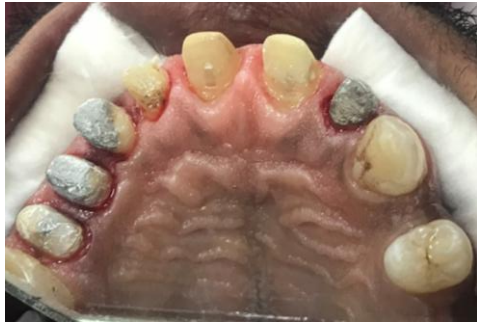- ✓ Gingival margin was found uneven, gingivoplasty was done, and the final impression was postponed after healing.



- Phase III Therapy  
Restorative Phase

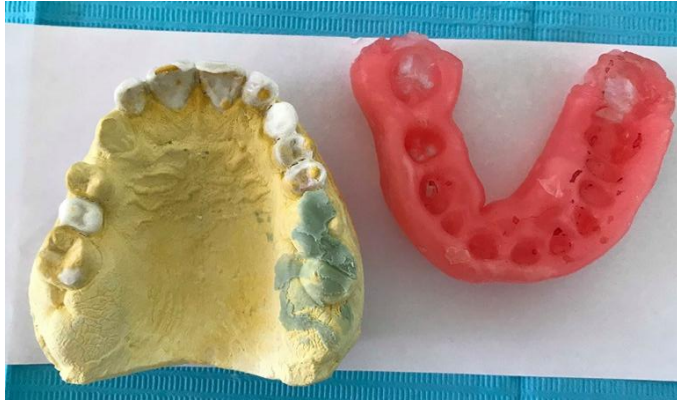# Post, Core and Crown



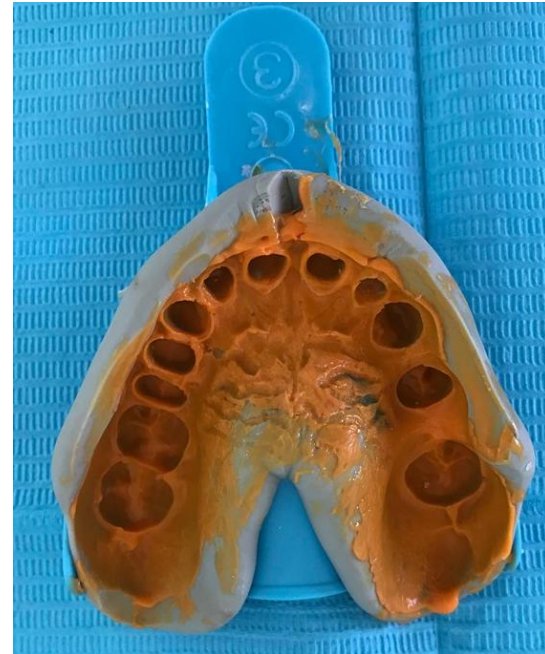

# Post, Core and Crown

Bite Registration



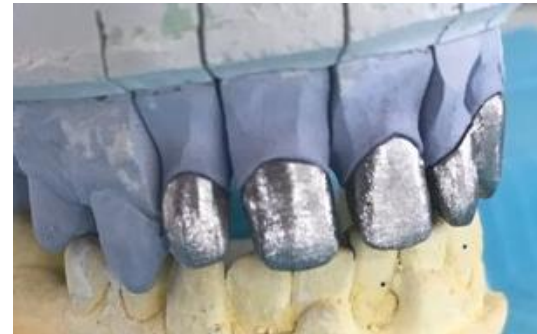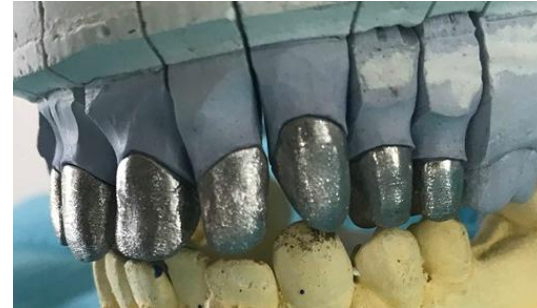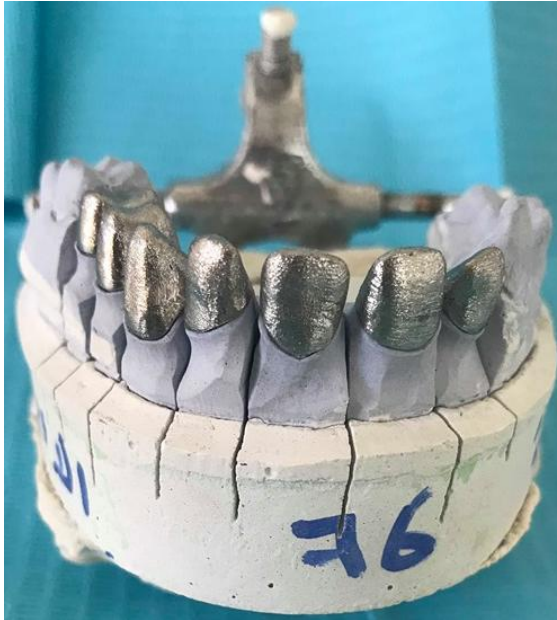Final Impression





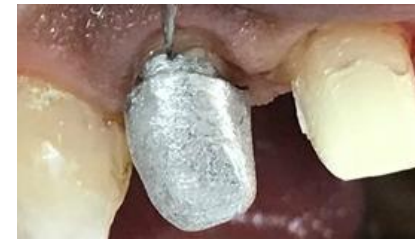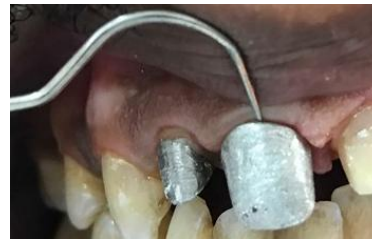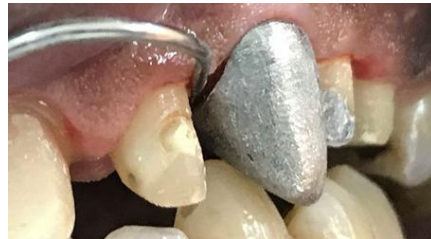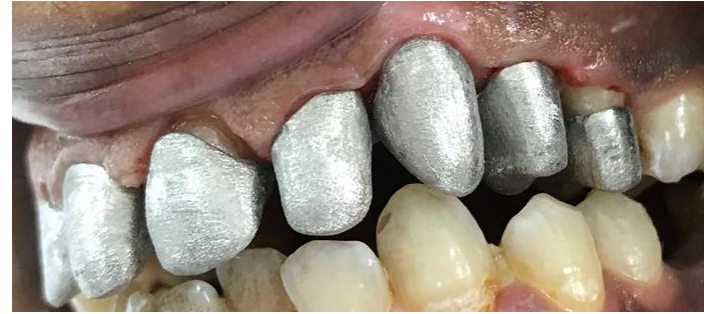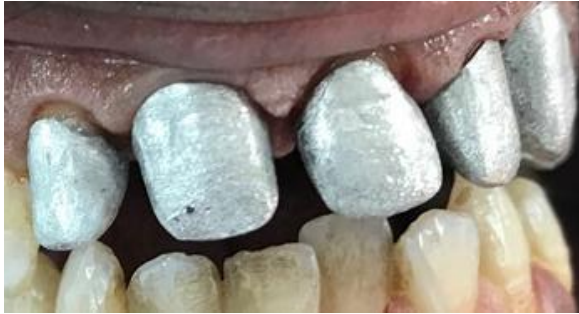# Post, Core and Crown

Metal Try-in “7 units”





# Post, Core and Crown

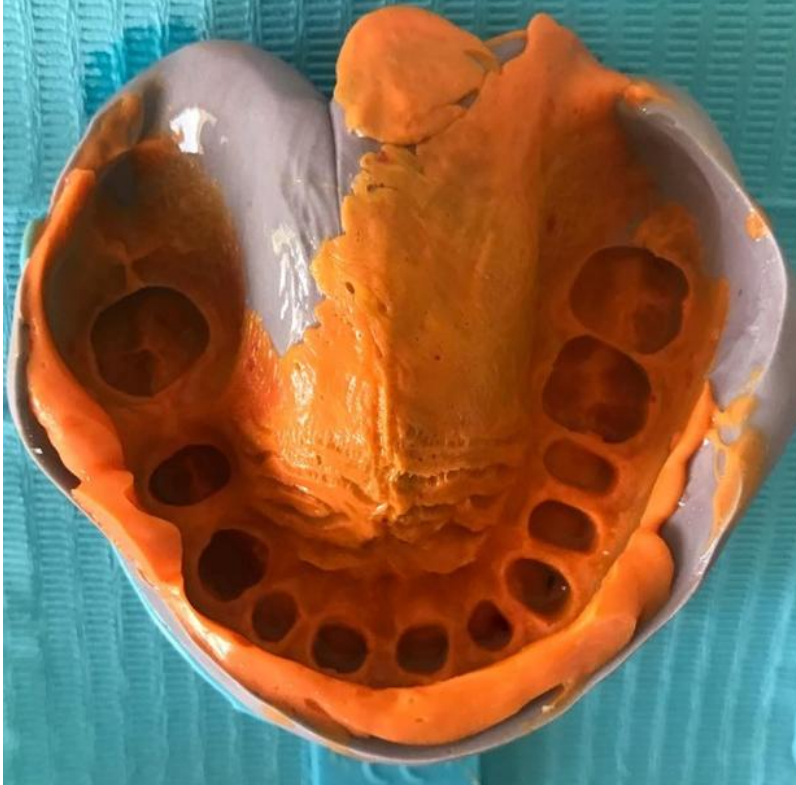

Required  
a remake.



- Phase III Therapy  
Restorative Phase

## Post, Core and Crown



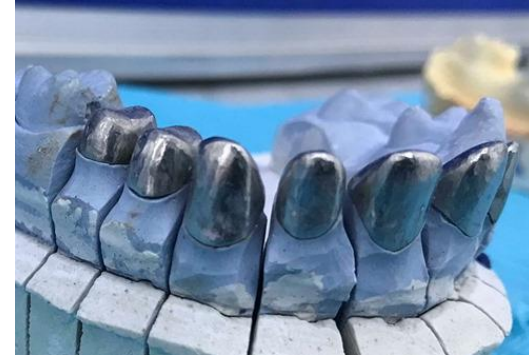
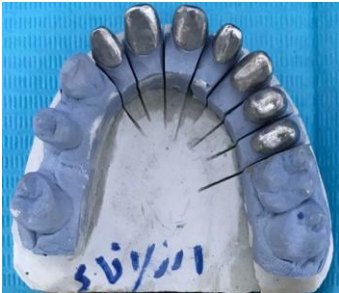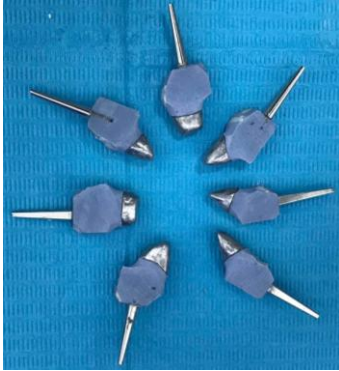
A Second Final  
Impression



- Phase III Therapy  
Restorative Phase

# Post, Core and Crown

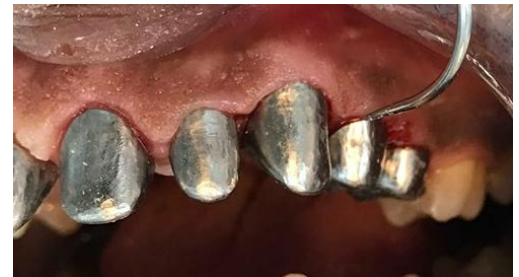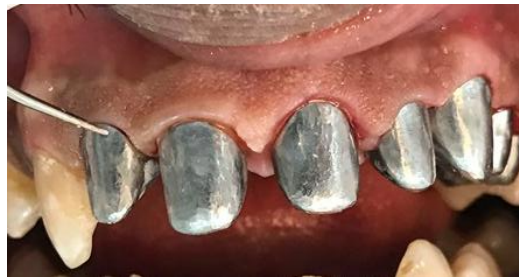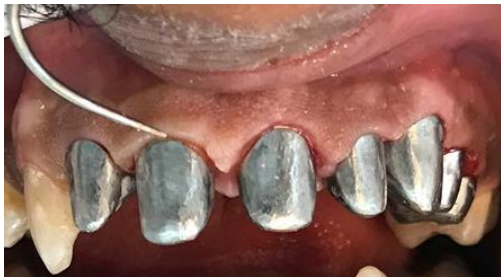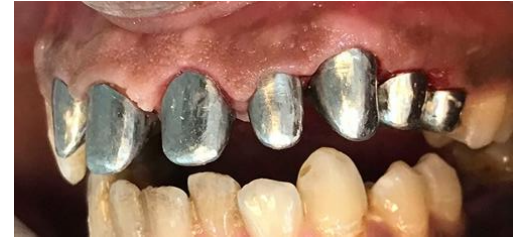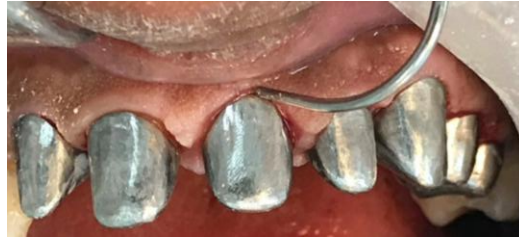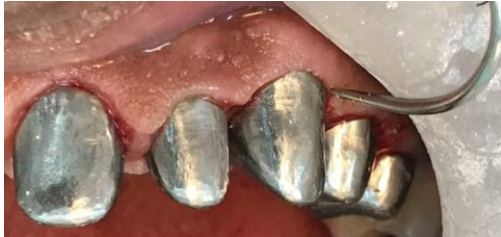Second Metal Try-in “7 units”





- Phase III Therapy  
Restorative Phase

# Post, Core and Crown



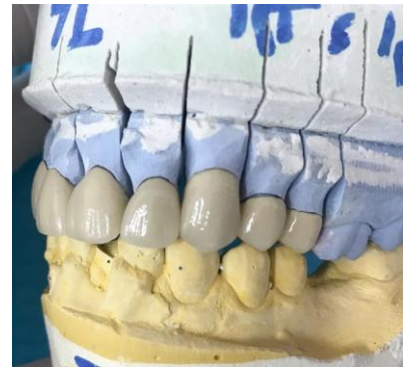
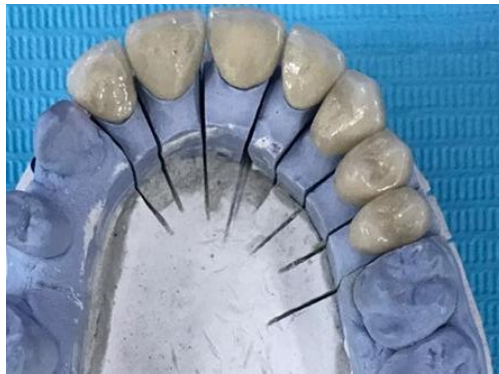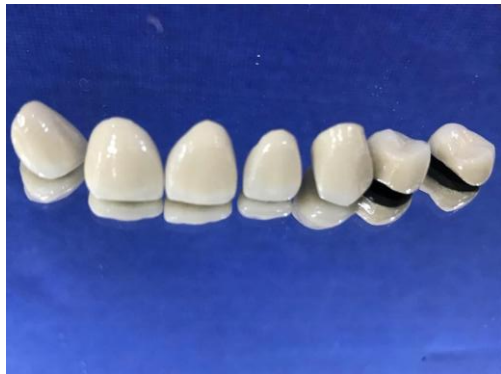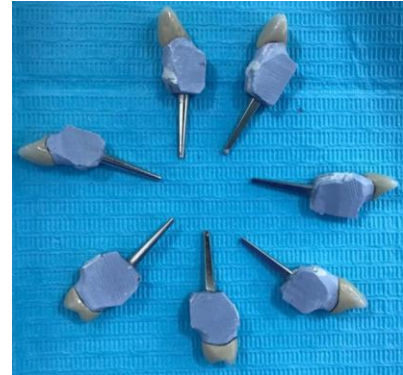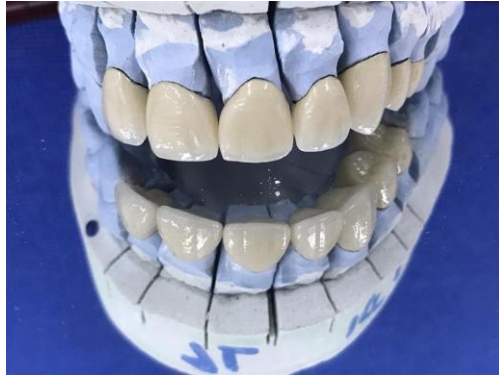✓ **Selected shade : A2**





➤ Phase III Therapy  
Restorative Phase

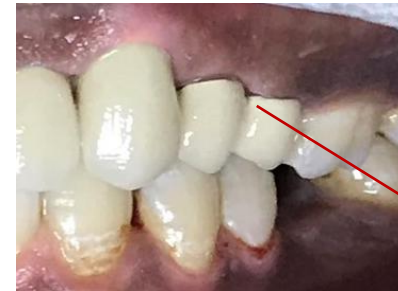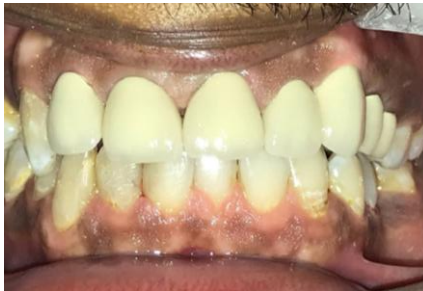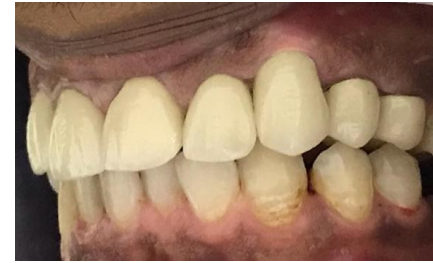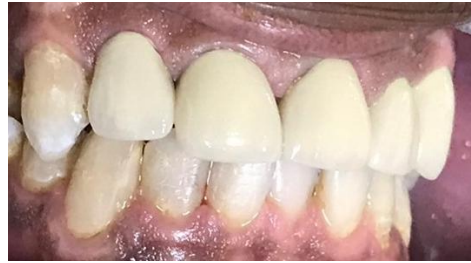# Post, Core and Crown





- Phase III Therapy  
Restorative Phase

# Post, Core and Crown



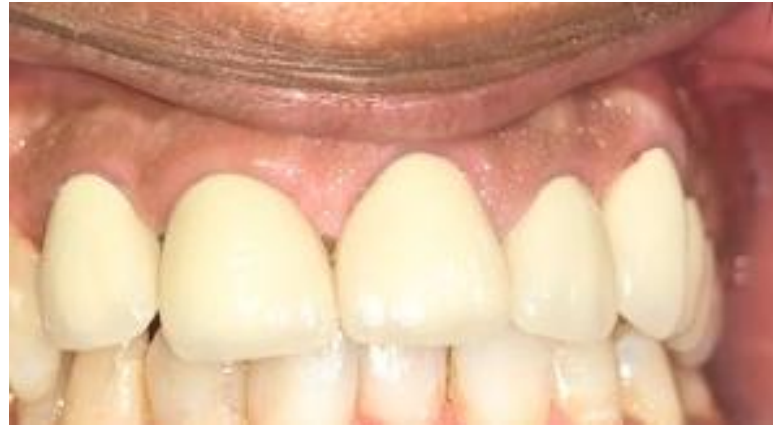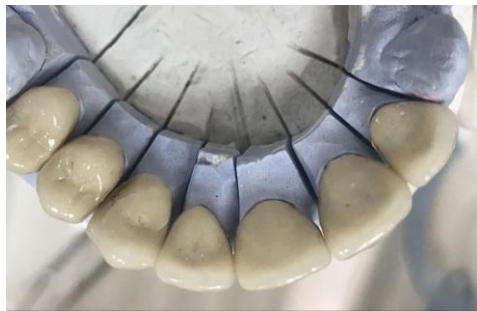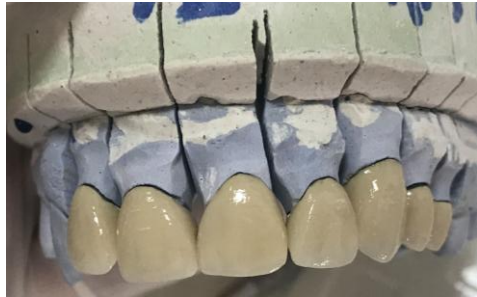**Short  
margin**



- Phase III Therapy  
Restorative Phase

# Post, Core and Crown

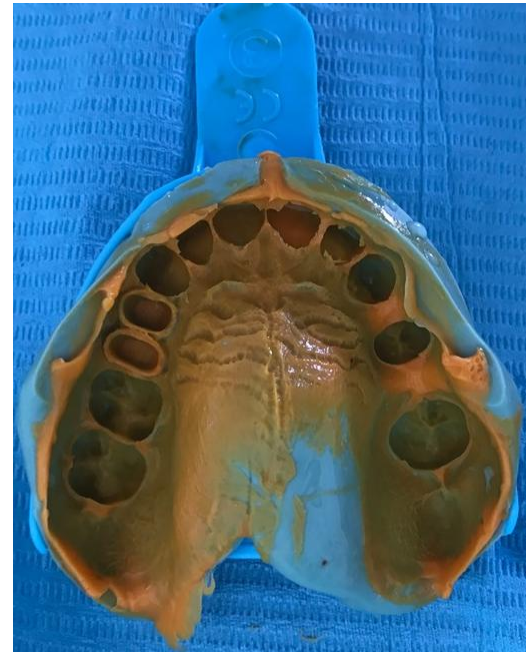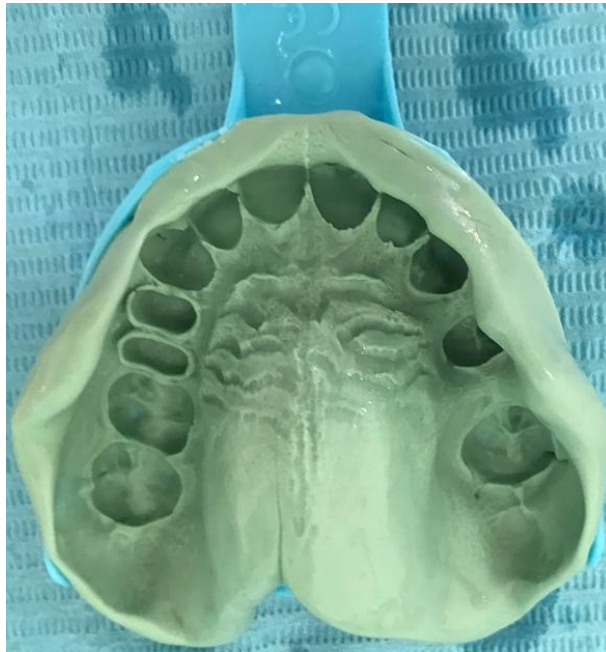## Insertion





# Post, Core and Crown

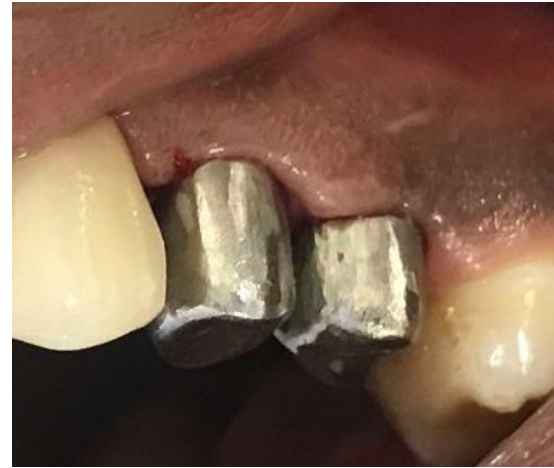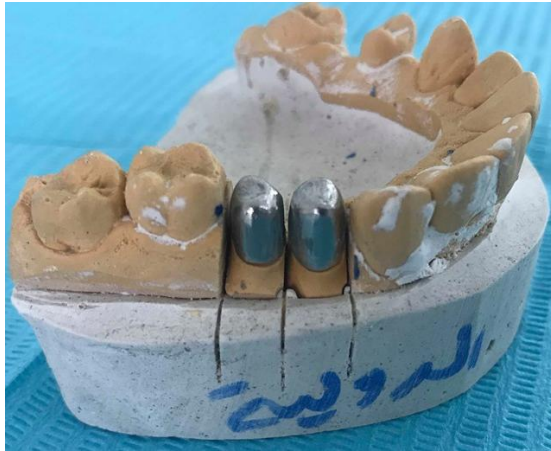## Final Impression for 24 - 25





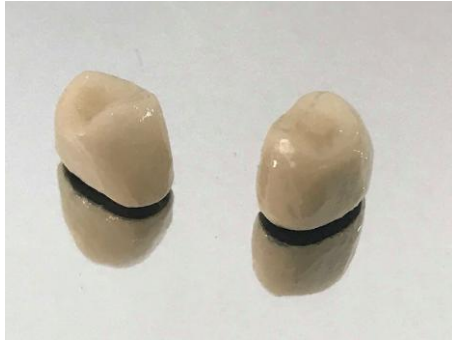# Post, Core and Crown

Metal Try-in for 24 - 25

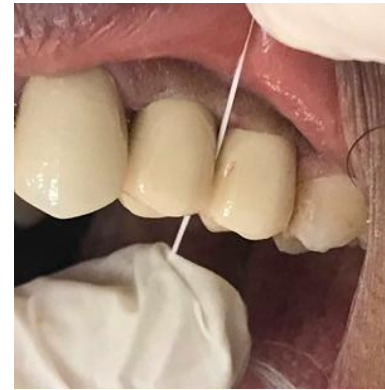
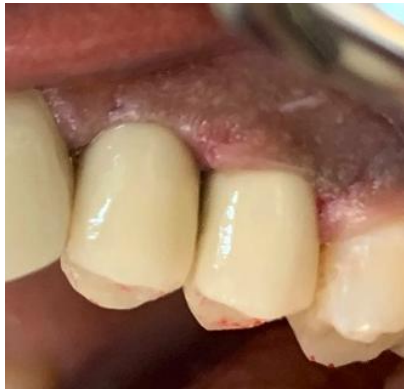
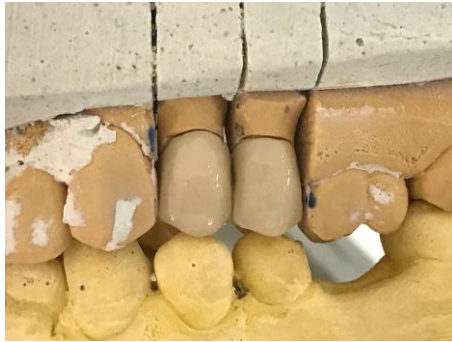

# Post, Core and Crown



Try-in for 24 - 25

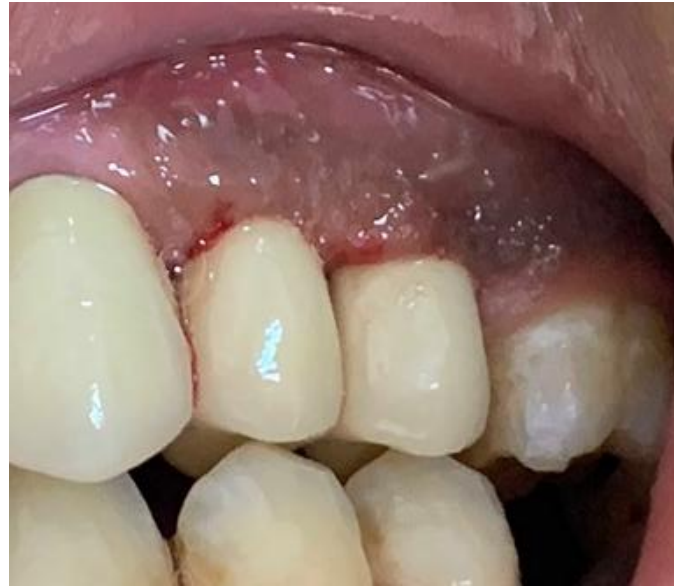



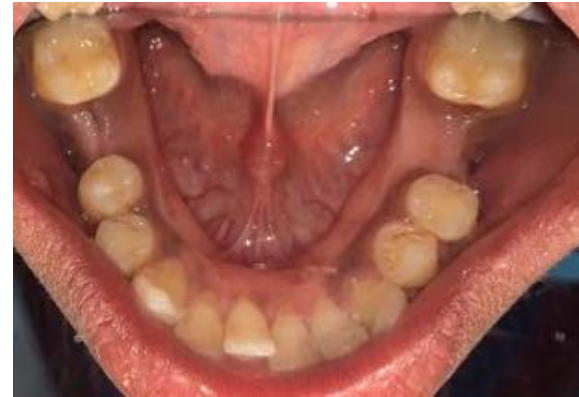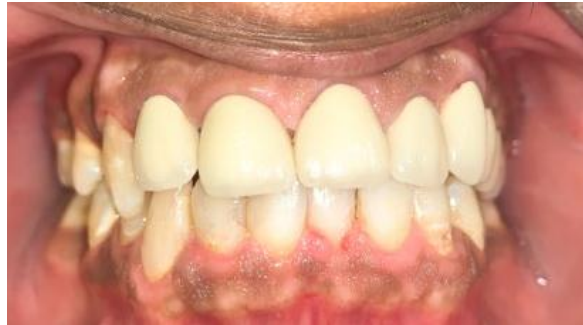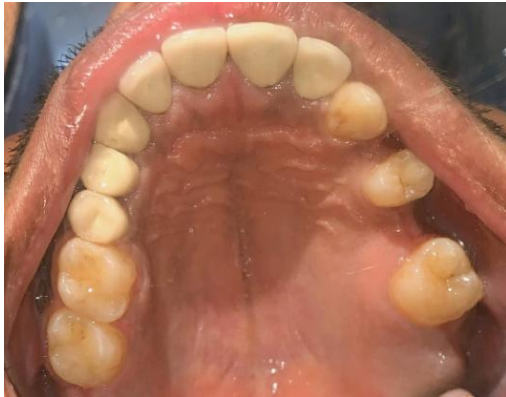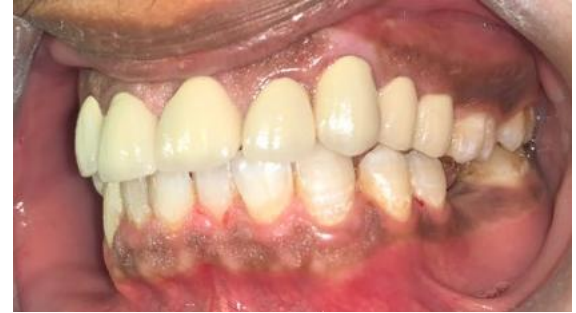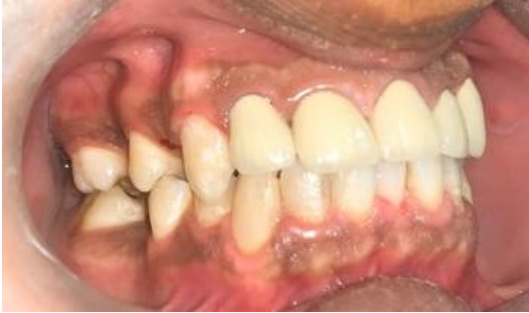- Phase III Therapy  
Restorative Phase

## Post, Core and Crown

Insertion 24 - 25

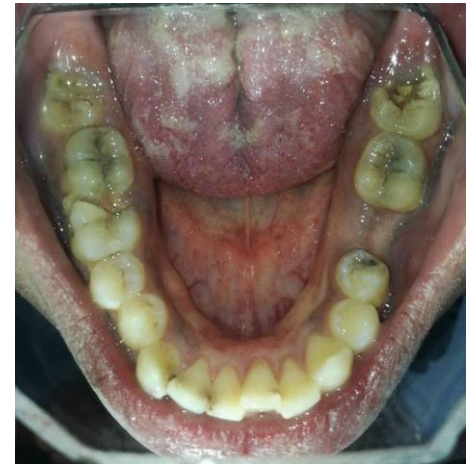
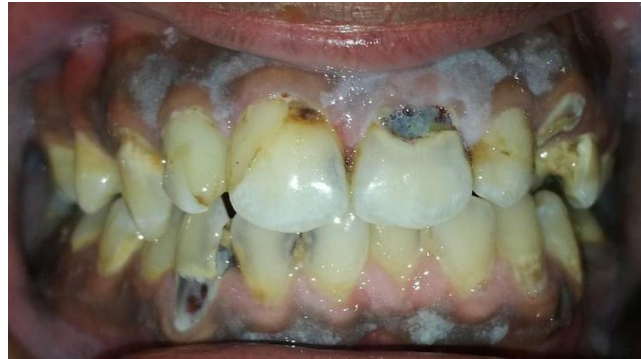
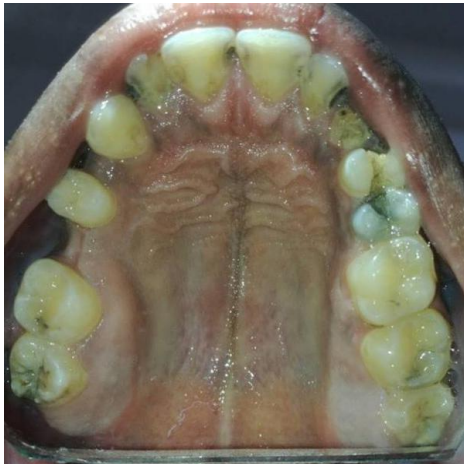
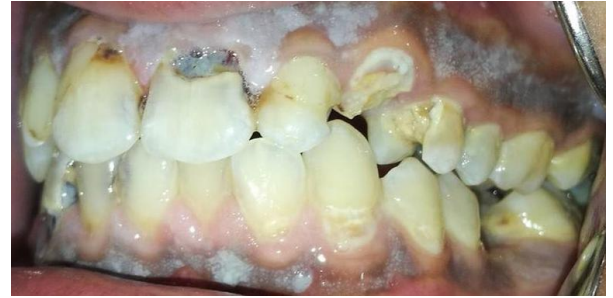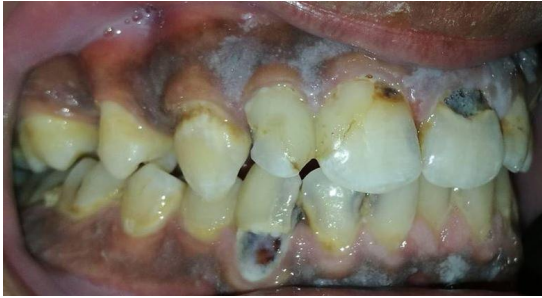# Post-operative Photographs


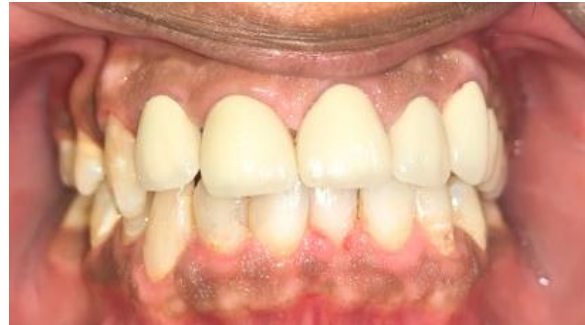


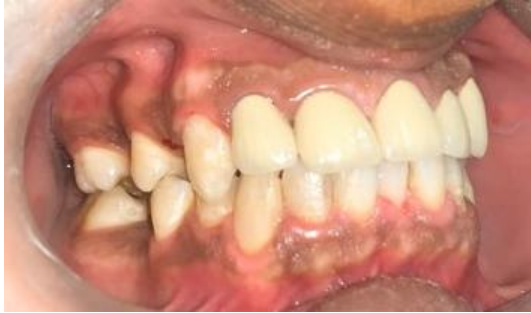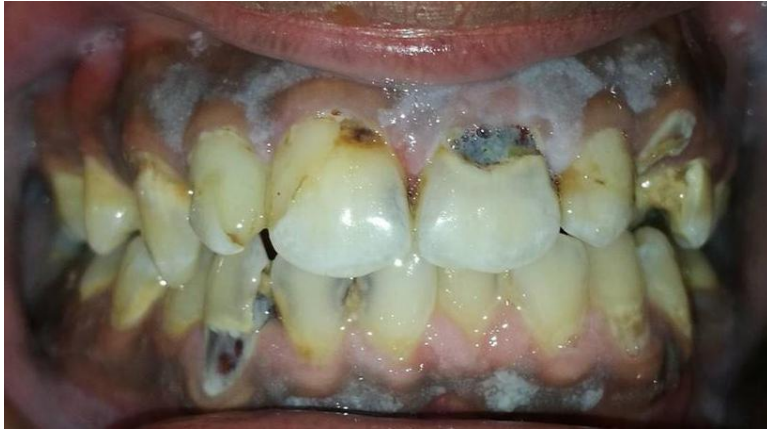# Before



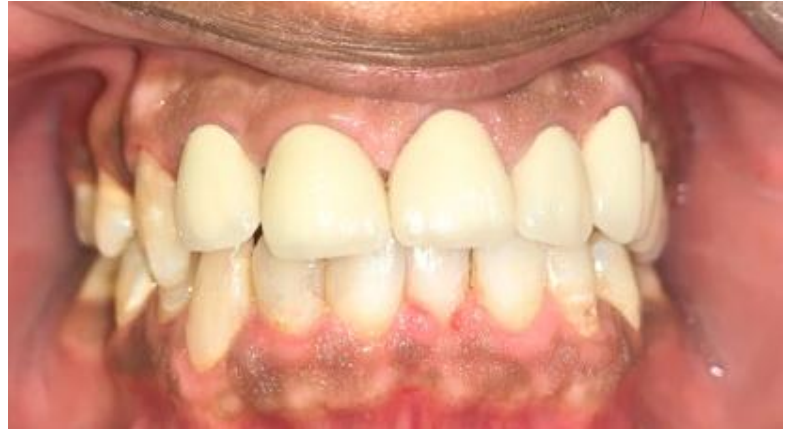# After



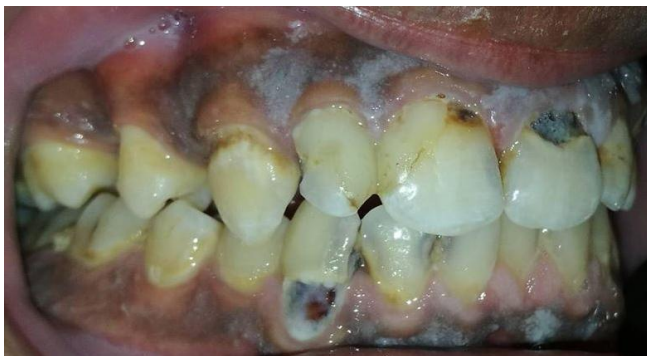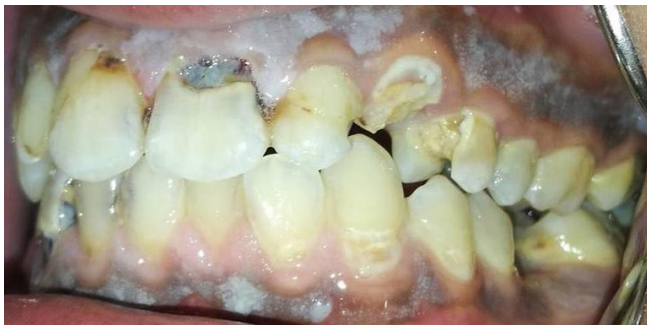Before



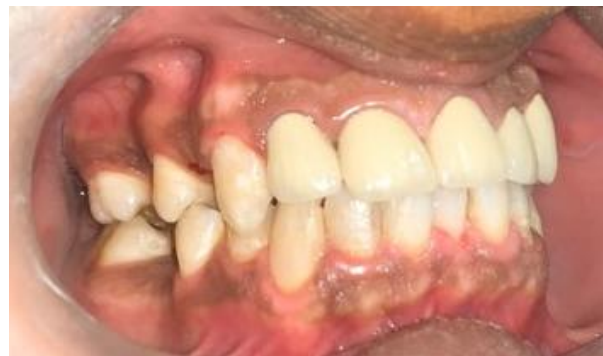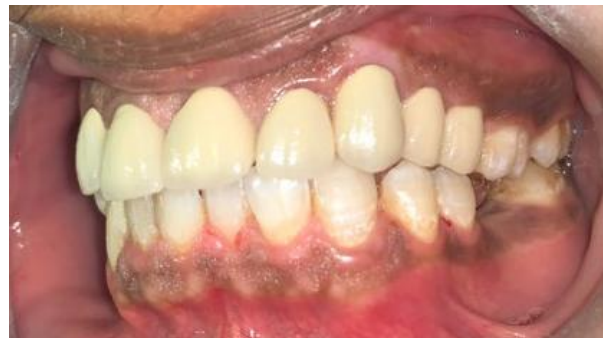After



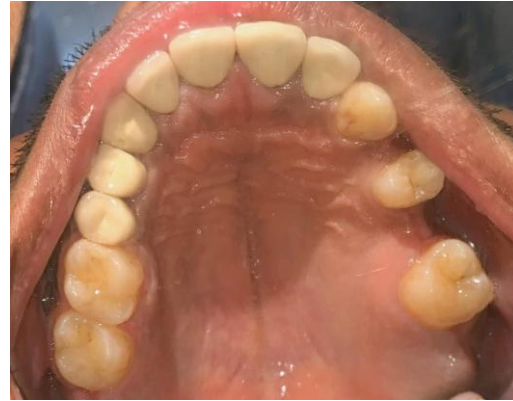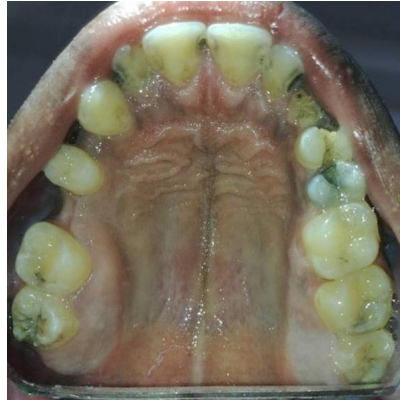Before



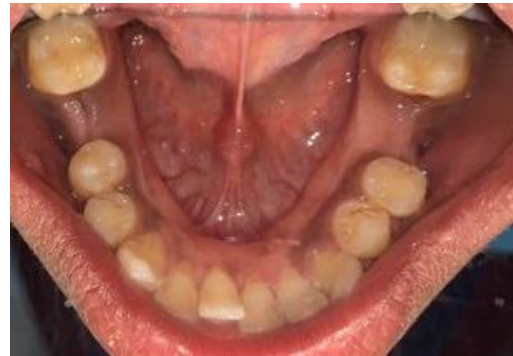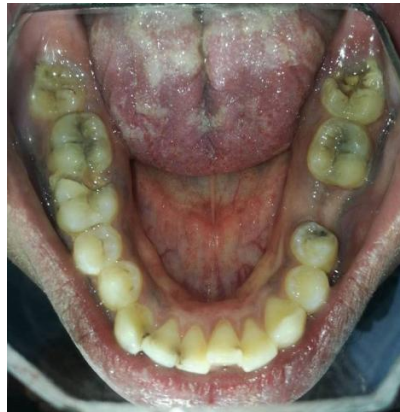After



Before



After





Thank You