



LIBYAN INTERNATIONAL MEDICAL UNIVERSITY

Comprehensive treatment presentation

Presented by:

Fatma Jamal ELbshari

No. 780

PATIENT INFORMATION

- **Pt name:** M.A.A
- **D.O.B:** 25\4\1984
- **Gender:** Male
- **Nationality:** Libyan
- **Occupation:** Accountant
- **Address :** almajory

Chief complaint and history of chief complaint :

□ C.C :

Patient came to restore broken restoration on upper right tooth. It was broken since one month.

□ H.C:

The tooth was RCT treated since one year .and filled with composite restoration which was broken during eating since one month .

No history of pain or swelling .

No other signs or symptoms



- **Medical history** : N.O.S

- **Drug history** : N.O.S

- **Allergic history** : N.O.S

- **Family history** : Mother is hypertensive and diabetic .

DENTAL HISTORY

- History of **extraction** ,with no complication more than one year ago.
- **RCT** with no complication since one year .

Oral Hygiene Practice

- **Brushing** : regularly twice a day .
- **Brushing method**: Horizontal
- **Any other orophysiotherapeutic Aids**: No
- **Kind of Dentifrice used**: crest

SOCIAL HISTORY

- Single
- smoker (**10 cigarette /day**)for **18 years**
- No alcoholic, or drug abuser.
- No hereditary diseases running in the family.



CLINICAL EXAMINATION

EXTRAORAL EXAMINATION

- Pt. is fit & healthy, with symmetrical face , no palpable neither tender **L.N.**
- **TMJ** examination reveals no clicking, crepitations, limitation or deviation of mouth opening, with no masticatory muscles tenderness.
- The Lips are **competent.**

Dental chart

8	7	6	5	4	3	2	1	1	2	3	4	5	6	7	8
M	M	D	RC		D	D						D	M		M
M															M

DMFT 7

O.H.I 2,7 FAIR

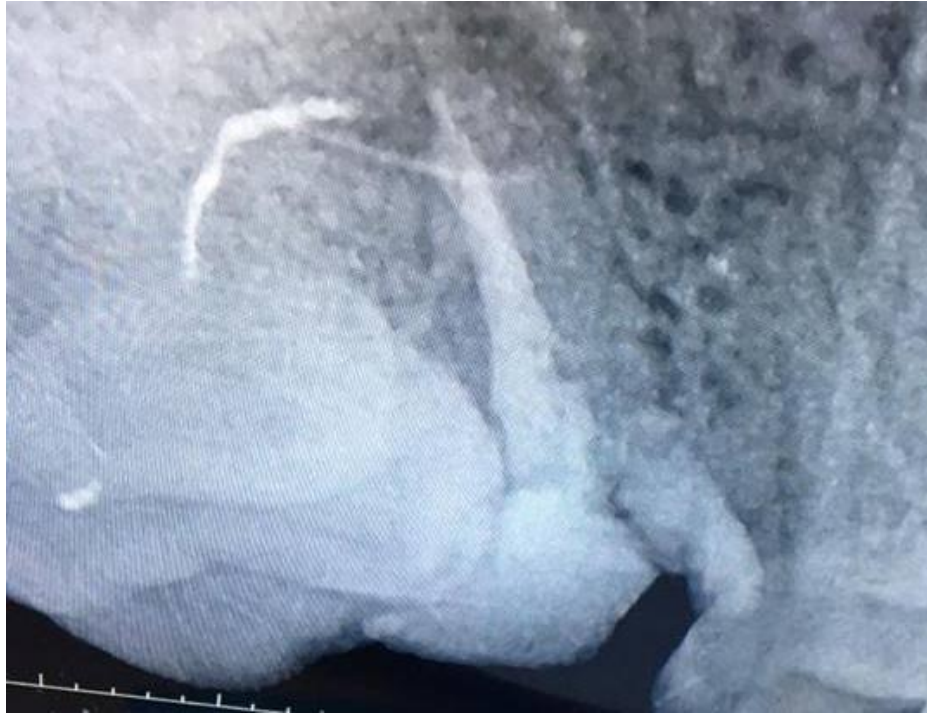
Periodontal health

- **Normal** collar pink gingival colour ,with scalloped margin and blunt end **IDP**.
- **Normal** stippling is present .
- **P.D** within normal **except** UL7 which is 4mm calibrated by universal probe.
- **A.L** related to LR1,2,3
- Supra and sub gingival calculus related to lower anterior quadrant .
- **Recession** related to LR1,2,3
- No mobility
- **Positive** bleeding on probing
- No exudates

Provisional diagnosis

- According to the offending tooth **UR5** ,which is the **C.C** of the P.T and after clinical examinations that reveals no tenderness neither swelling, the provisional diagnosis will be fractured composite restoration .

Investigations – Intraoral periapical radiograph

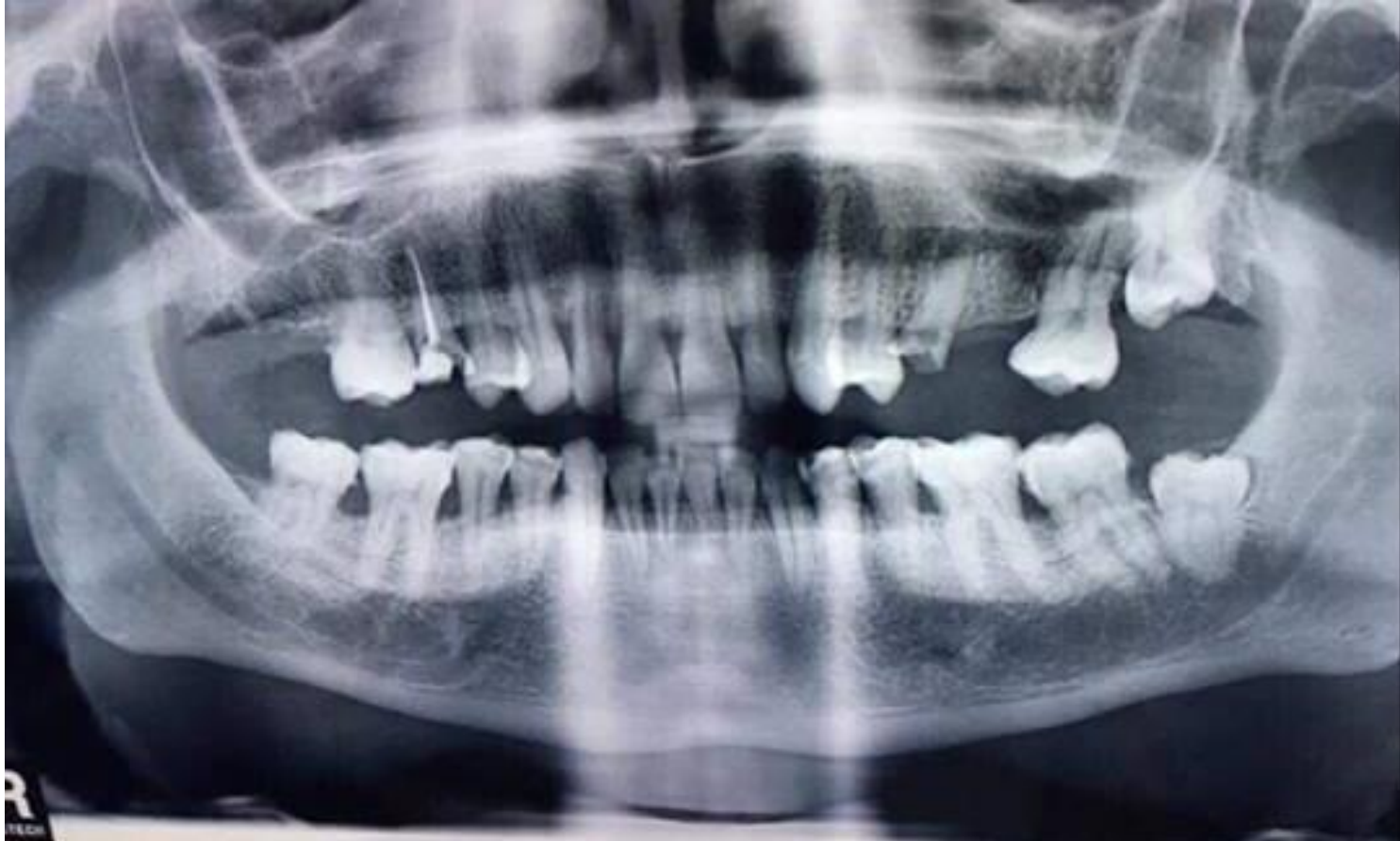

Final diagnosis & findings

- fractured composite restoration related to the RC treated **UR5** .

- **Findings :**
 1. Dental carious teeth UR2,3,6 –UL5
 2. Missing teeth UR7,UL6
 3. Missing all 3rd molars
 4. Generalized mild to moderate chronic periodontitis

Ortho panoramic radiograph



Treatment options and **ttt** plan selected

- Phase I therapy :
- -p.t motivation & education
- O.H.I
- - scaling & root plannig
- -evaluation of phase I therapy



- **Phase II :**

- Extraction of UL5

But the p.t **refused** the ttt plan , he won't to extract more teeth , so together decided to try to **preserve** the tooth , and So phase II was cancelled .



□ **Phase III :**

□ Restoration of UR**2,3,6**

□ RCT FOR UL**5** and **custom made** post & core & crown

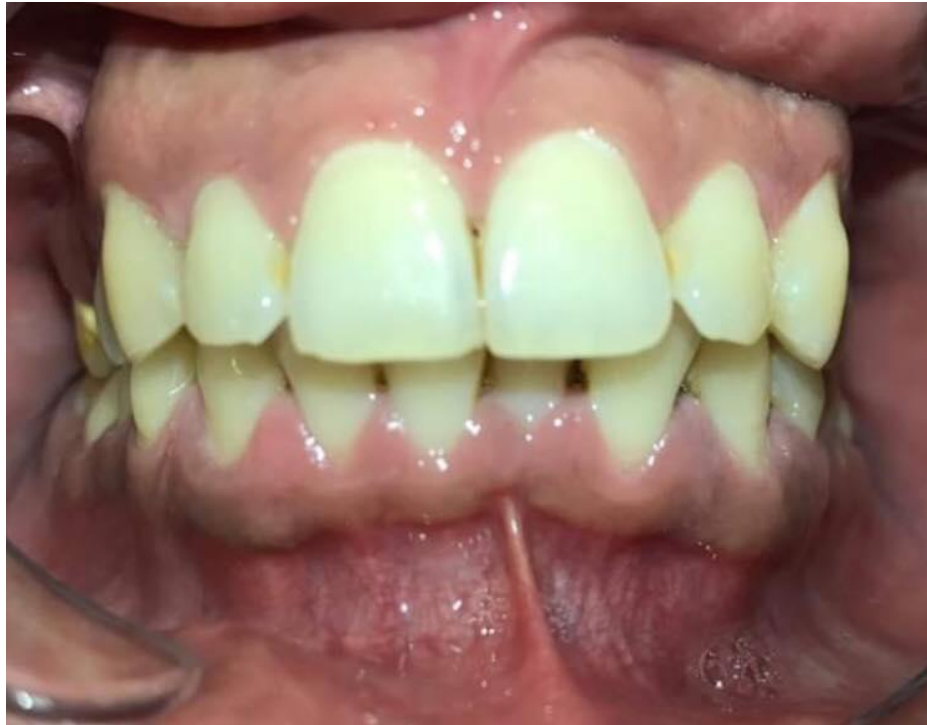□ RCT Retreatment of UR**5** and **custom made** post & core & crown



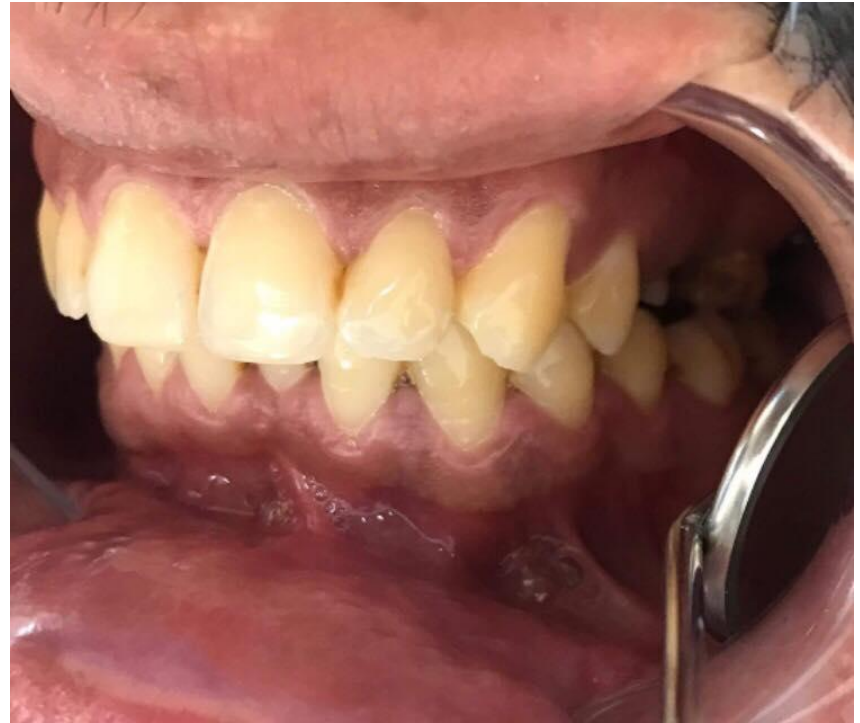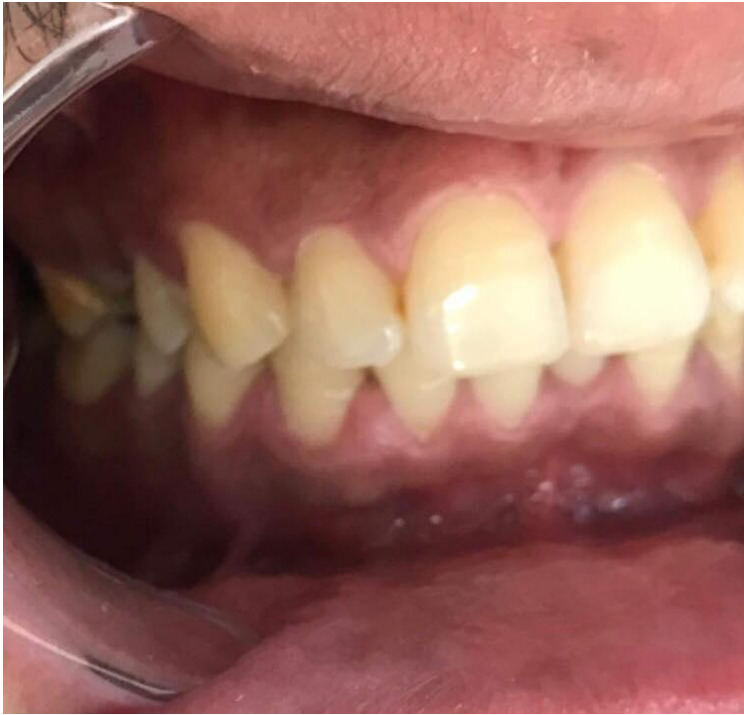- **Phase IV :**

- Maintenance after 6 months .

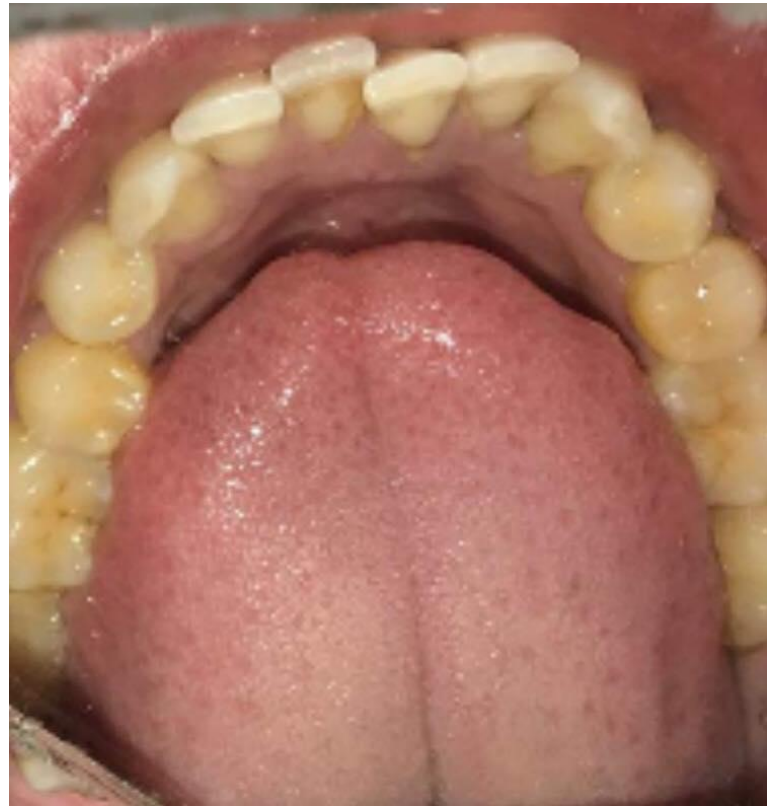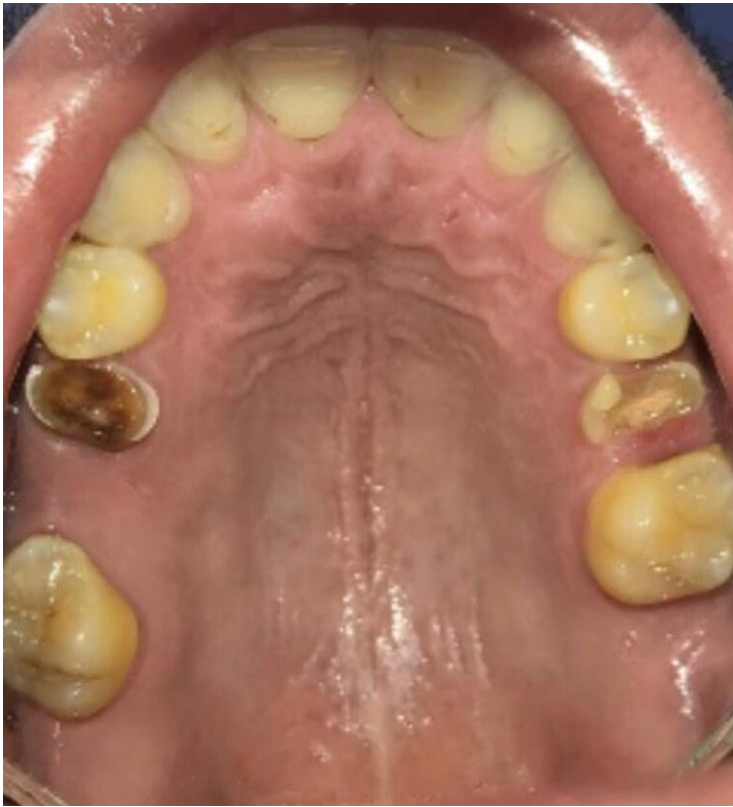Intra oral photographs



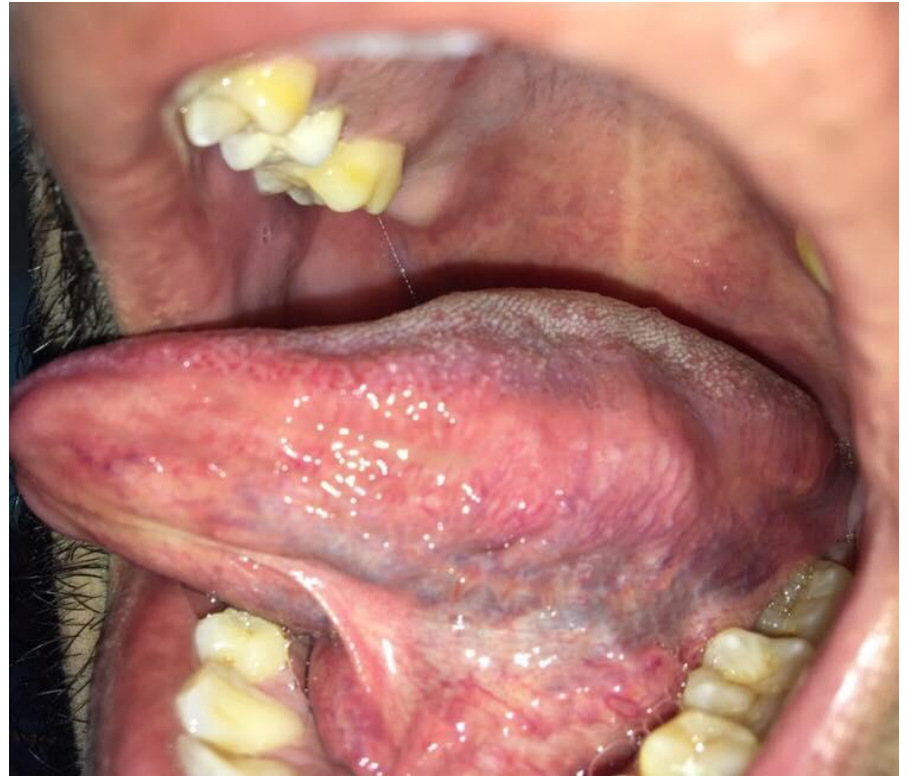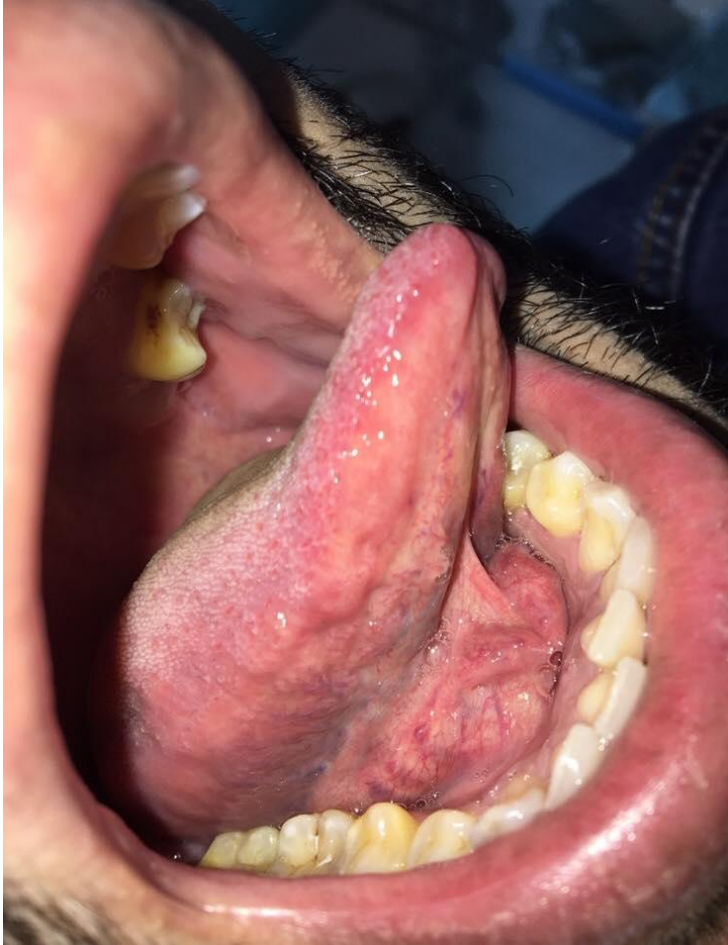Intra oral photographs



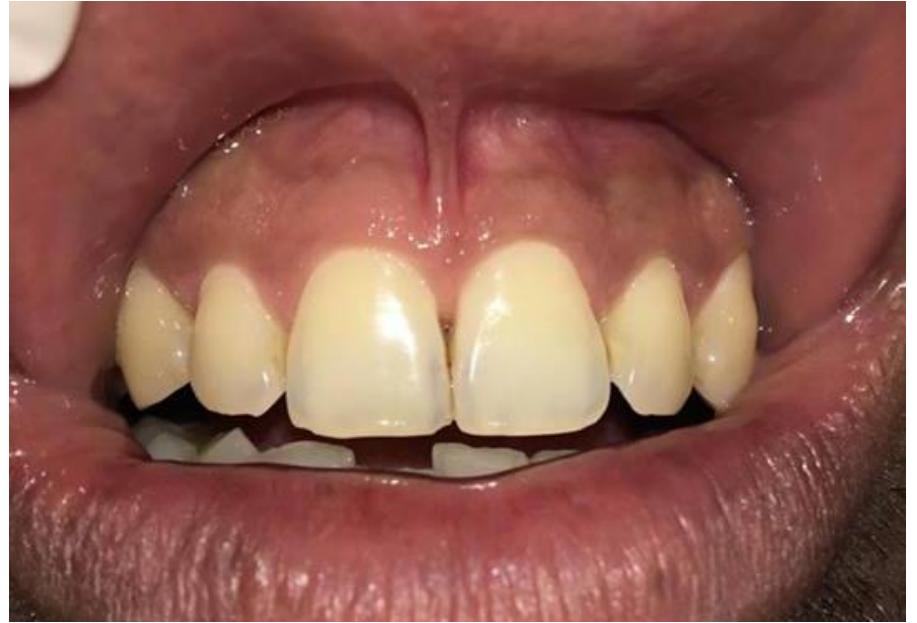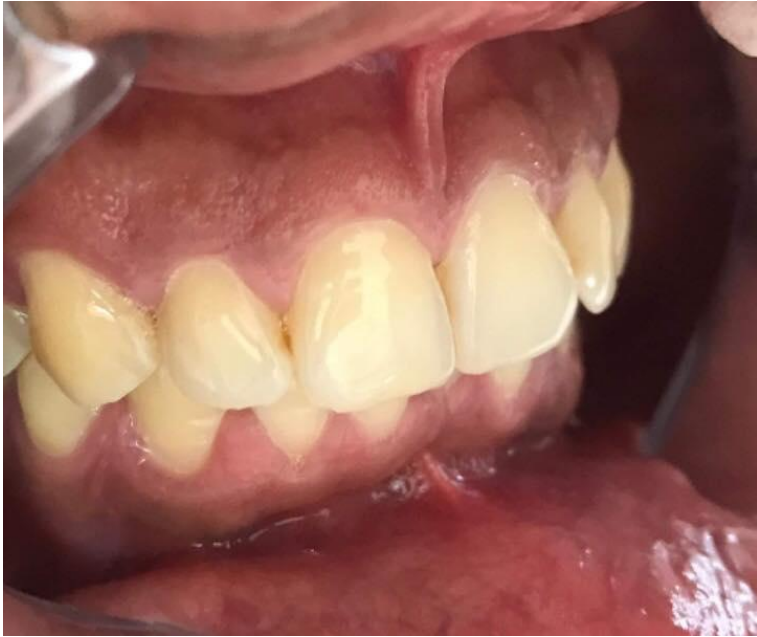Intra oral photographs



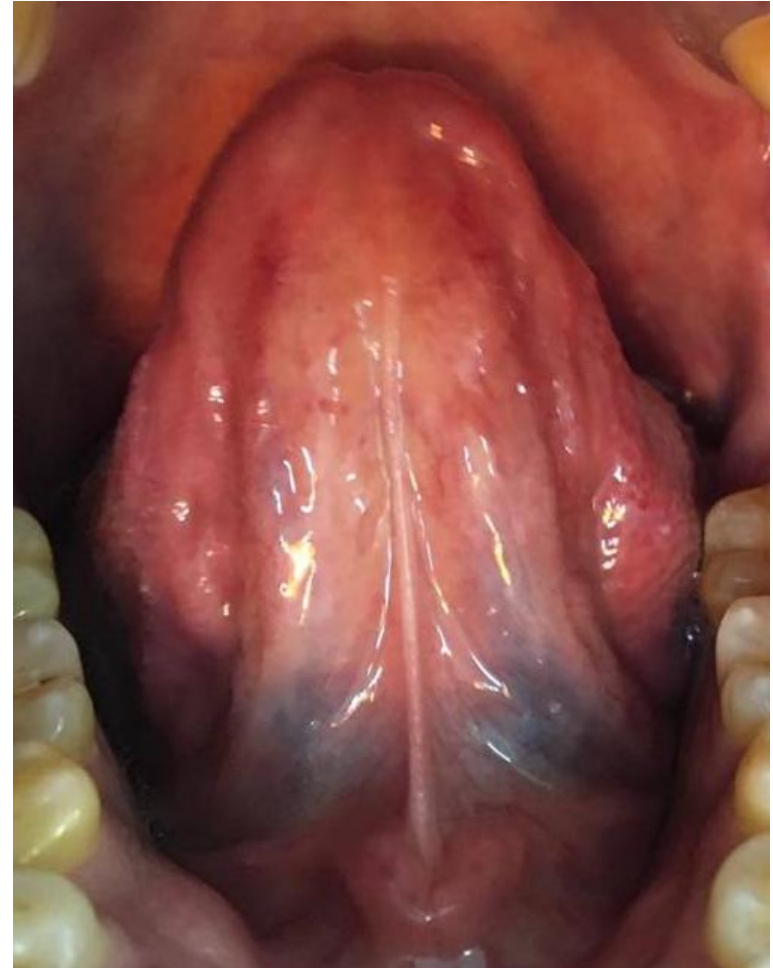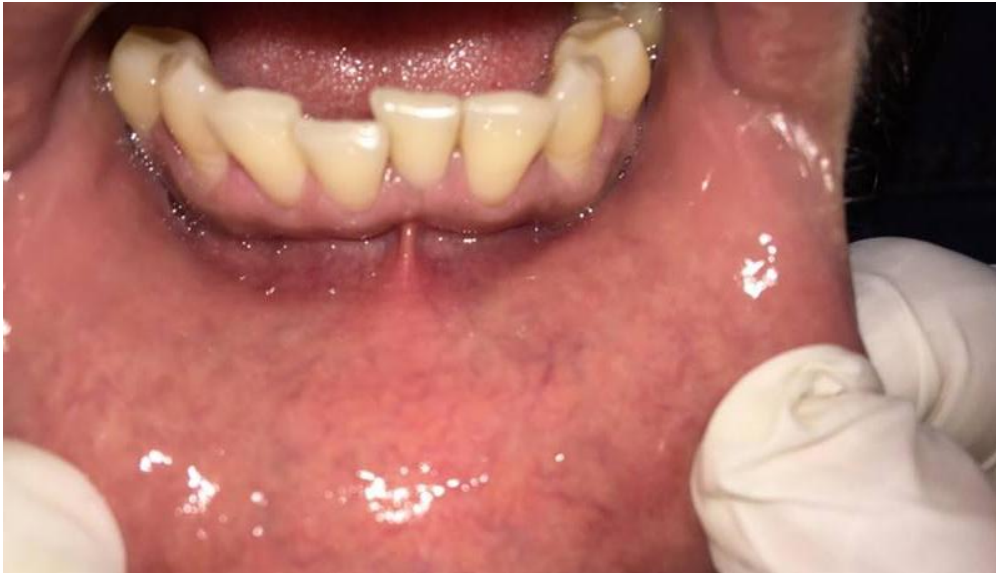Intra oral photographs



Intra oral photographs



Intra oral photographs

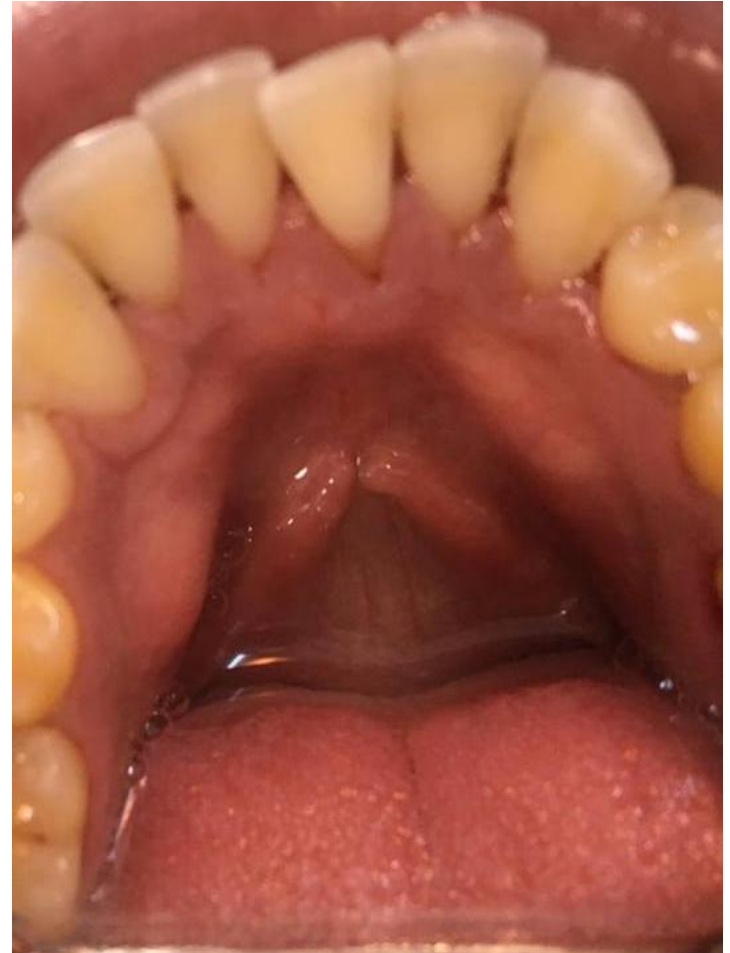
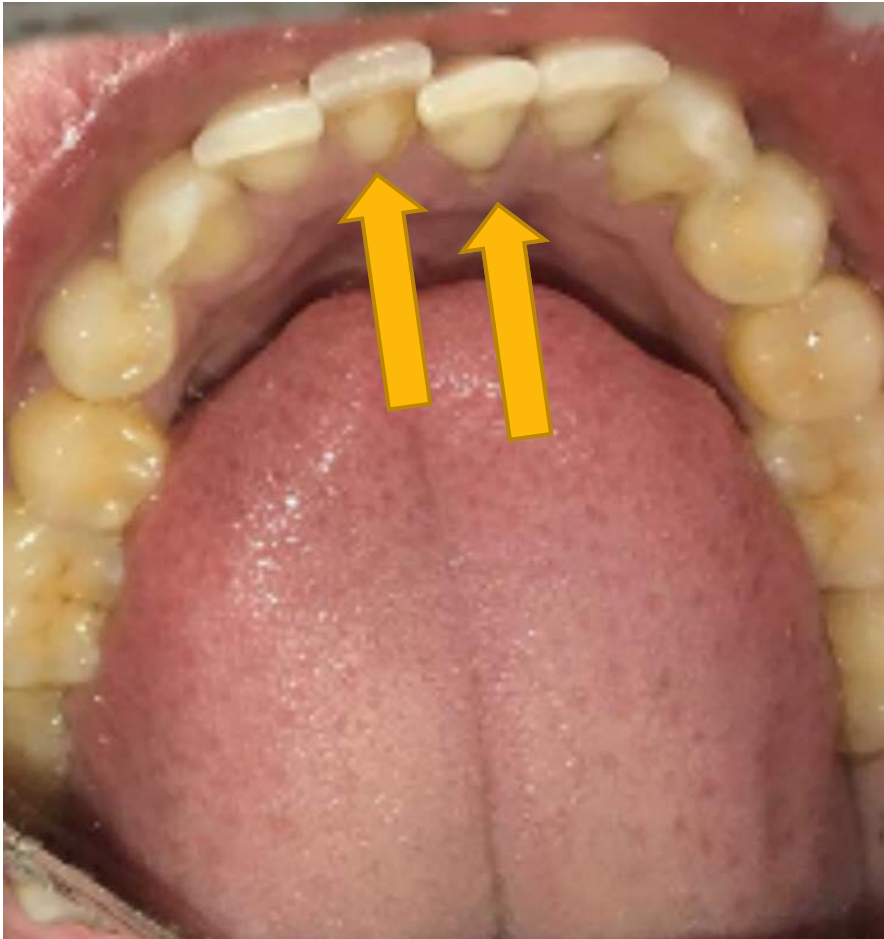
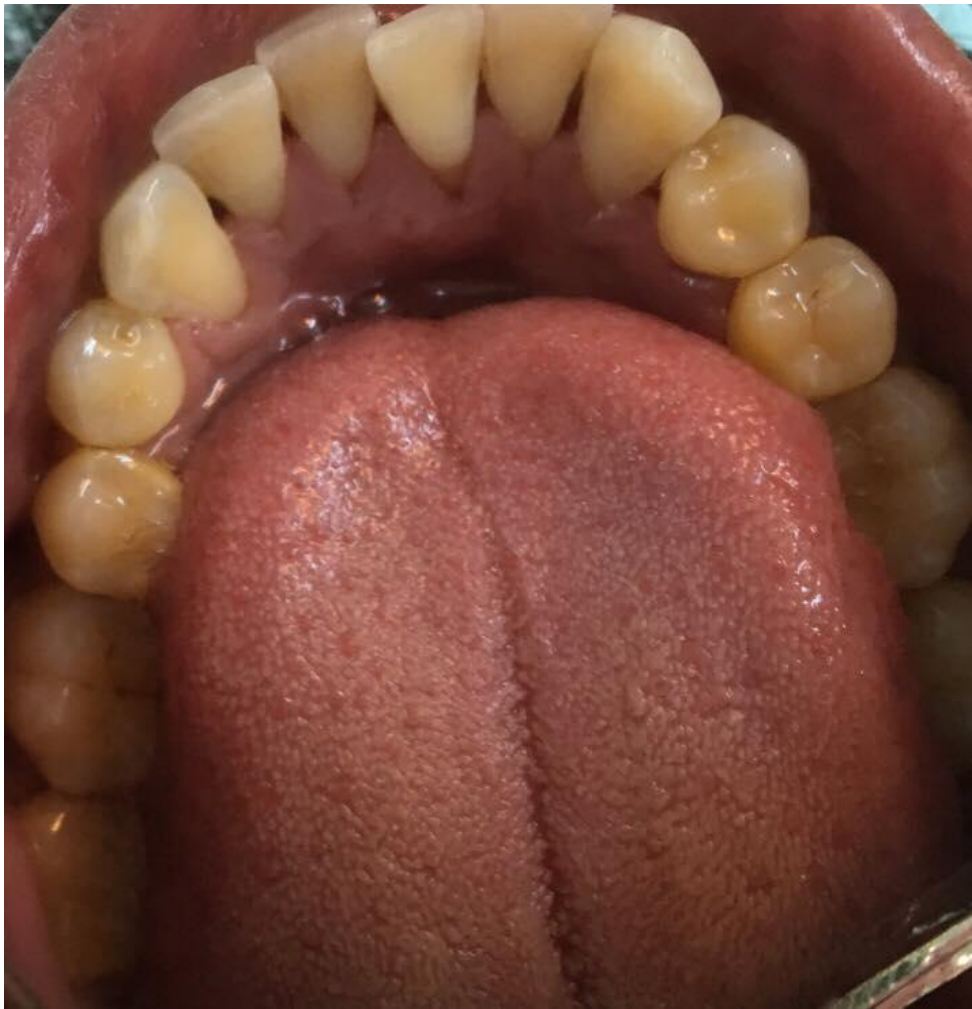Phase I – Diet Sheet

Patient Name: [Redacted] Gender: M/F Date of Birth: 25-4-1984
 Occupation: [Redacted] Address: الماشوريت

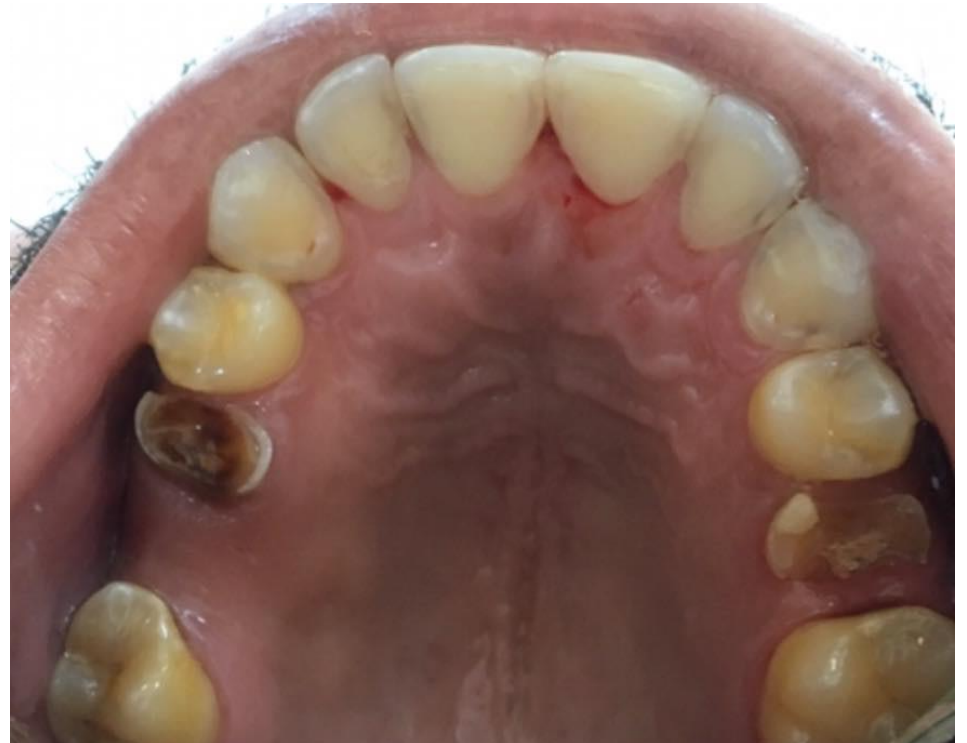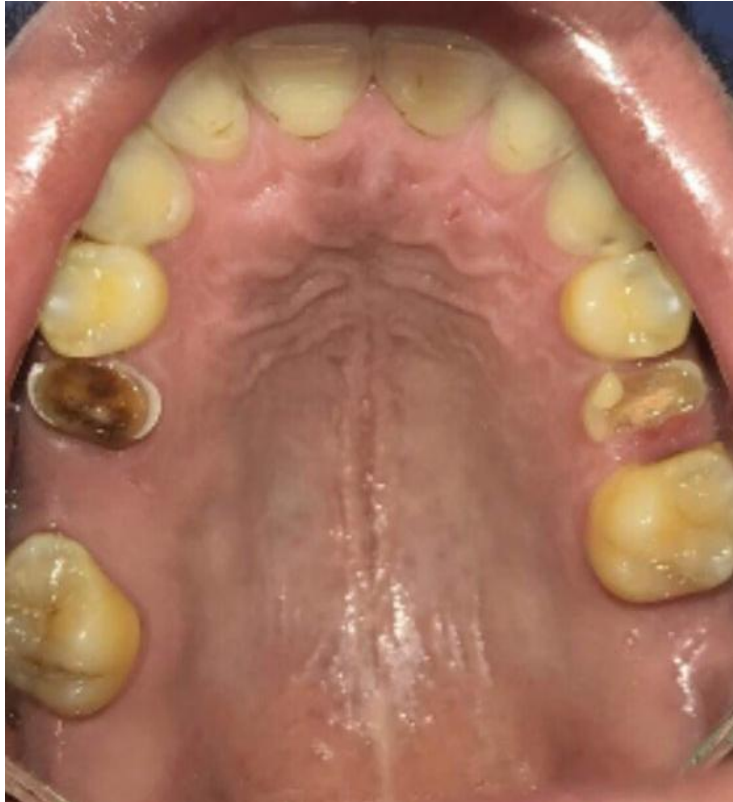نوع الوجبة	المأكولات والمشروبات	الساعة	الأيام
فطور	قهوة + شوكولاتة + كوب ماء	10	الخميس
غداء	مكرونة + دجاج + سلطة + قزوز	2	
عشاء	شاي + خبز بالجنينة	4	
	مكباته	6	
	هامبرج + قزوز	10	
فطور	تفاح + دس + فول + كلبا	11	الجمعة
غداء	قهوة (ز أبيض + مضي)	11:30 2	
عشاء	كيك + مكباته	5:30	
	أصيكة + بيبي	11	
فطور	قهوة + كيك	10	السبت
غداء	طبيخة بطاطة + سلطة + قزوز	3	
	بروش + مكباته	7	
عشاء	سندوتش تفاح + دس	11	

Phase I –Scaling before & after

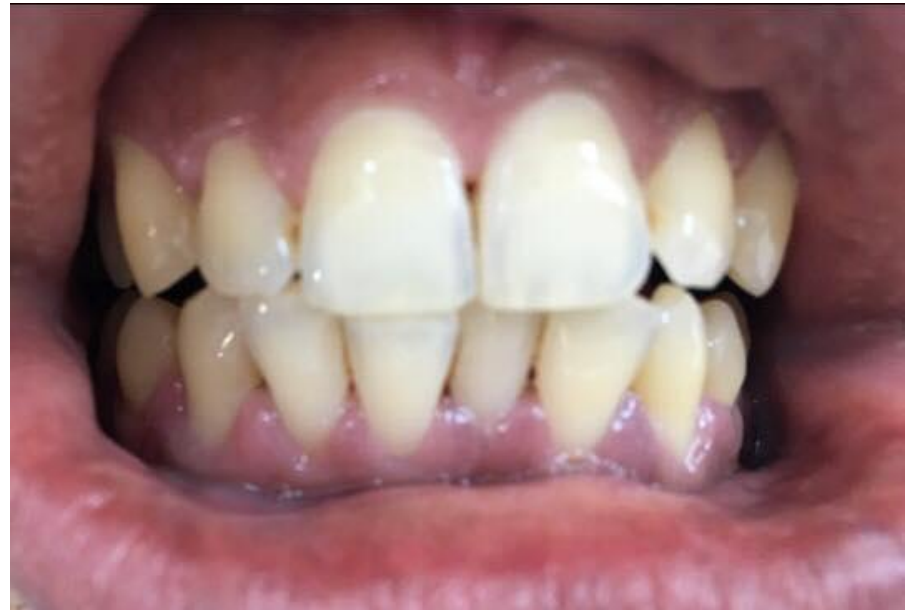
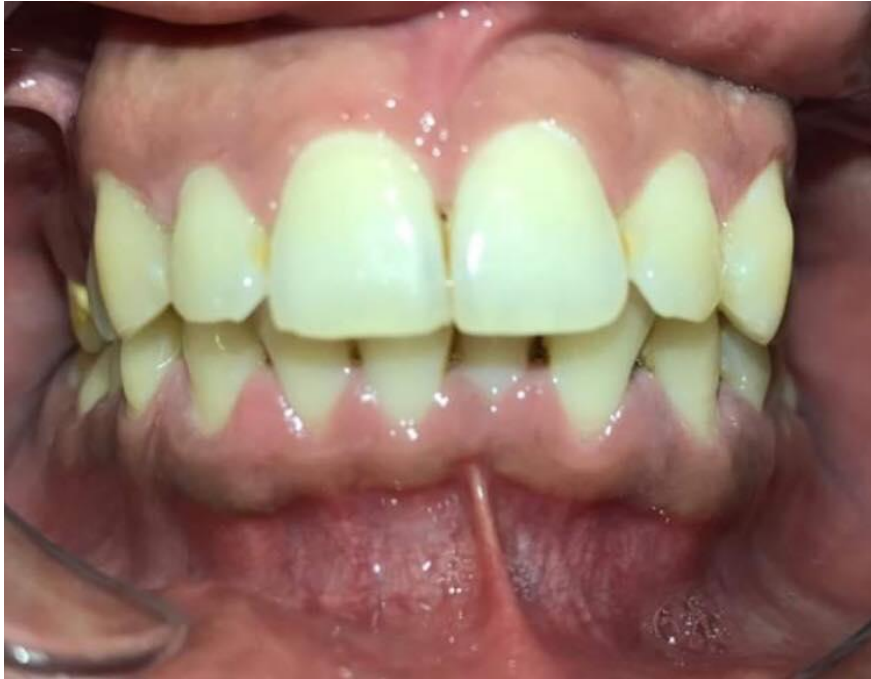


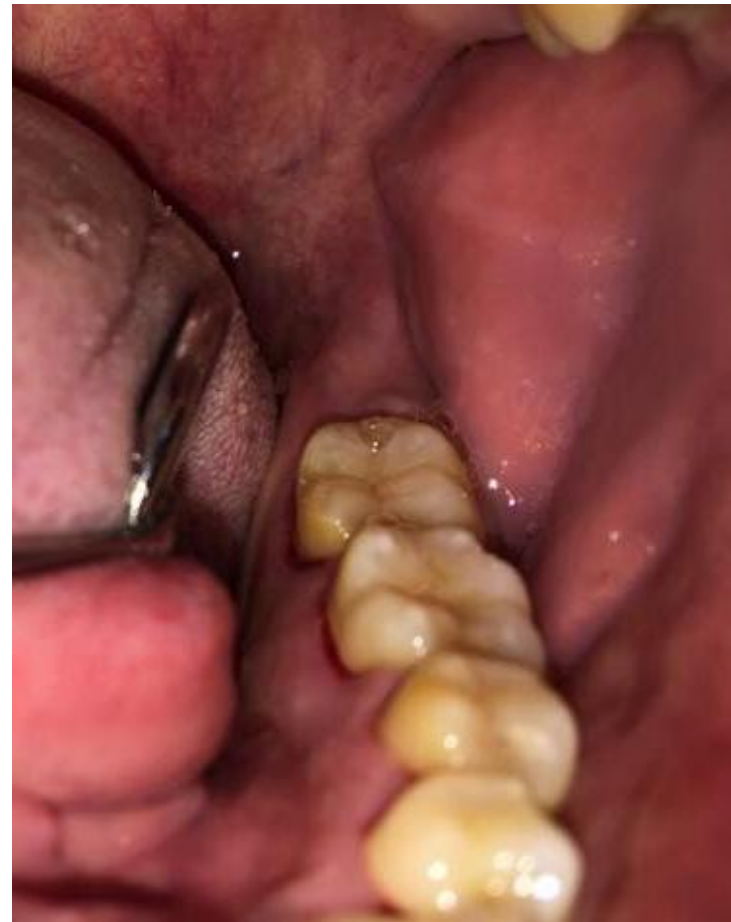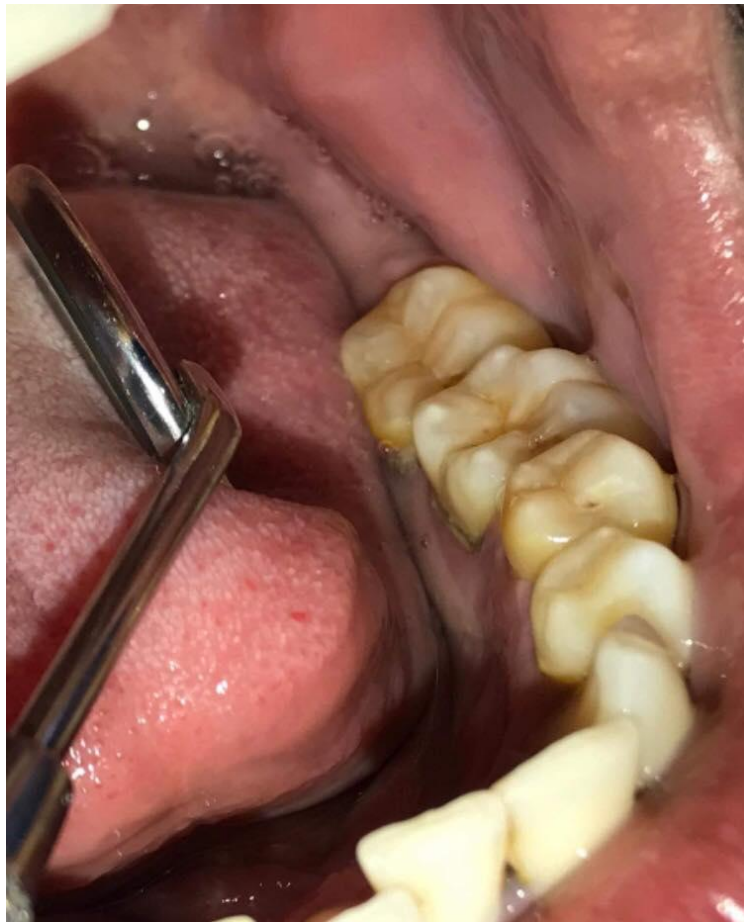Phase I –Scaling before & after



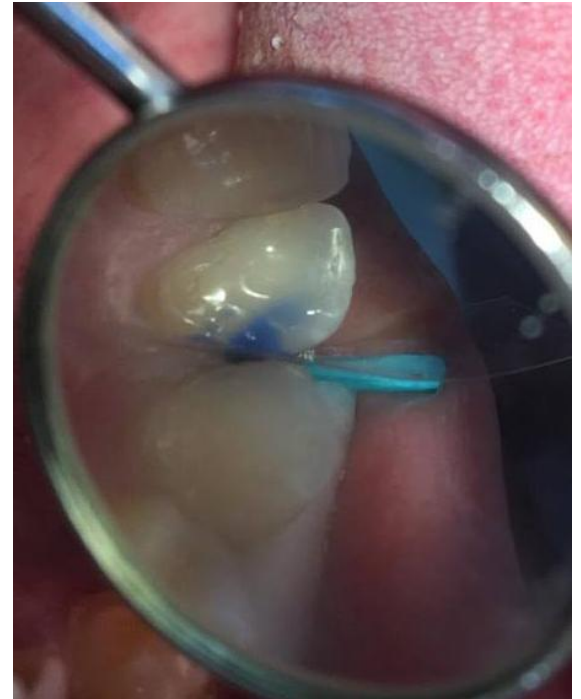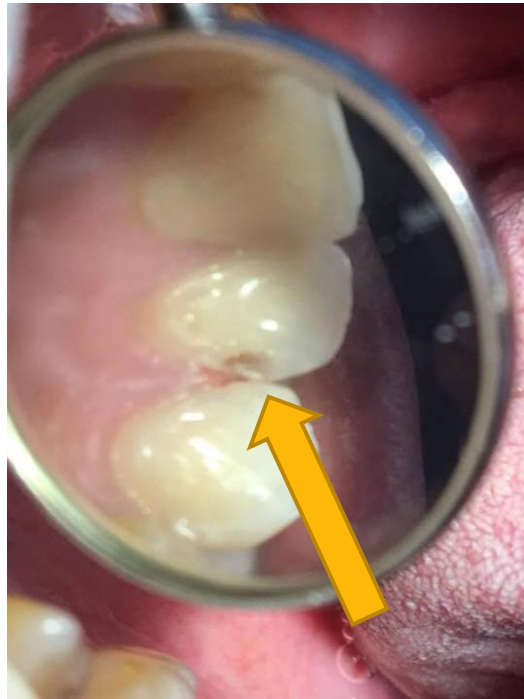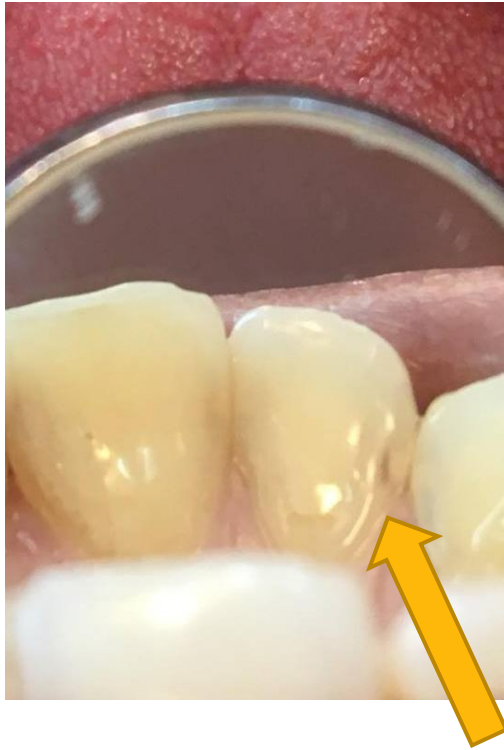Phase I –Scaling before & after



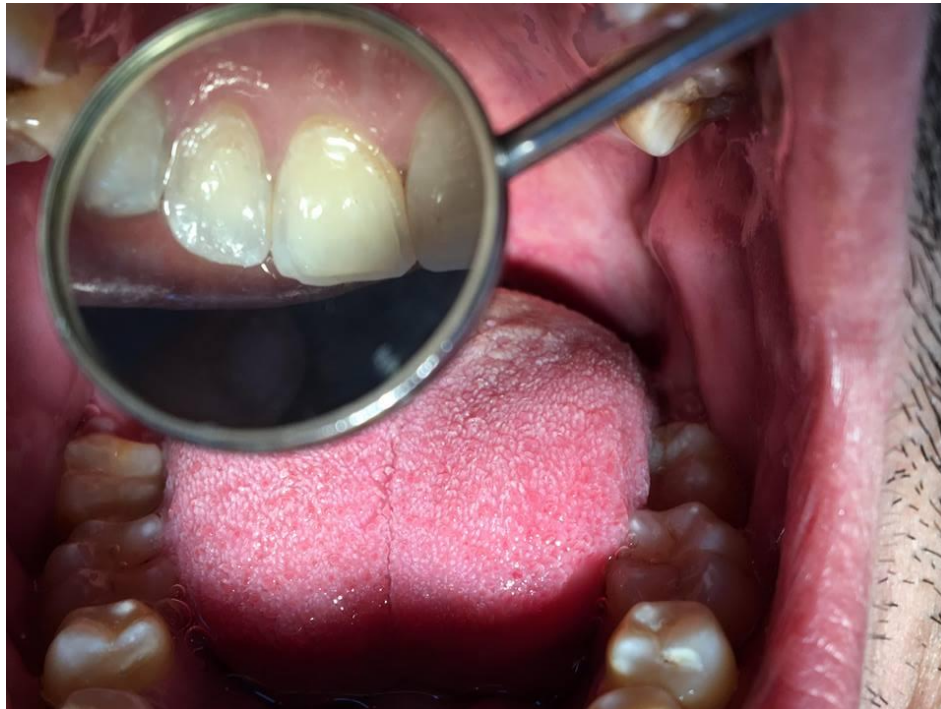Phase I –Scaling before & after



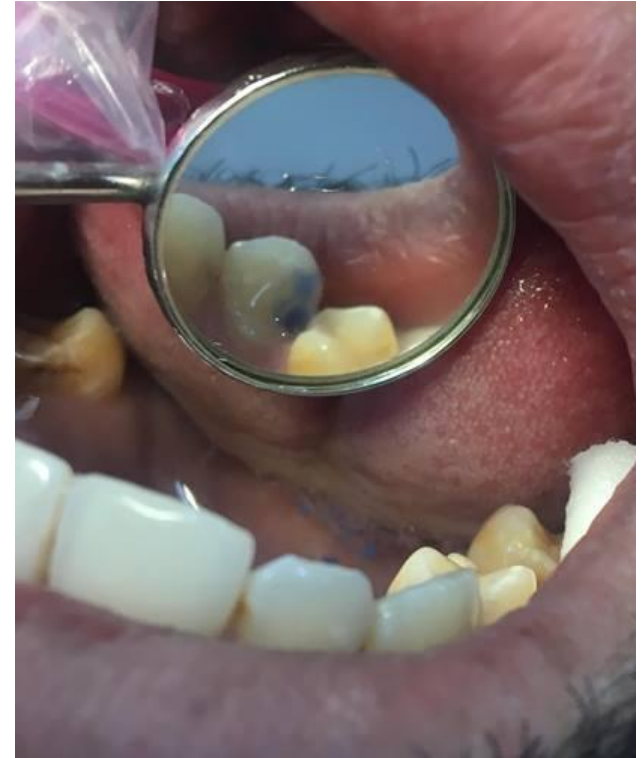
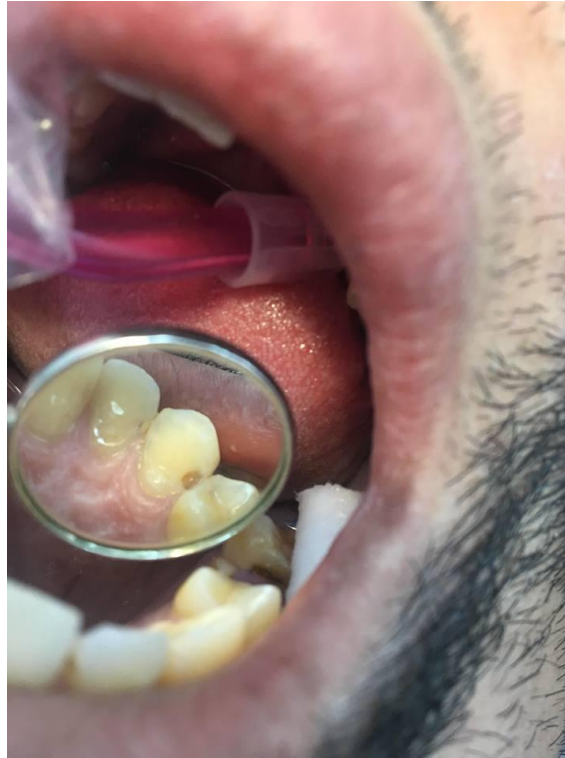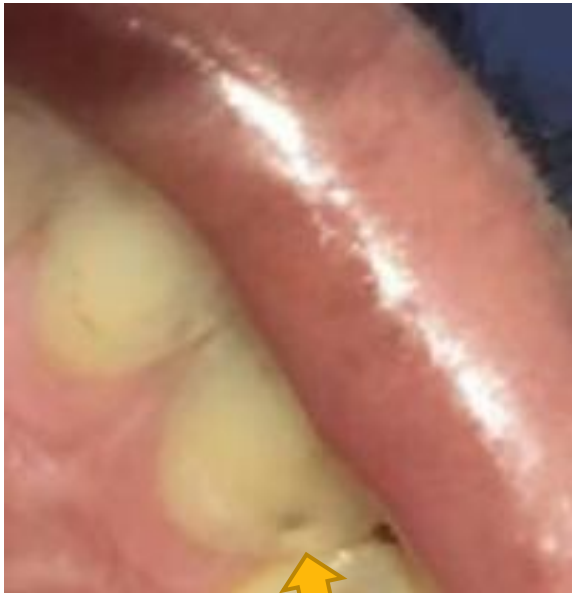Restoration of UR2



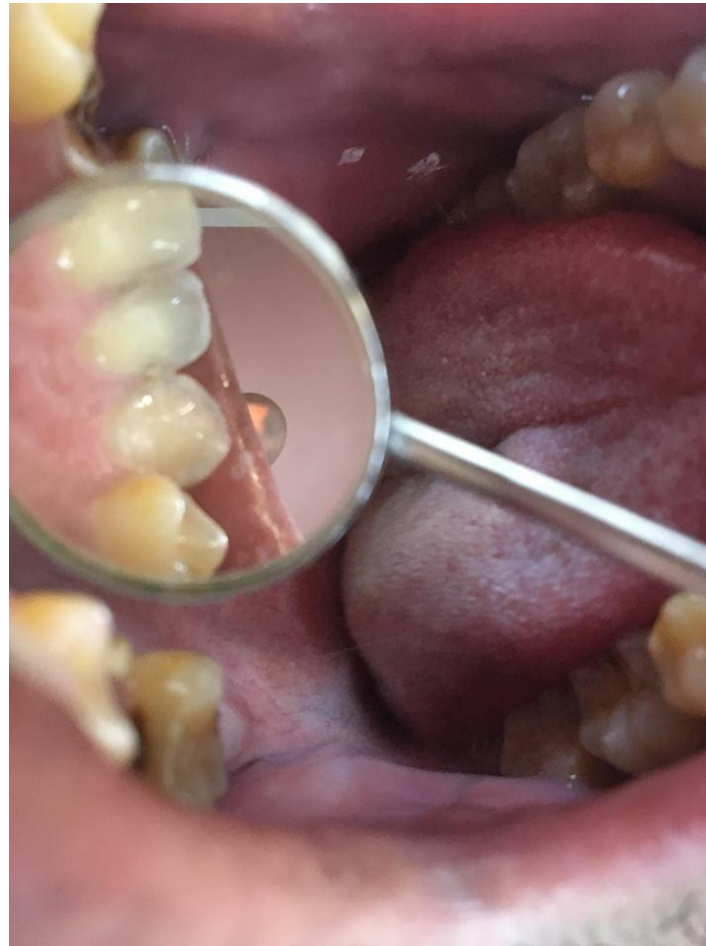Restoration of UR2



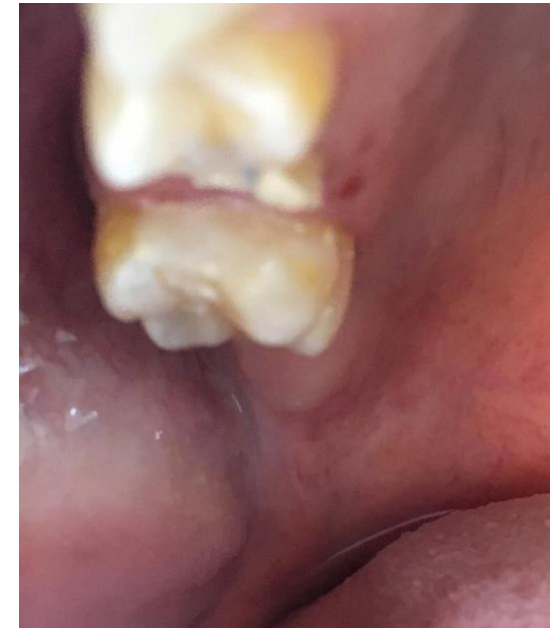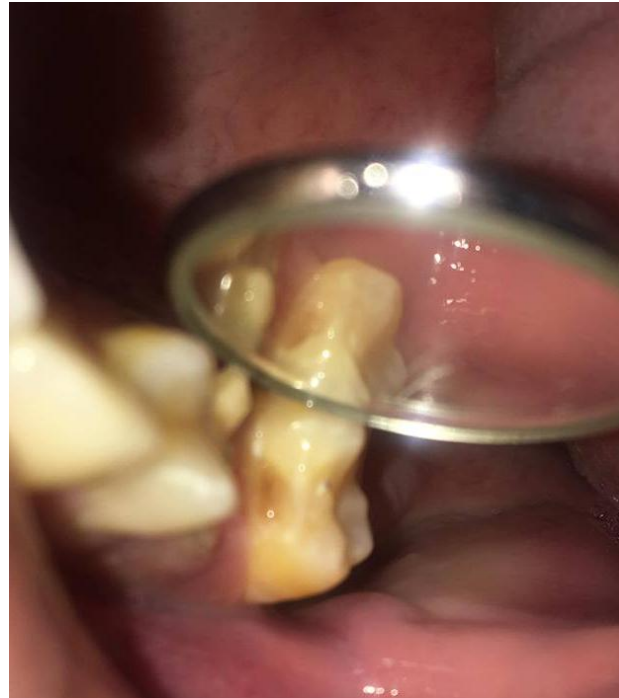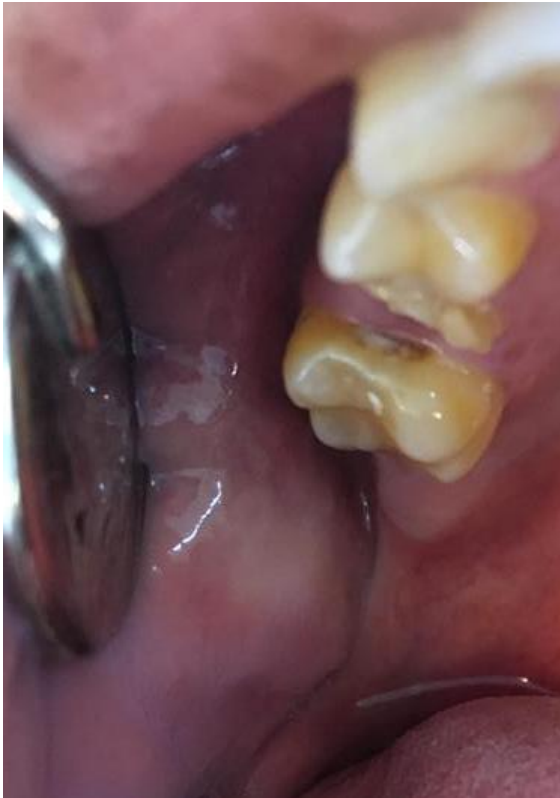Restoration of UR3



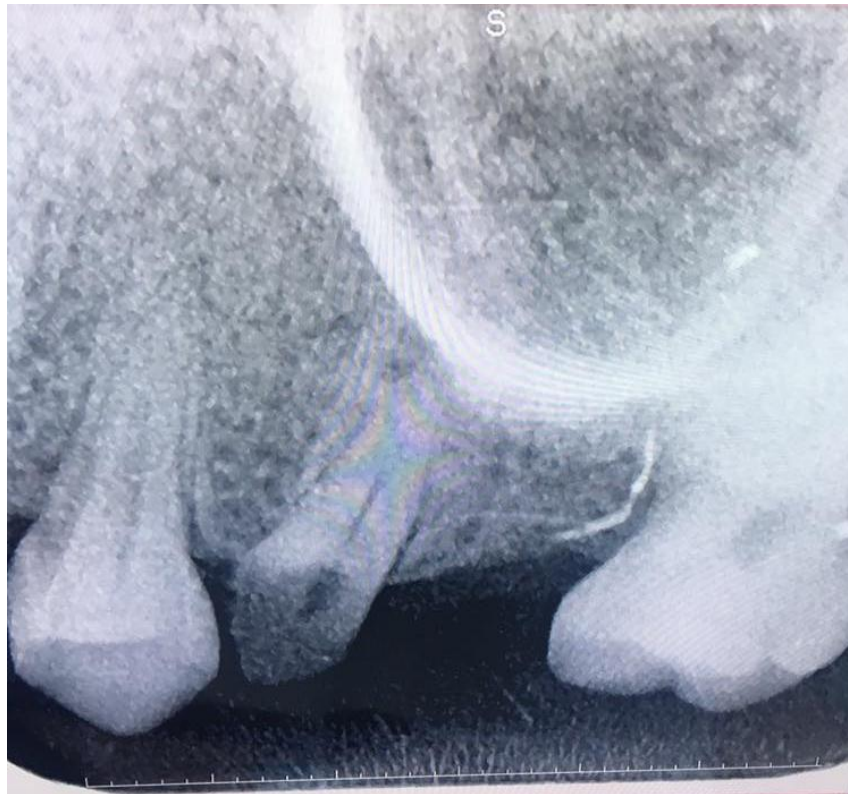
Restoration of UR3



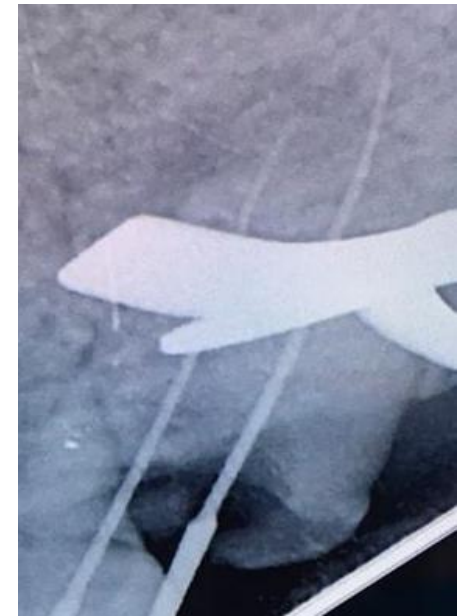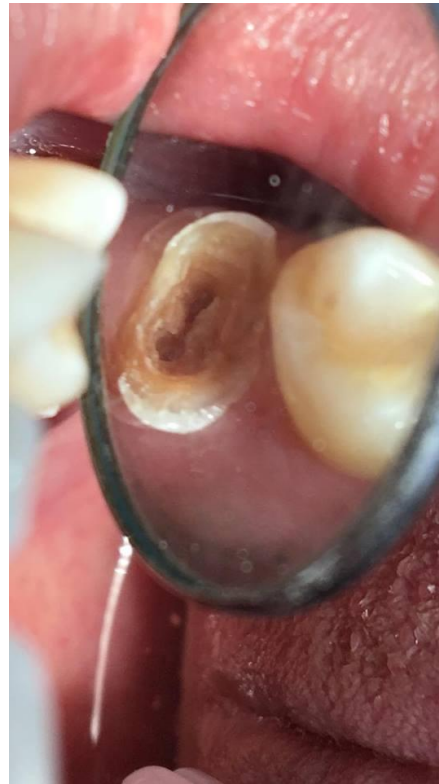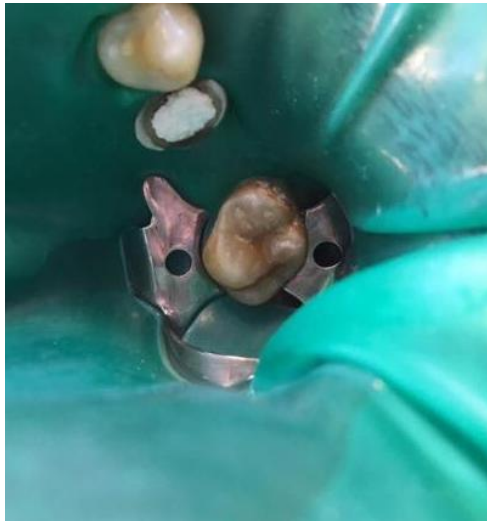Restoration of UR6



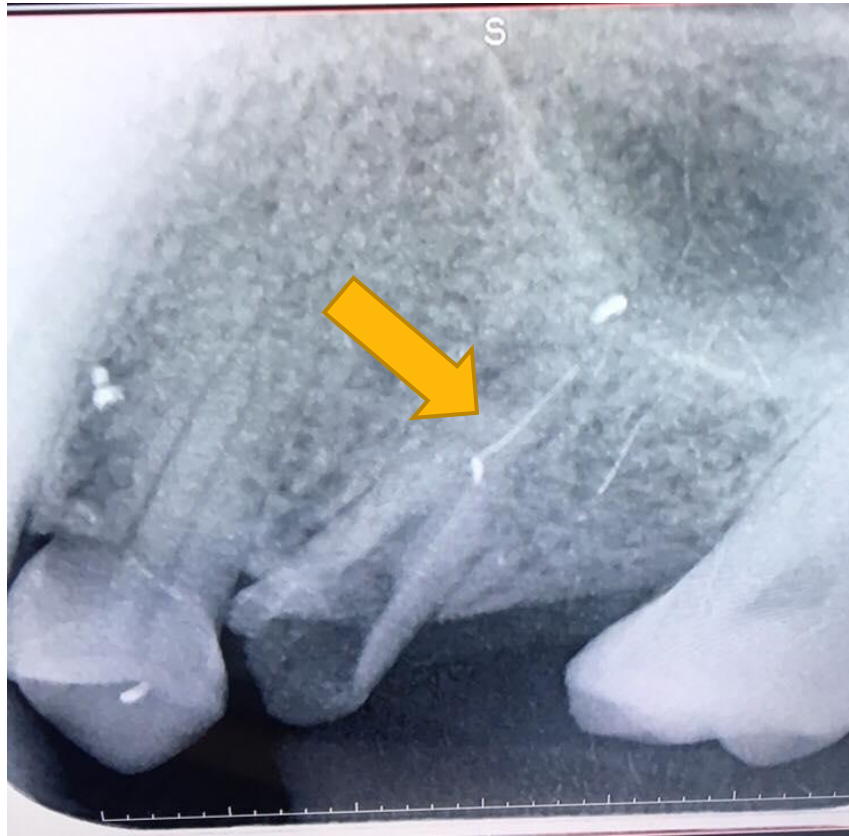
Phase III – RCT for UL5 – pre operative periapical radiograph



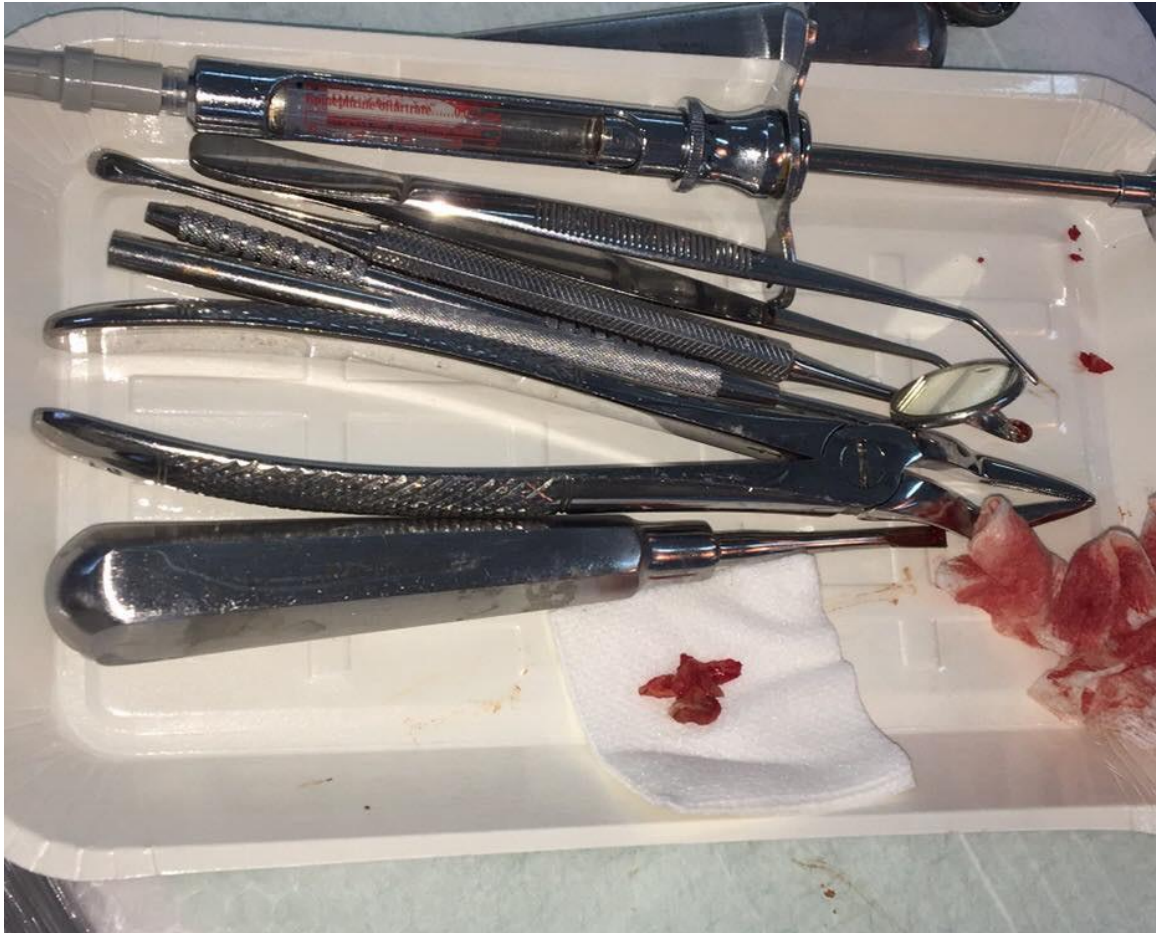Phase III – RCT for UL5



Phase III – RCT for UL5 – COMPLICATION

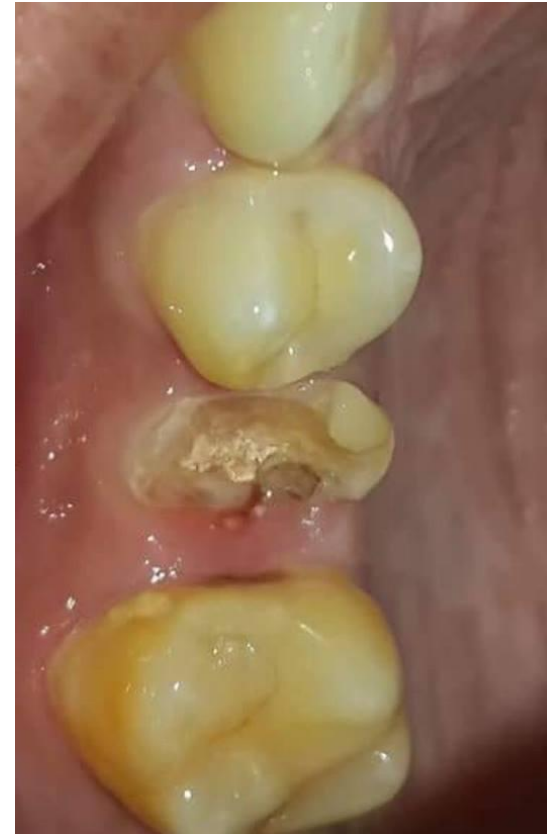
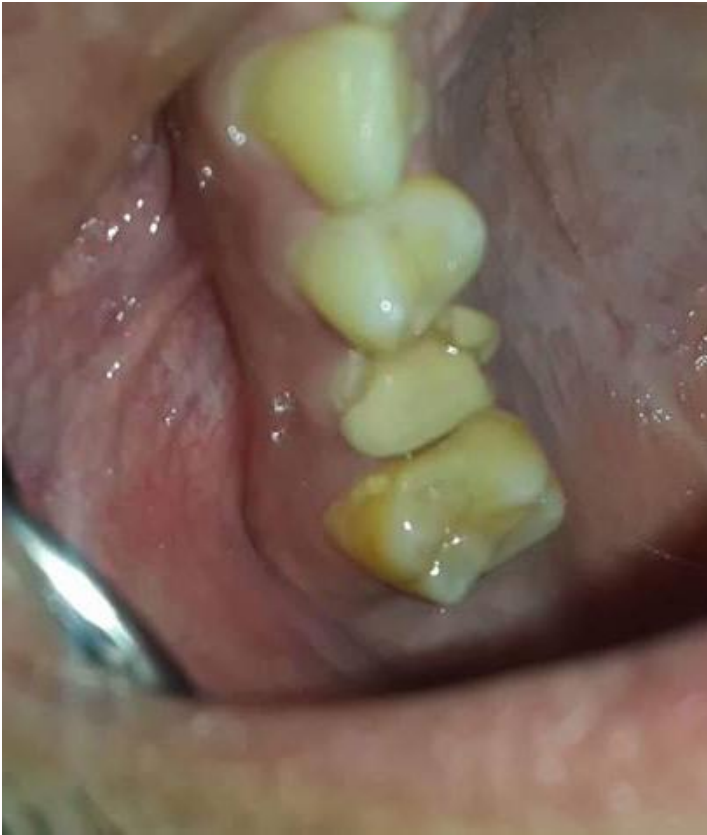
Phase III – RCT for UL5 was cancelled to be extracted

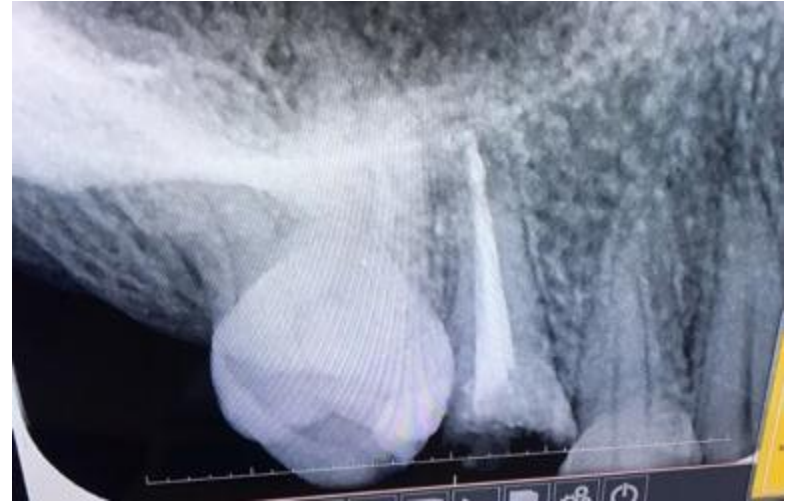
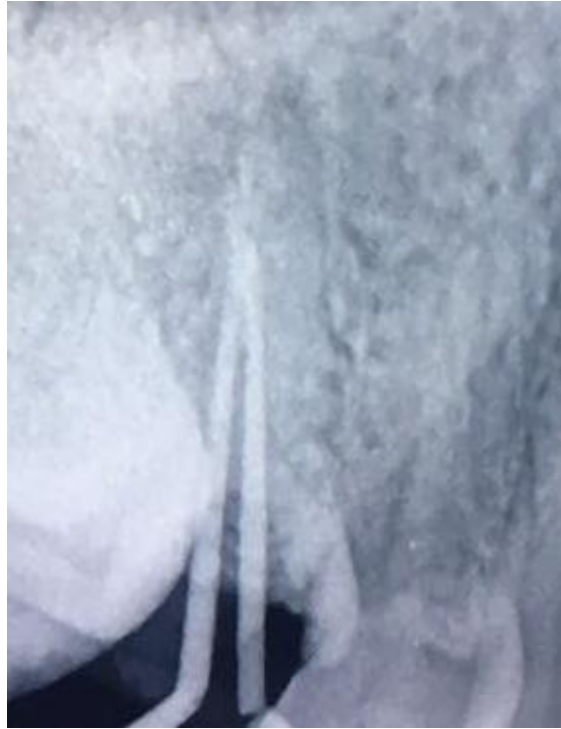
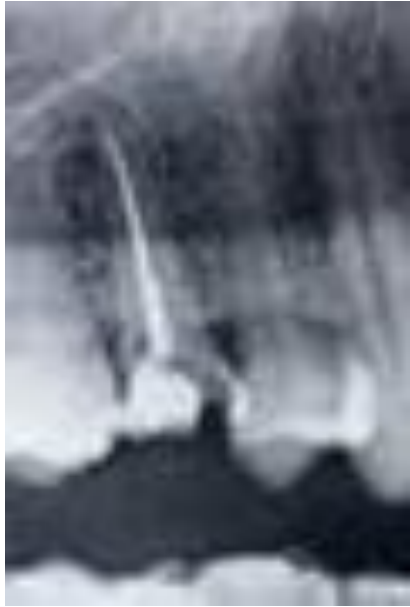Phase III – restoration of UR5

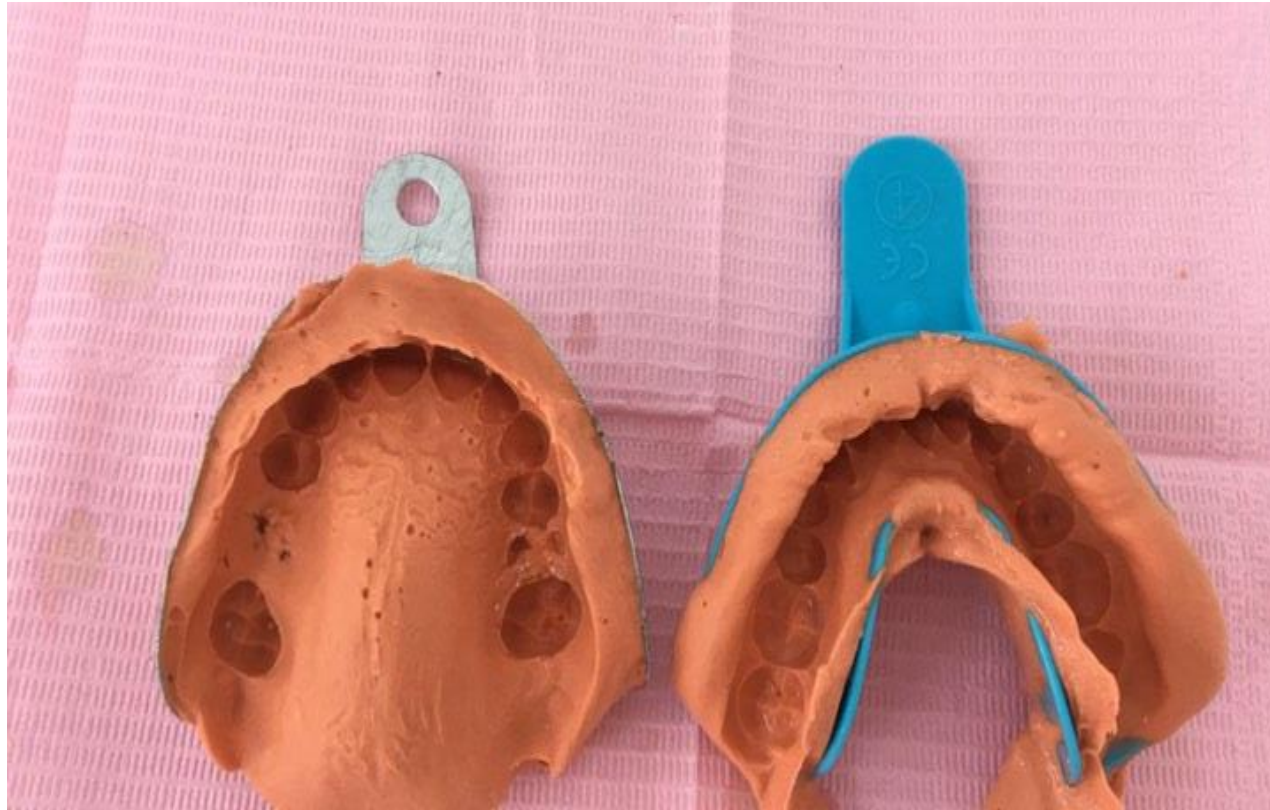Clinical photo (before)



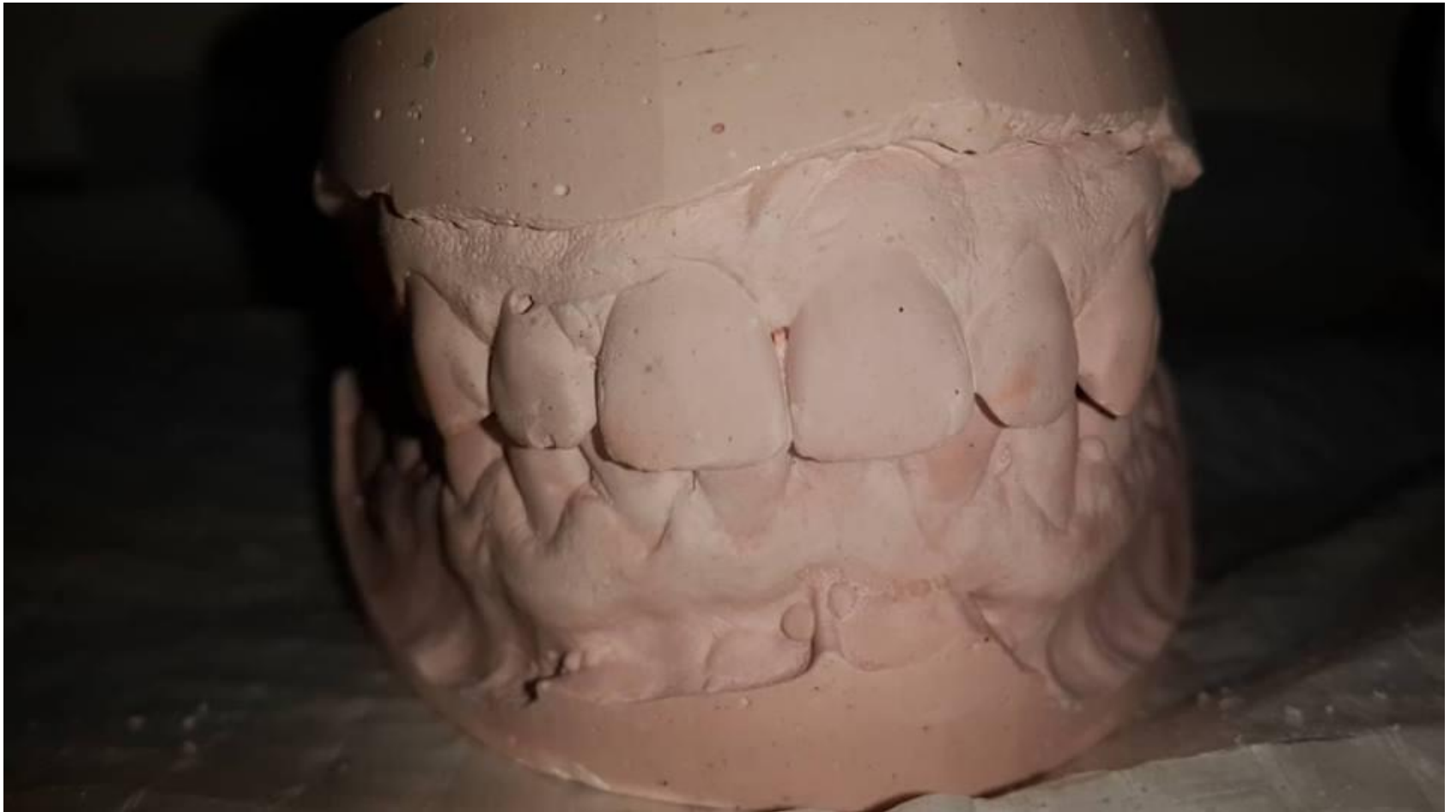Retreatment



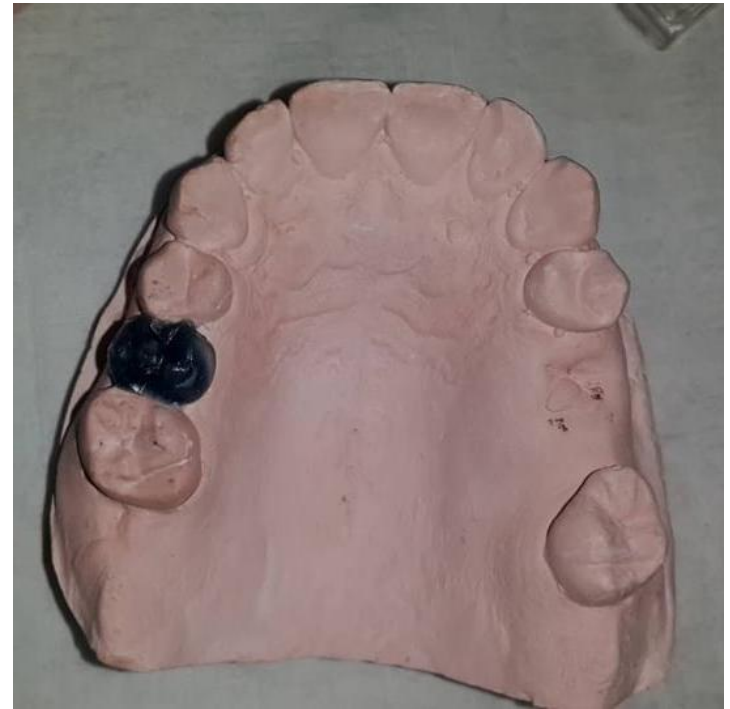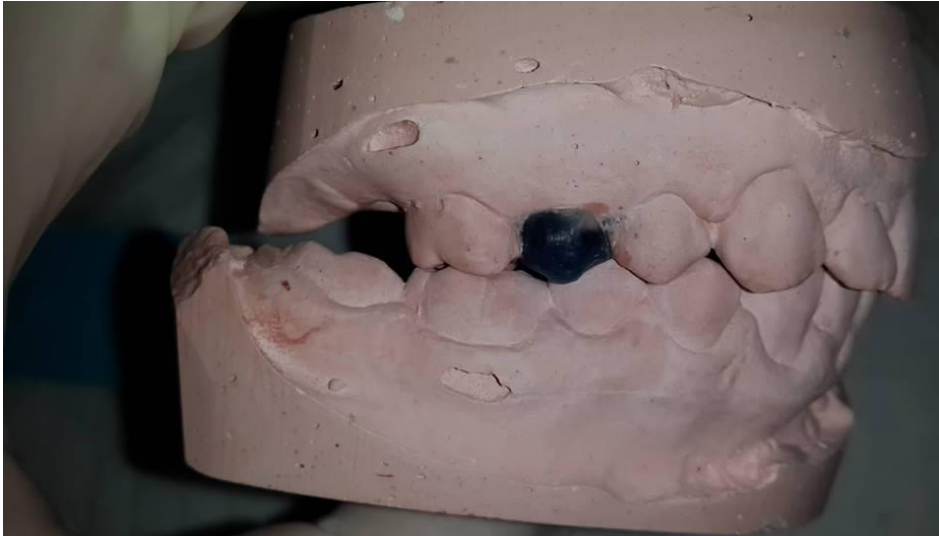Primary impression



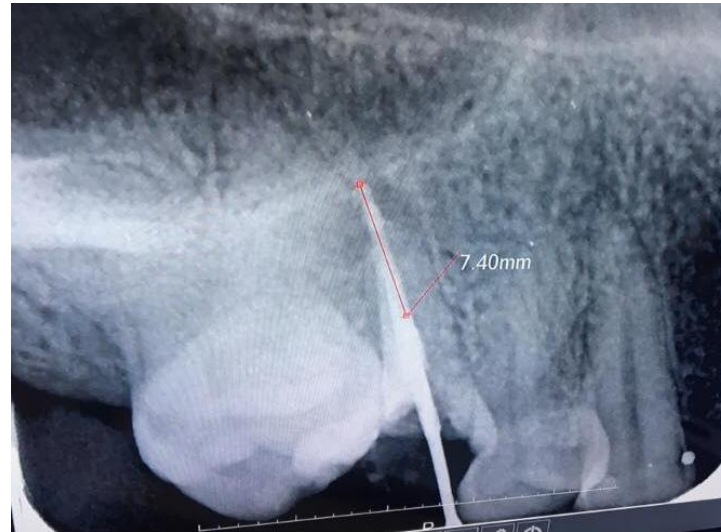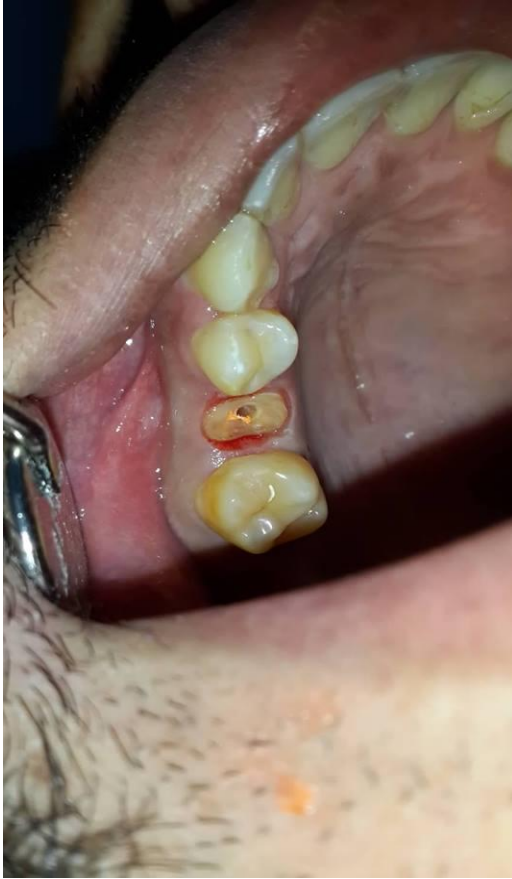Diagnostic casts



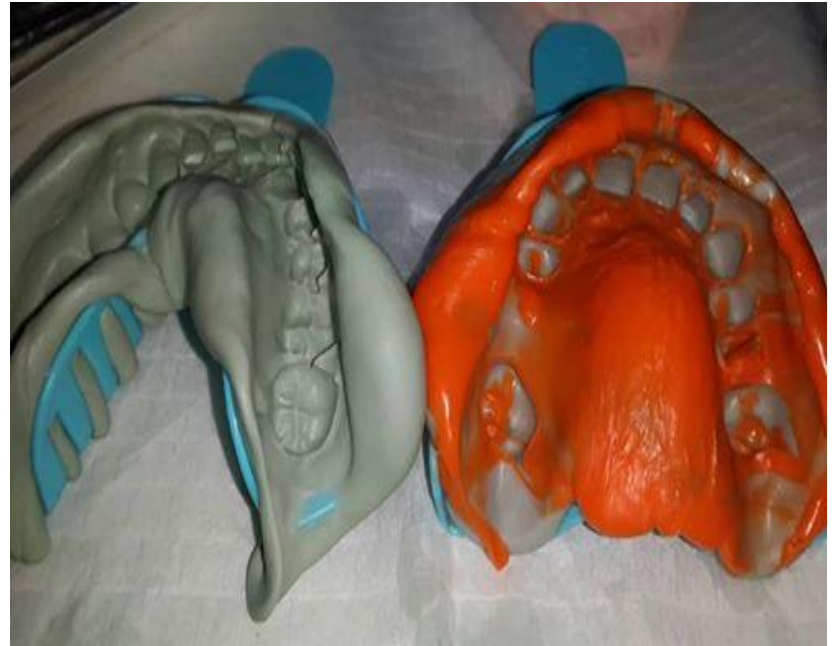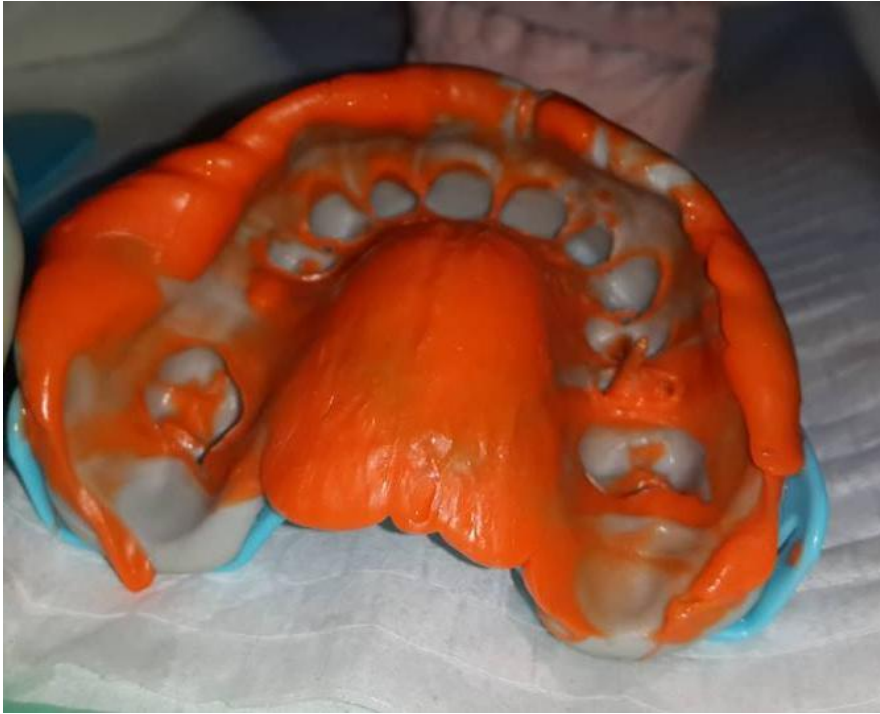Wax - up



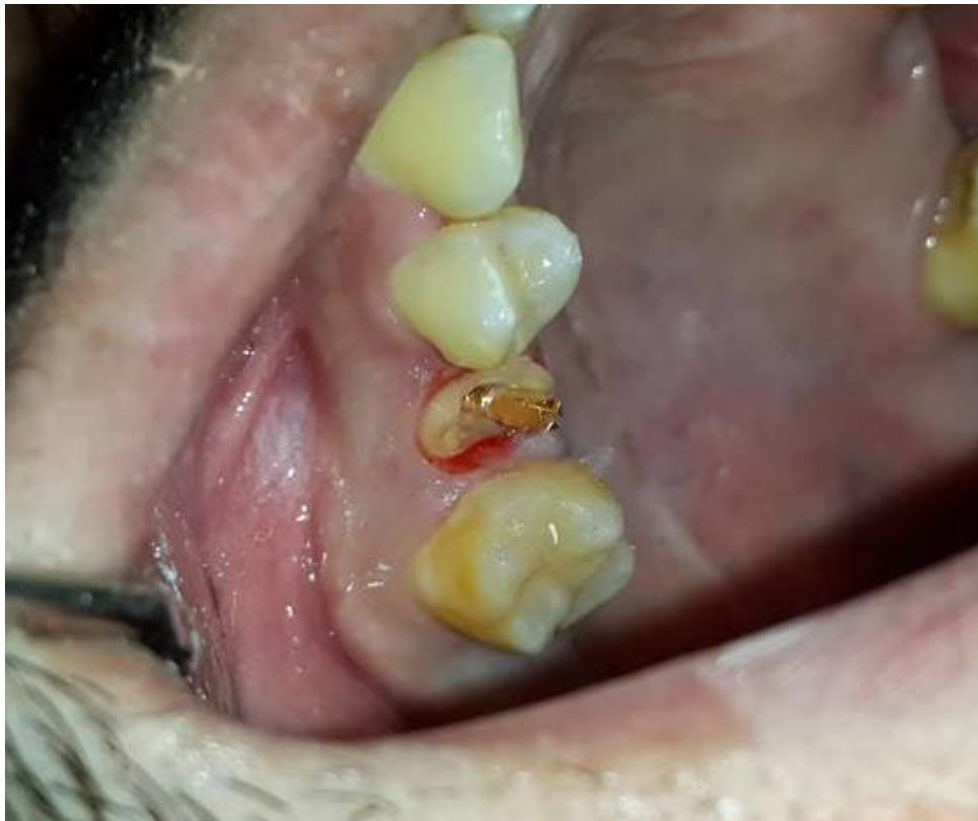Post space preparation



Final impression for post space



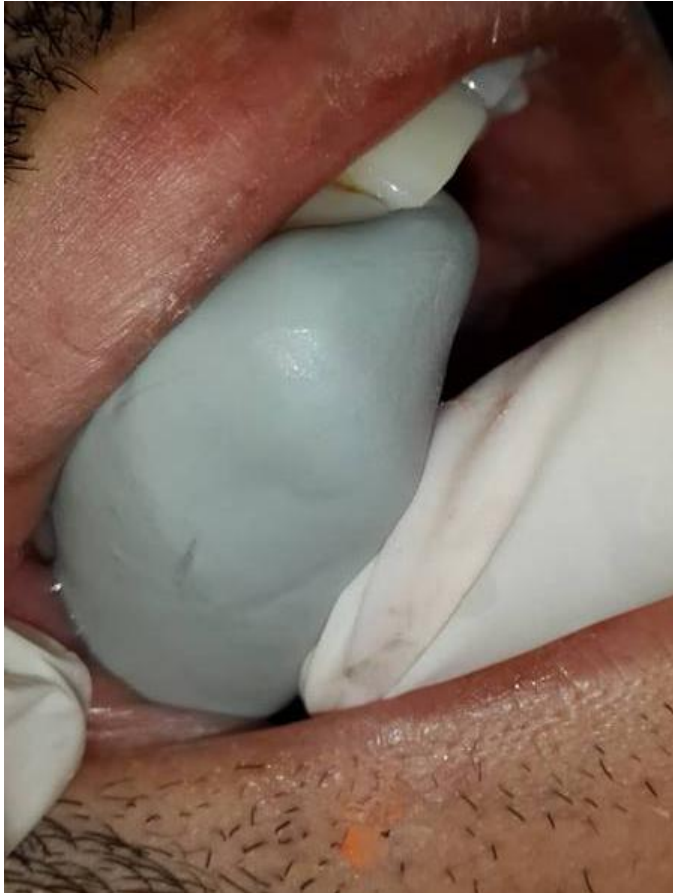
Temporary post cementation



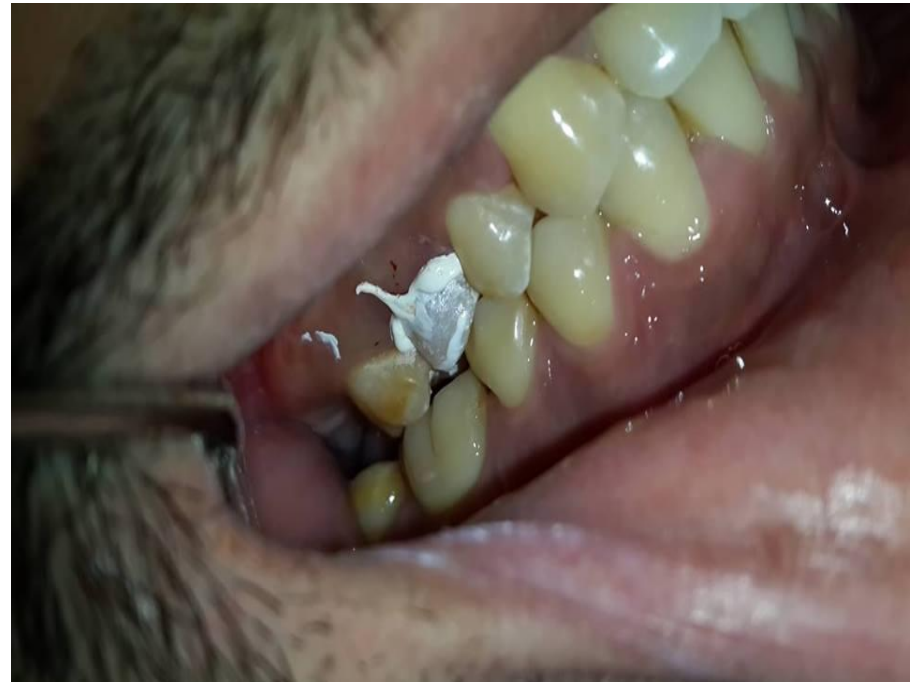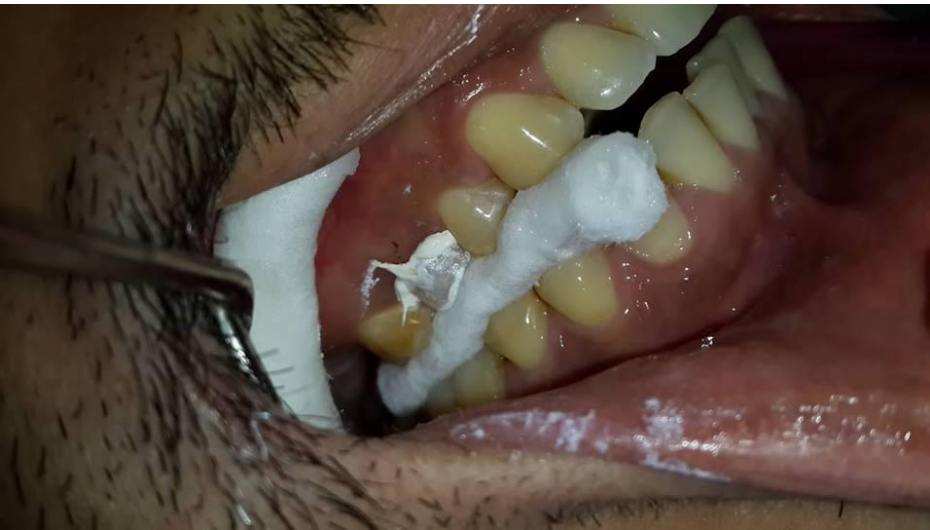Putty index



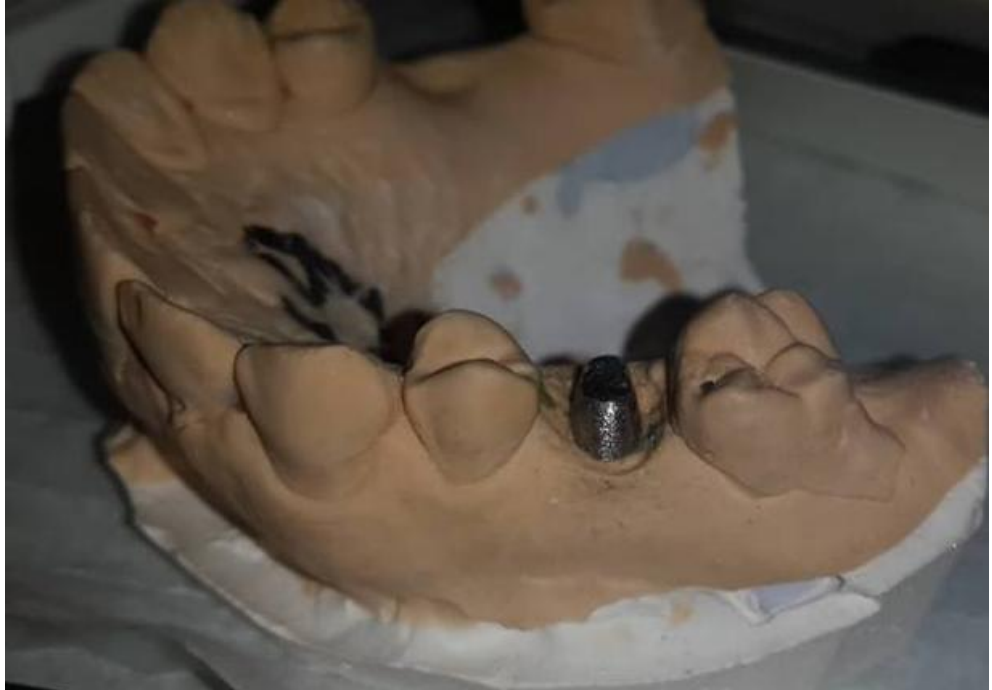Temporary post and core



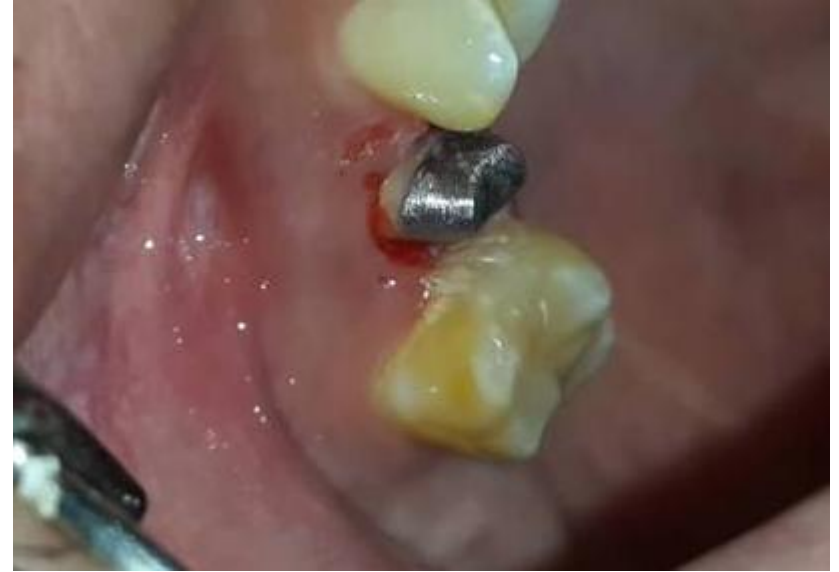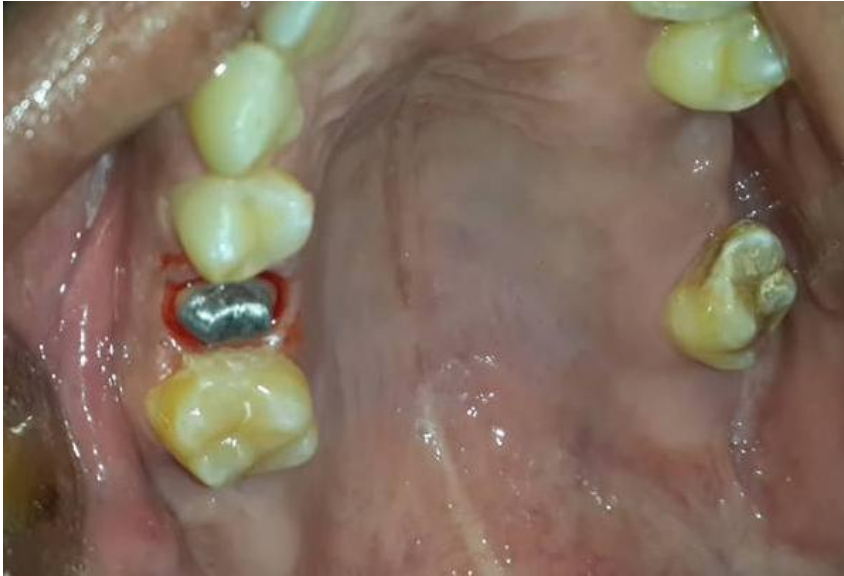Temporary post & core cementation



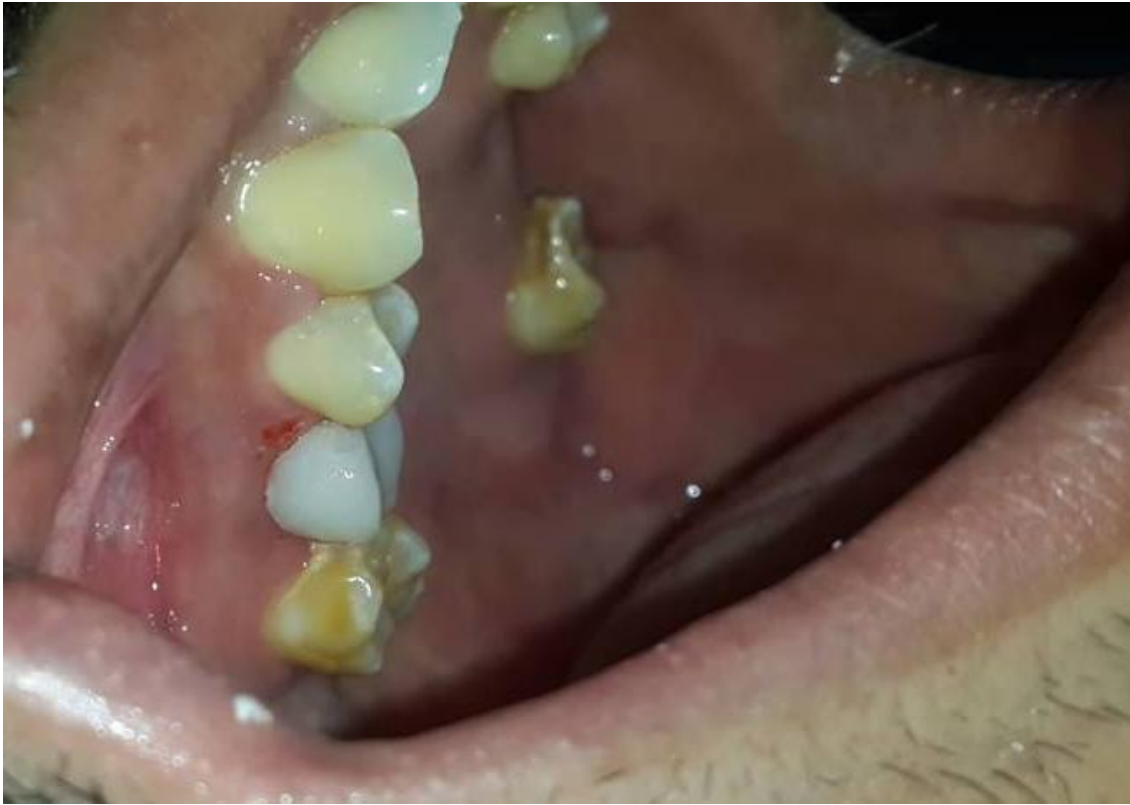Metal try In of custom made post & core



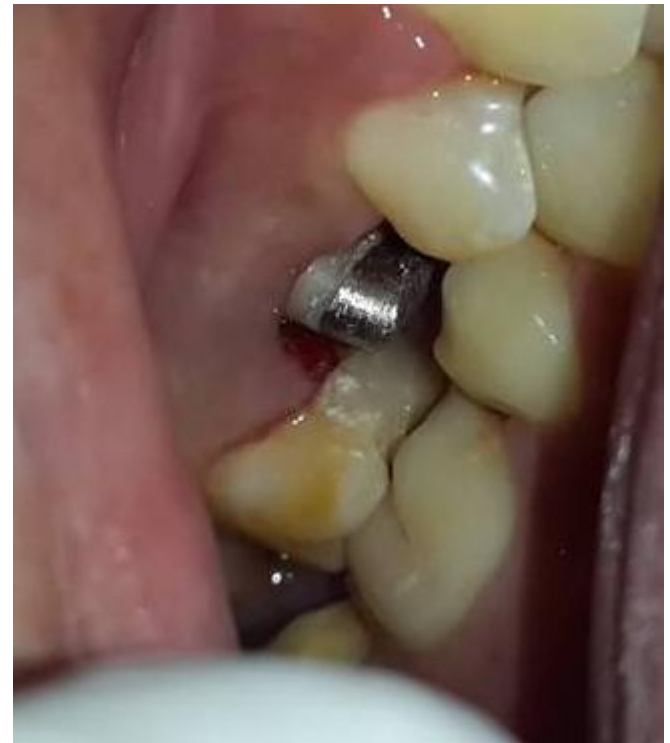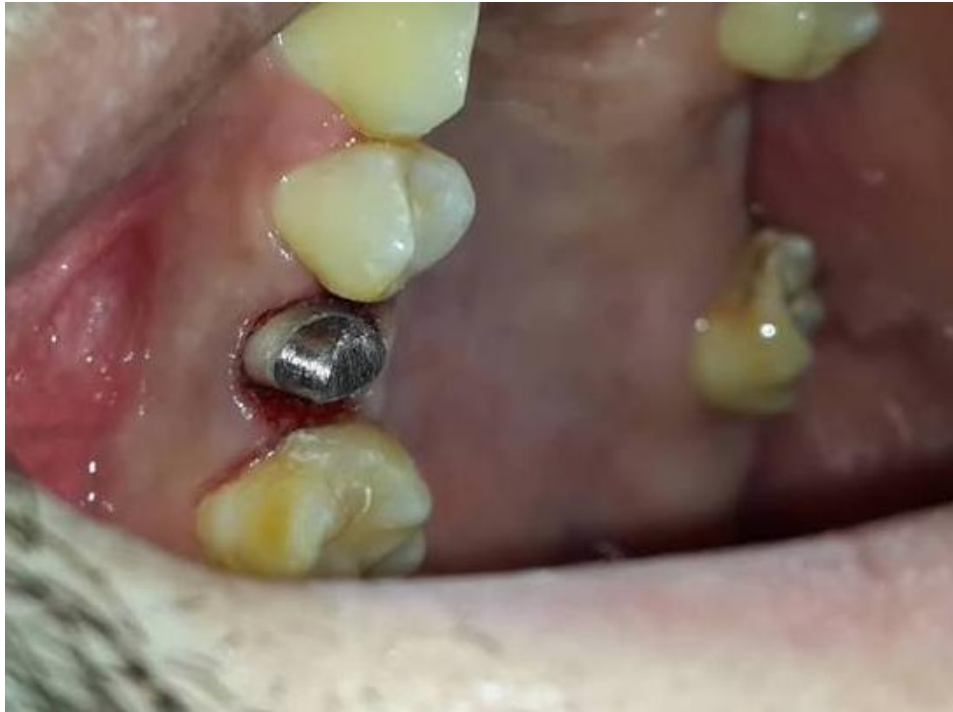Metal try In of custom made post & core



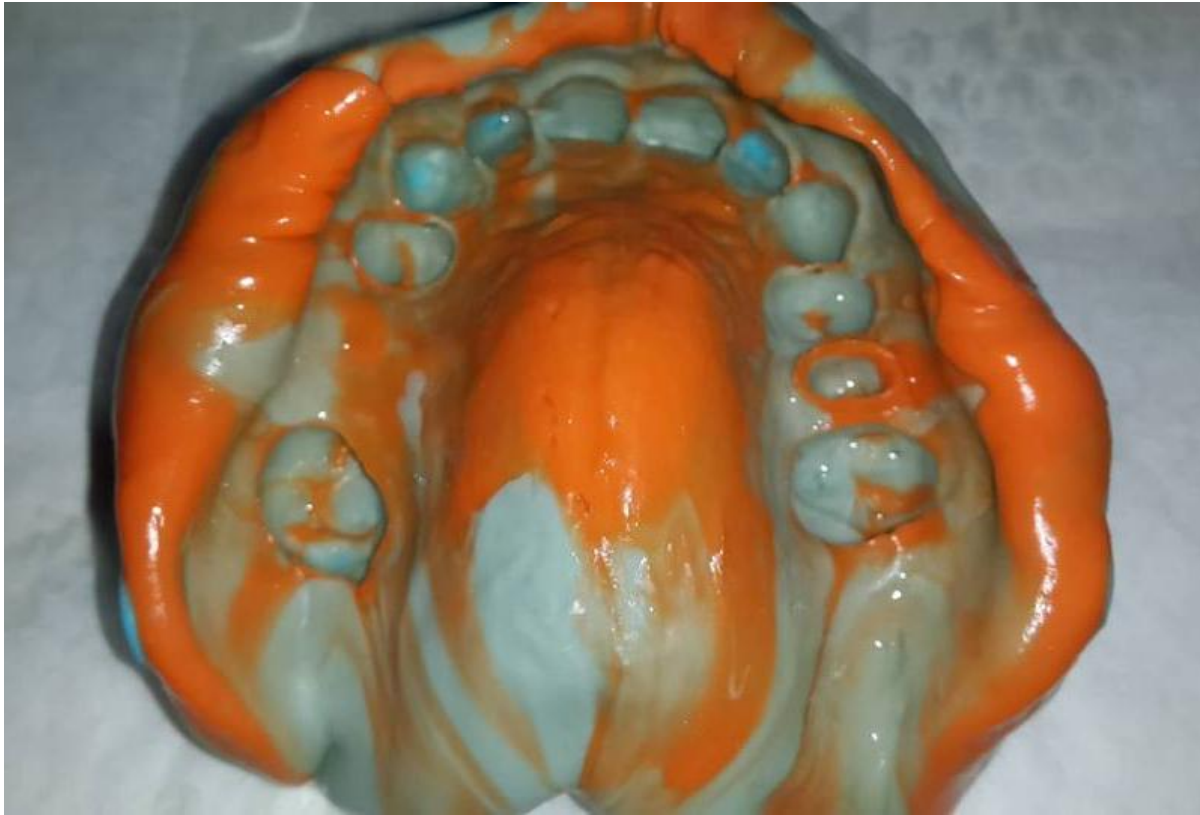Temporary crown



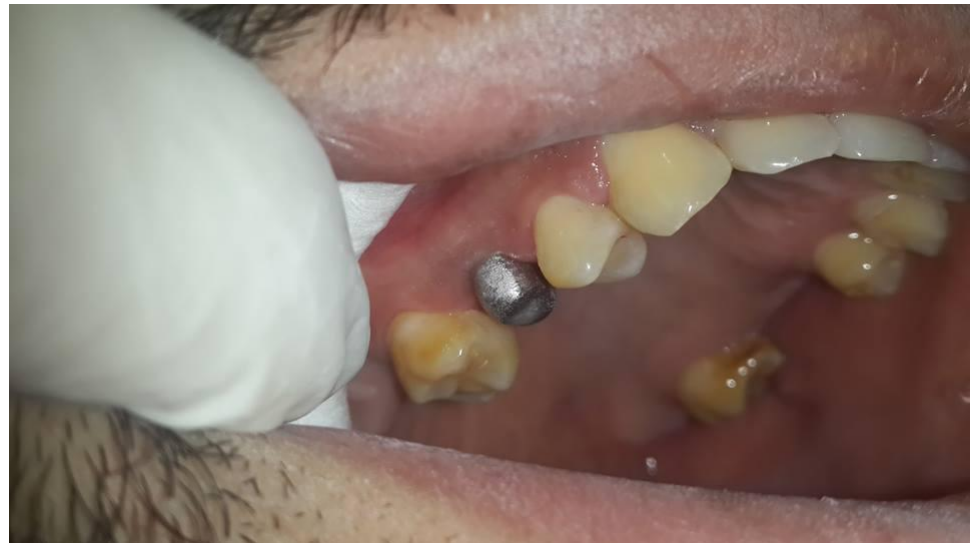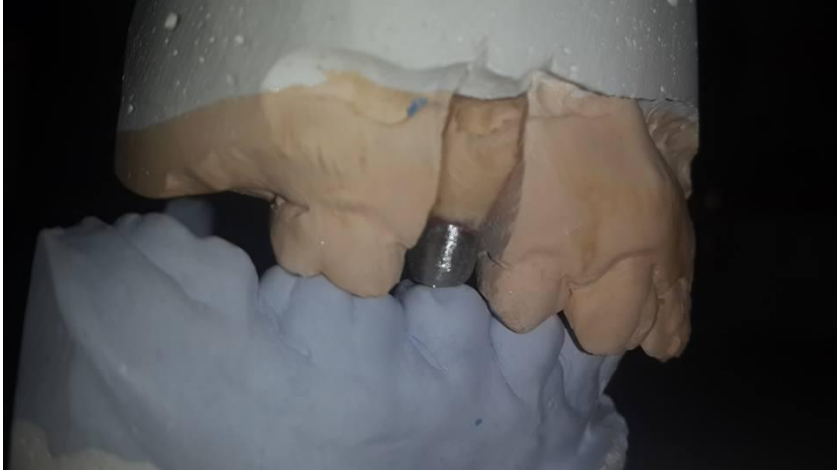Final impression



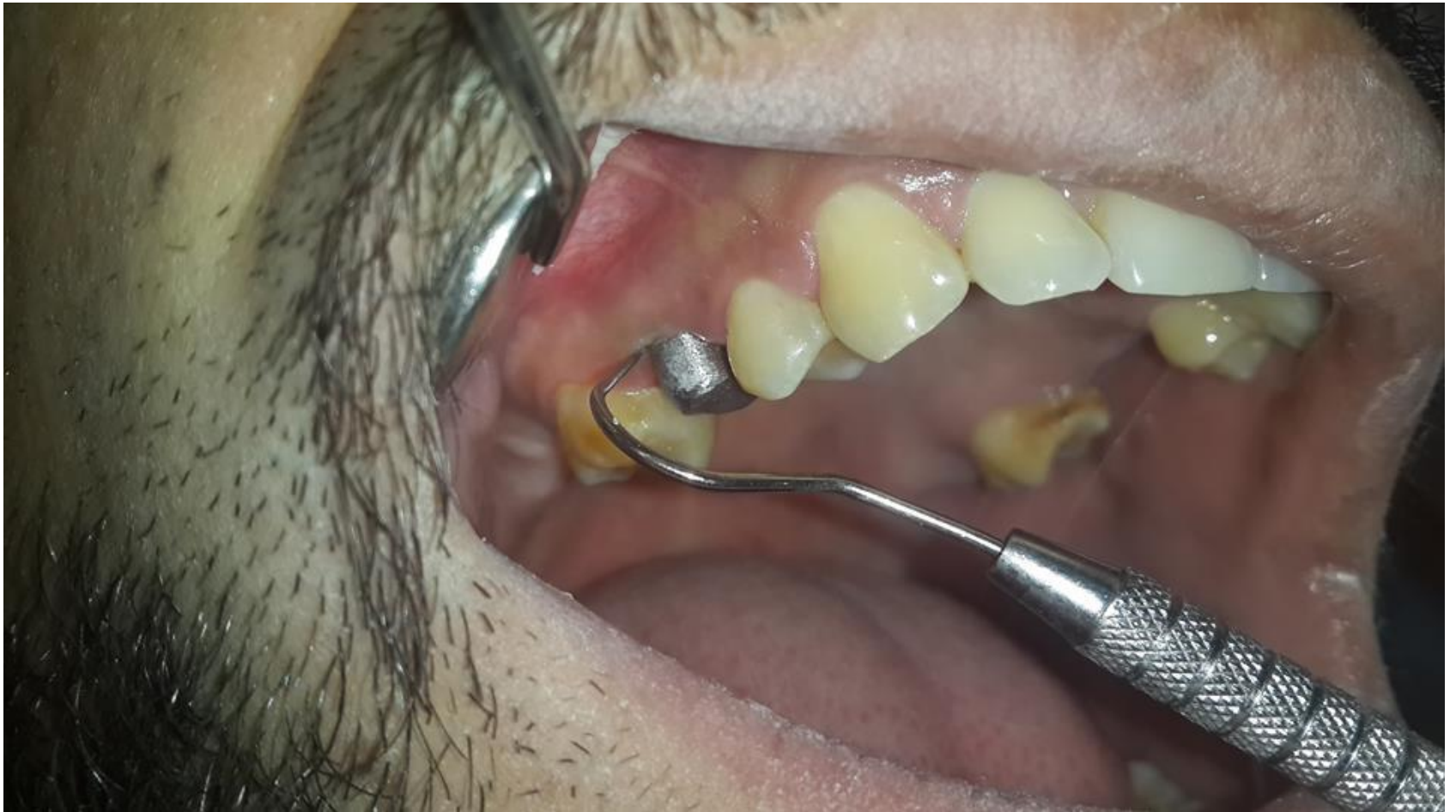Final impression



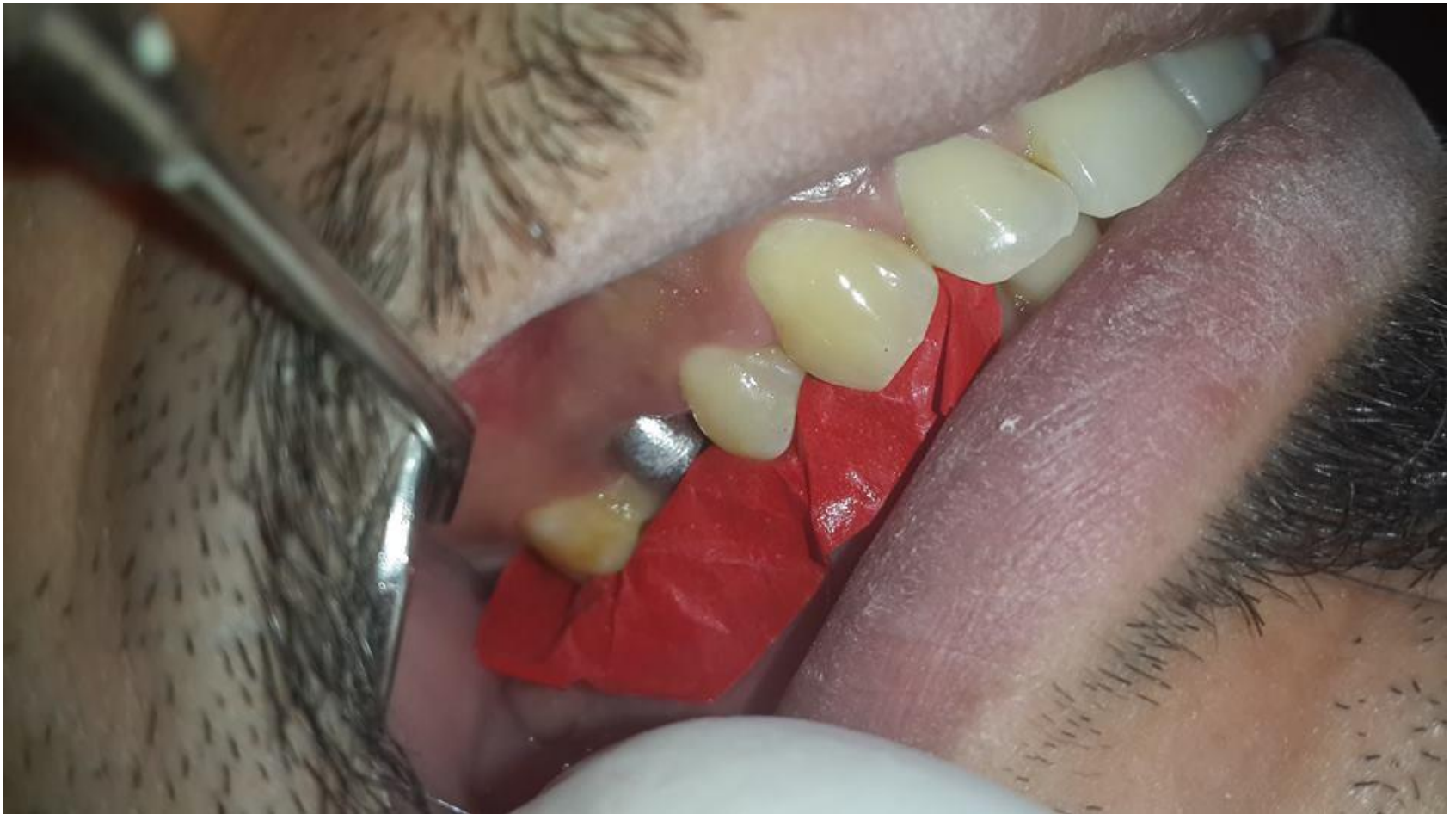Metal try In of PFM crown –



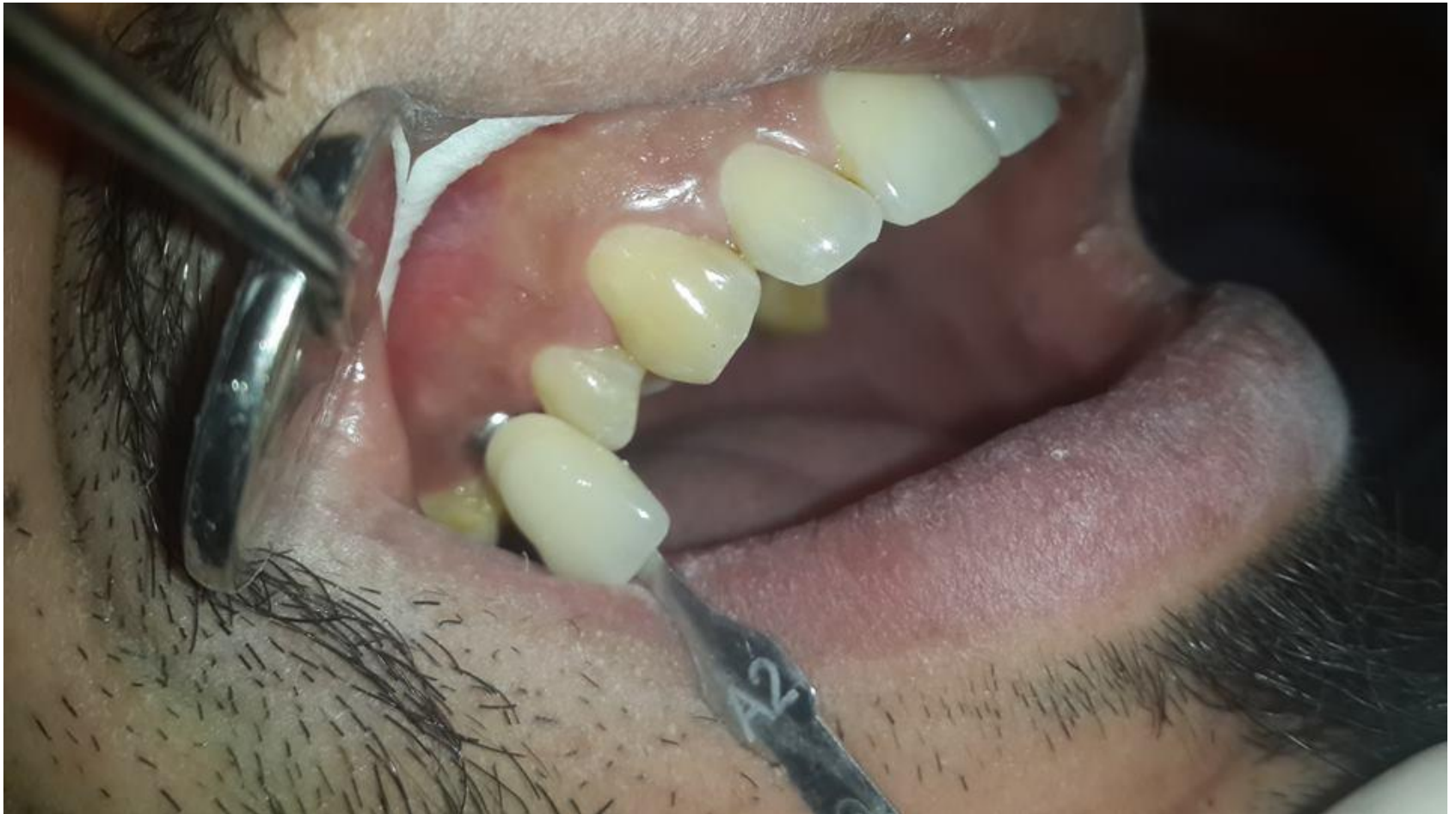Metal try of PFM crown – marginal integrity



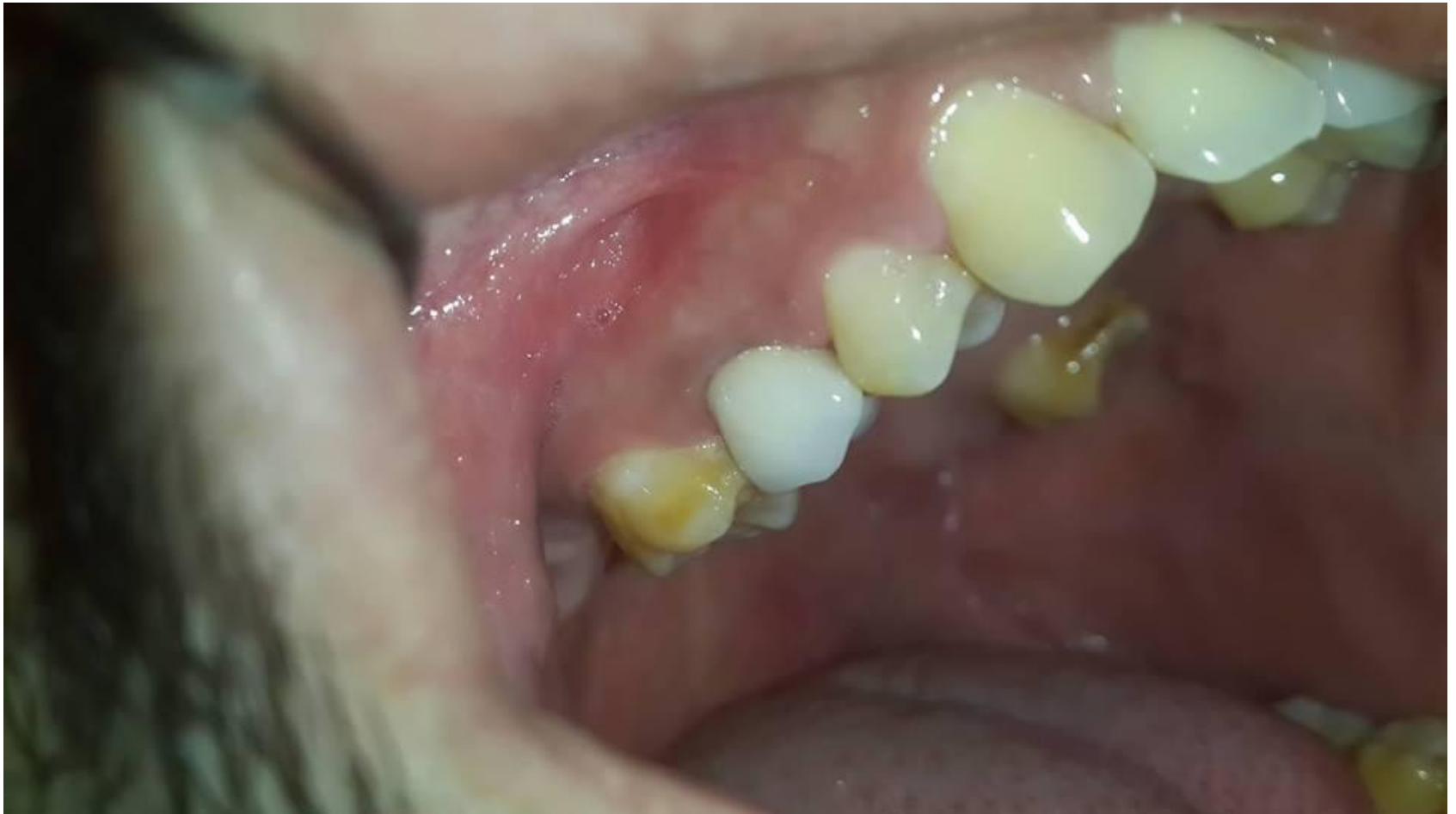Metal try of PFM crown- occlusal adjustment



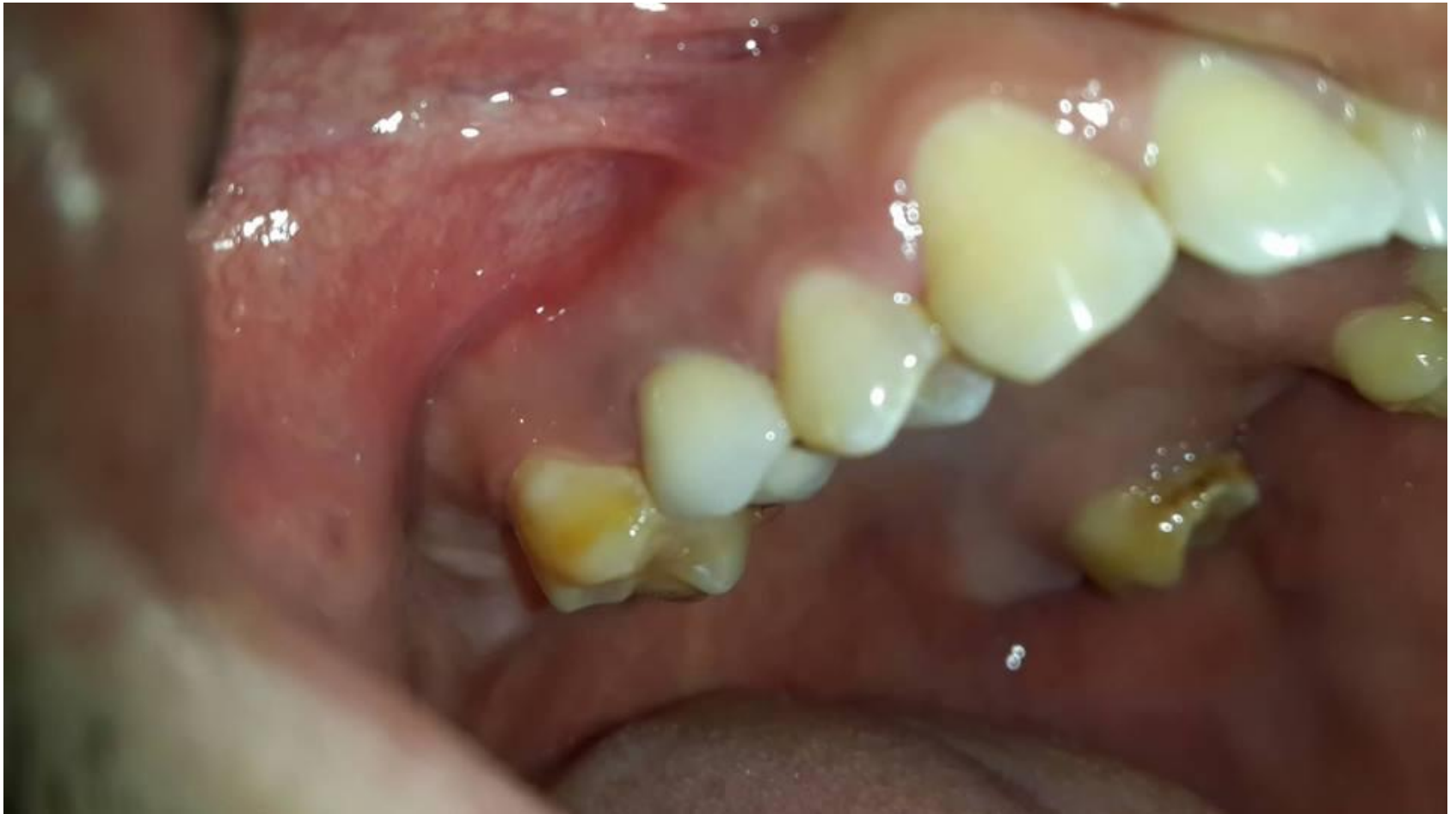Shade selection



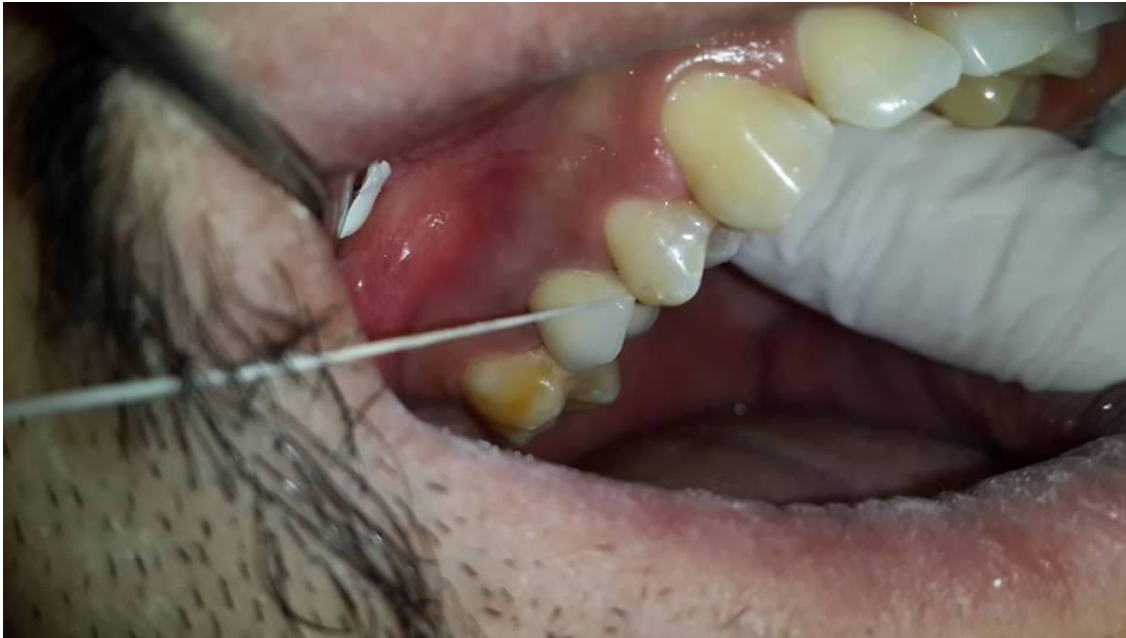
PFM before shade adjustment



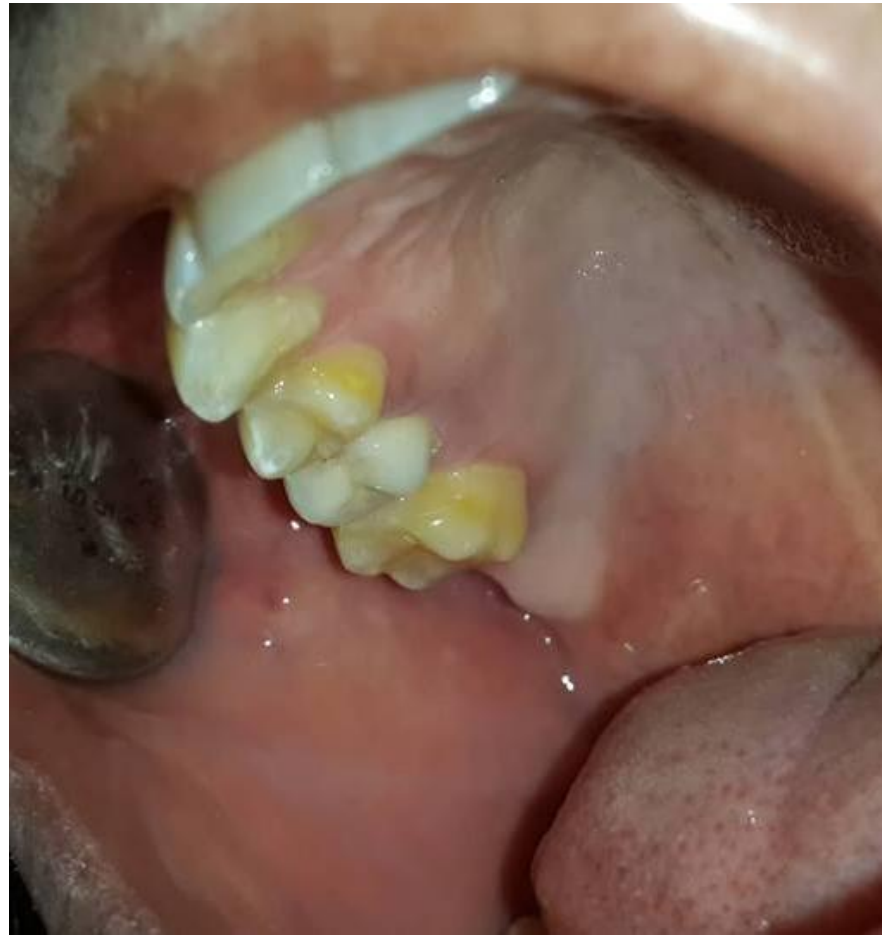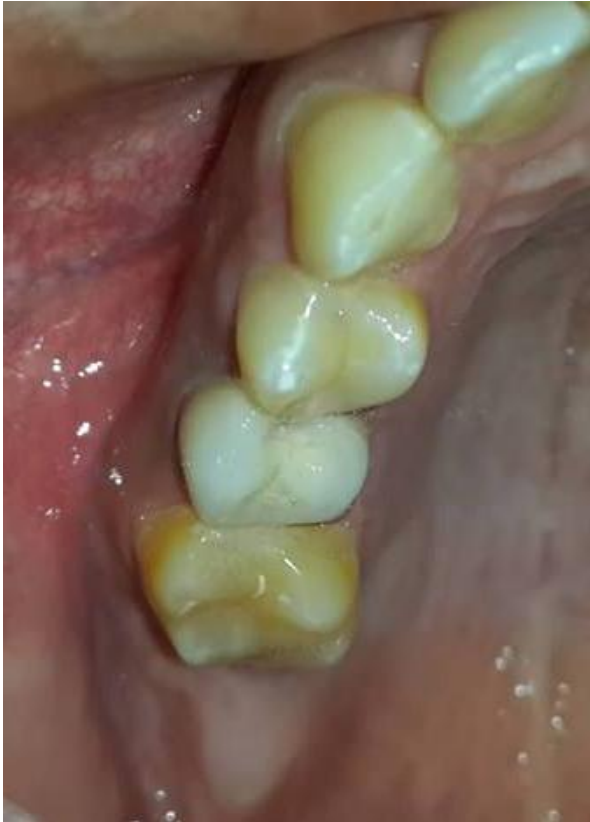Temporary cementation



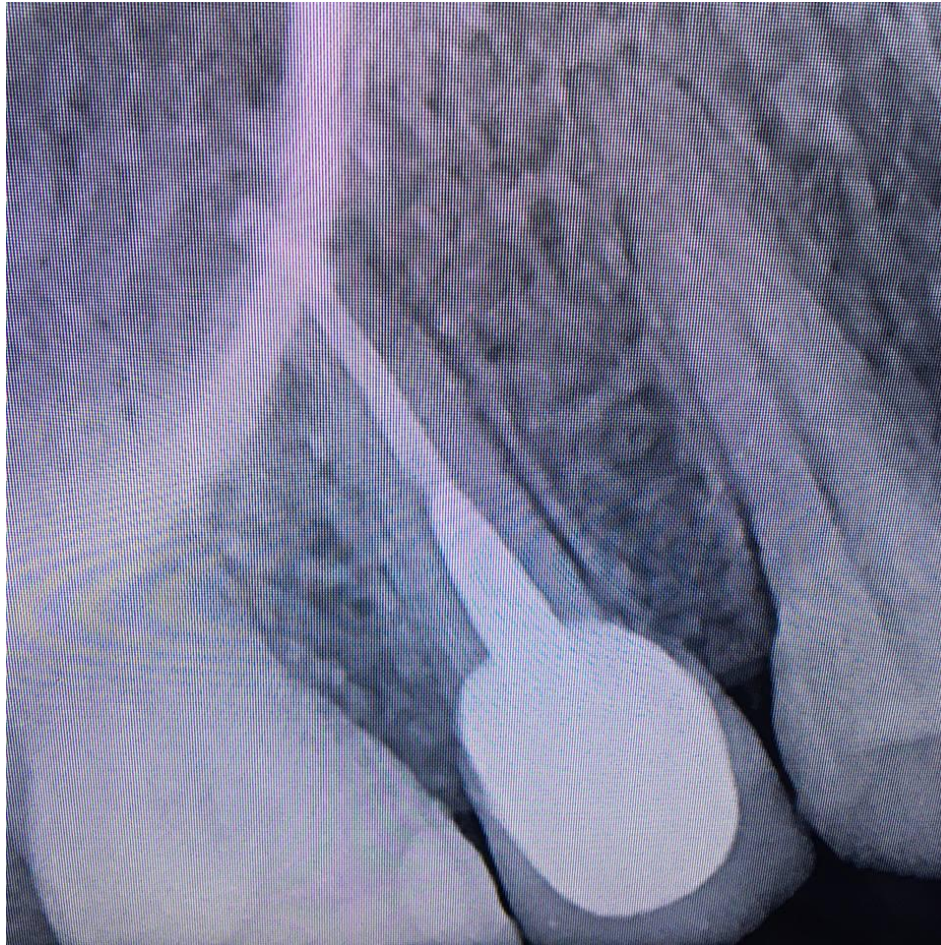
Final cementation



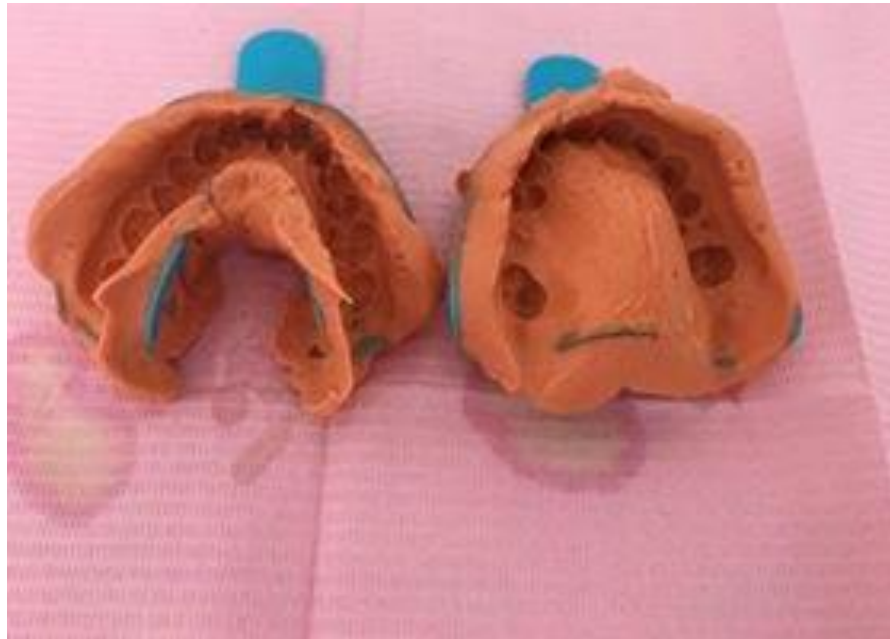
Final cementation



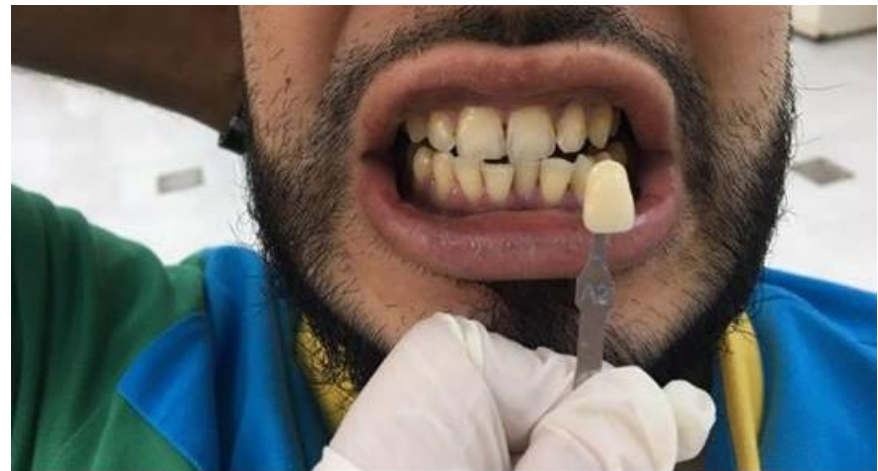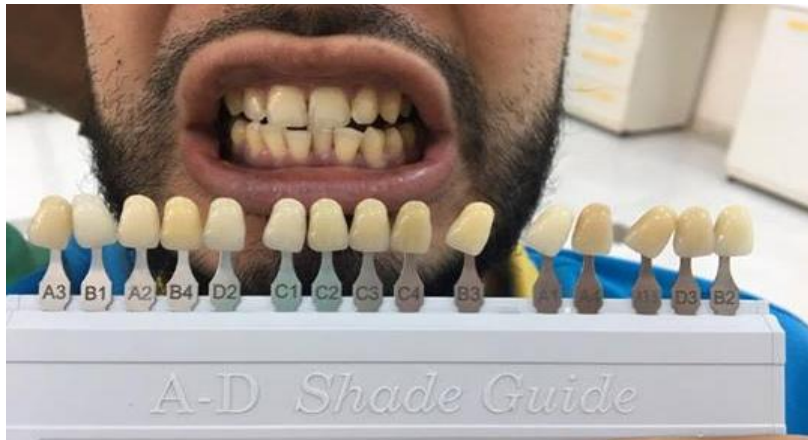Recall after one week



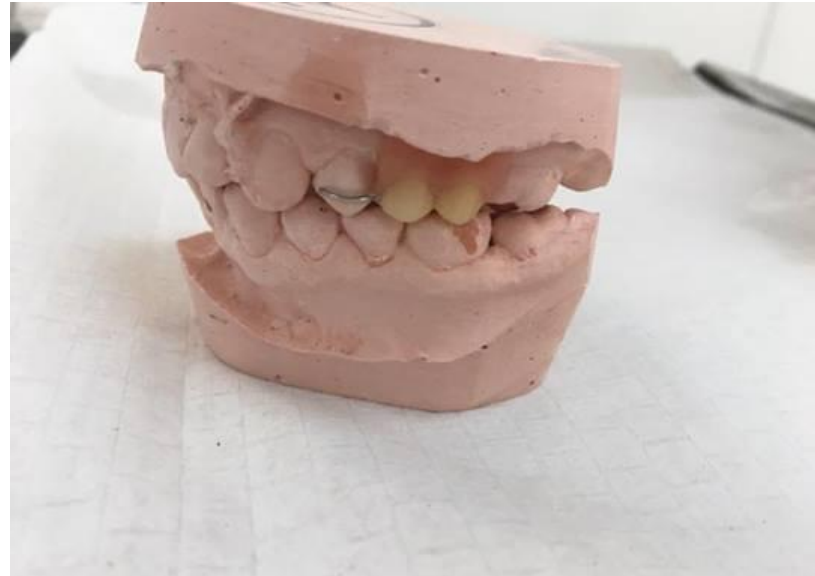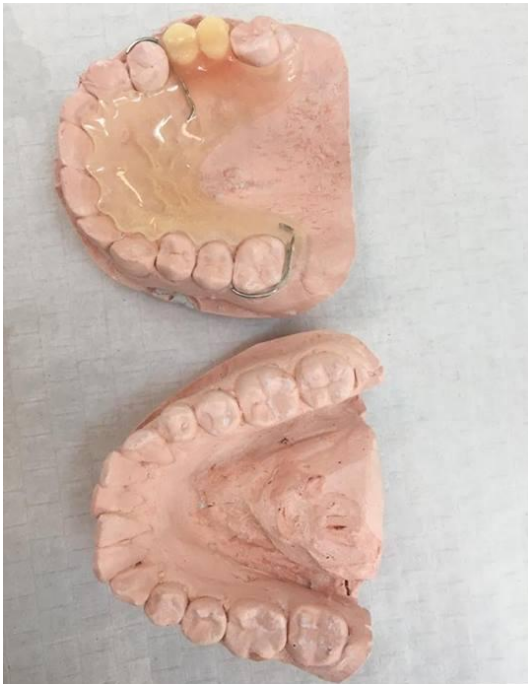Phase III – RPD – primary impression



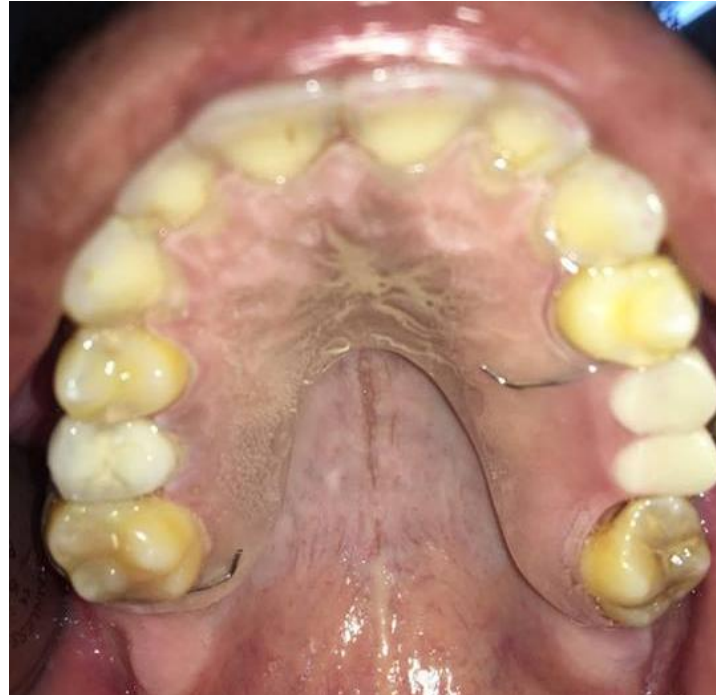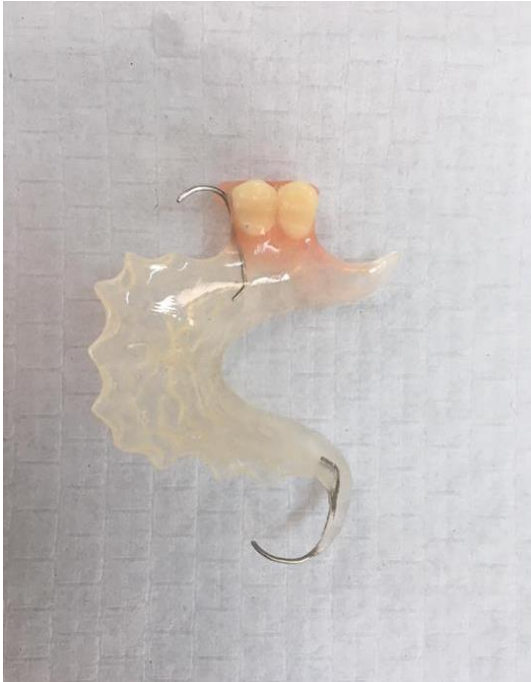Shade selection



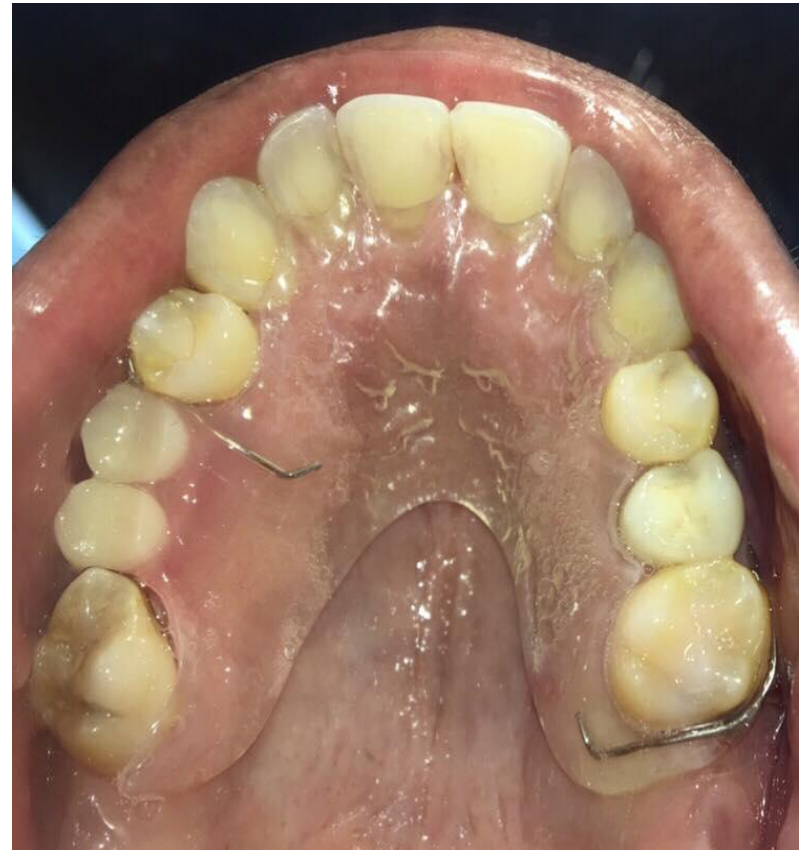
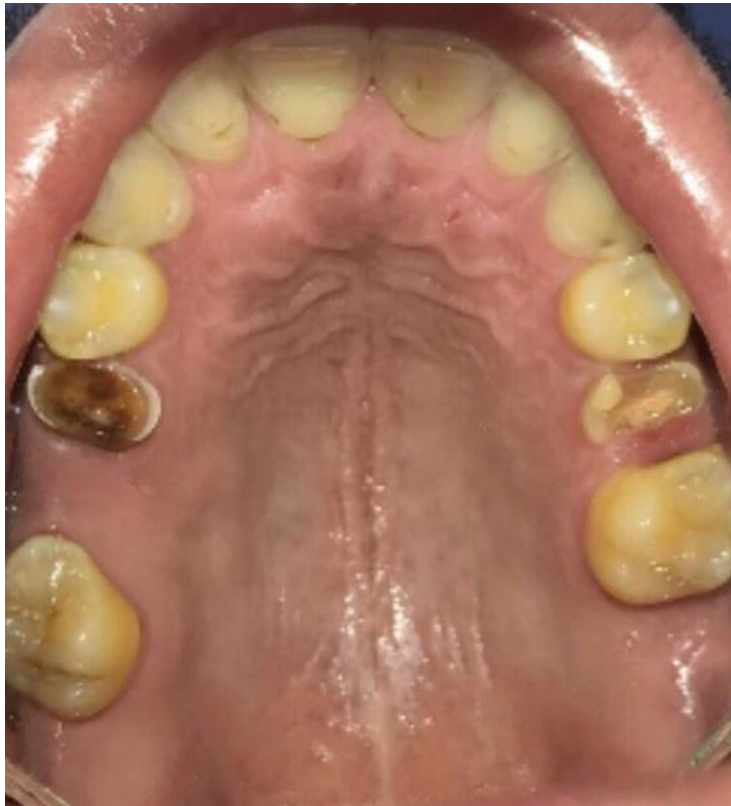Insertion



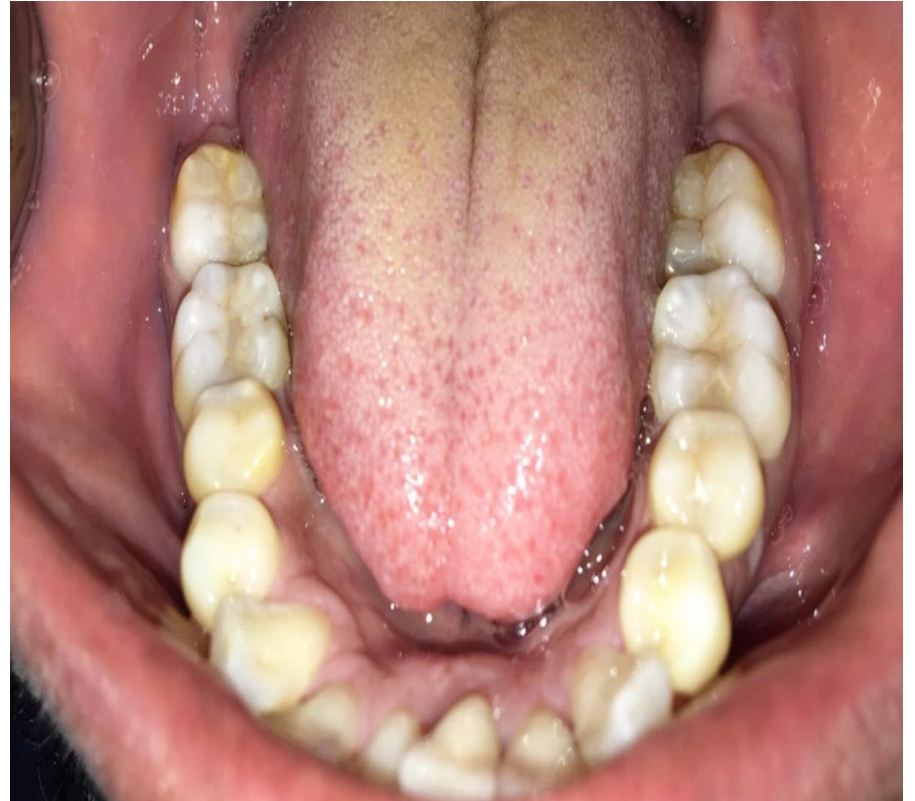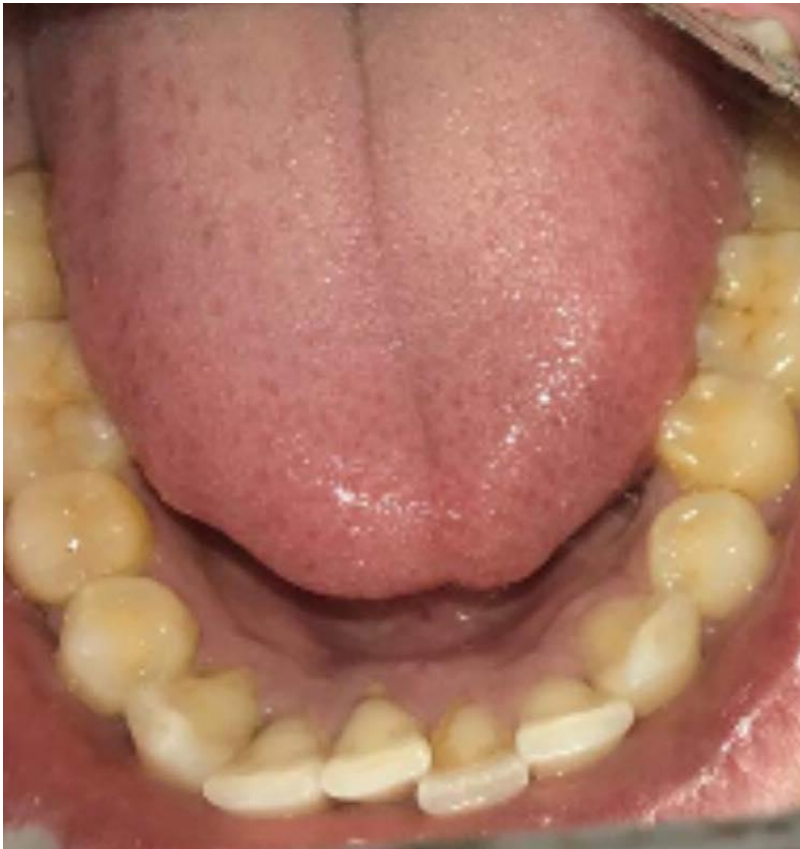Insertion



Before & After



Before & After





Thank
you