



Libyan International Medical University



Comprehensive Case Presentation

Presented By Aisha Bader

Roll no. : 915

This work was achieved by the student [Aisha Bader](#), under the supervision of the dental teaching staff at [Libyan International Medical University](#):

- ❖ **Dr. Rafik Alkuafi**
- ❖ **Dr. Abdelmonem Abdelnabi**
- ❖ **Dr. Nada Kashbur**
- ❖ **Dr. Asma Al-Howati**
- ❖ **Dr. Ali Busnaina**
- ❖ **Dr. Omar Alhouni**
- ❖ **Dr. Amal Alawami**

Patient Information

- ▶ **Name: N.H.A.**
- ▶ **D.O.B.: 13/10/1986**
- ▶ **Age: 32**
- ▶ **Gender: Female**
- ▶ **Nationality: Libyan**
- ▶ **Occupation: Student**
- ▶ **Address: Al- Salmany**

Chief Complaint

Chief Complaint:

- ▶ **Pain in the upper right side of the jaw that started 2 weeks ago**

History of chief complaint

- **Severe (8/10), throbbing, intermittent, spontaneous pain that lasts for an hour and causes sleep disturbance. The pain is exacerbated by biting, relieved by analgesic (voltaren) that is taken when needed. The patient previously took amoxicillin (1x3x5). The pain is associated with headache and radiates to the right side. There was no history of swelling or previous treatment to the tooth.**

History

Medical history:

- ◆ **No known medical conditions**
- ◆ **No known allergies**
- ◆ **Systematic review revealed no underlying medical conditions**

Drug History:

- ◆ **Voltaren**
- ◆ **Amoxicillin (1x3x5)**

Dental history:

- ◆ **Irregular clinic attender**
- ◆ **H/O multiple extractions without complications**
- ◆ **Last dental visit was 1 year ago for an extraction with no abnormal reaction to L.A. or any other post-extraction complication**
- ◆ **Brushes teeth once a day at most, horizontally, using crest toothpaste w/o flossing**

History

Family History:

- ◆ **No family history of disease**

Social history:

- ◆ **Single**
- ◆ **Lives with parents, brothers, widowed sister and her two children**
- ◆ **Student who is in her final year**
- ◆ **Has never smoked or drunk alcohol or drug abuse**

Examination

▶ Extra-oral examination:

TMJ:

- **No crepitations**
- **No clicking**
- **No tenderness**
- **No dislocation**

Cervical LN's:

- **Not palpable,**
- **Not tender**

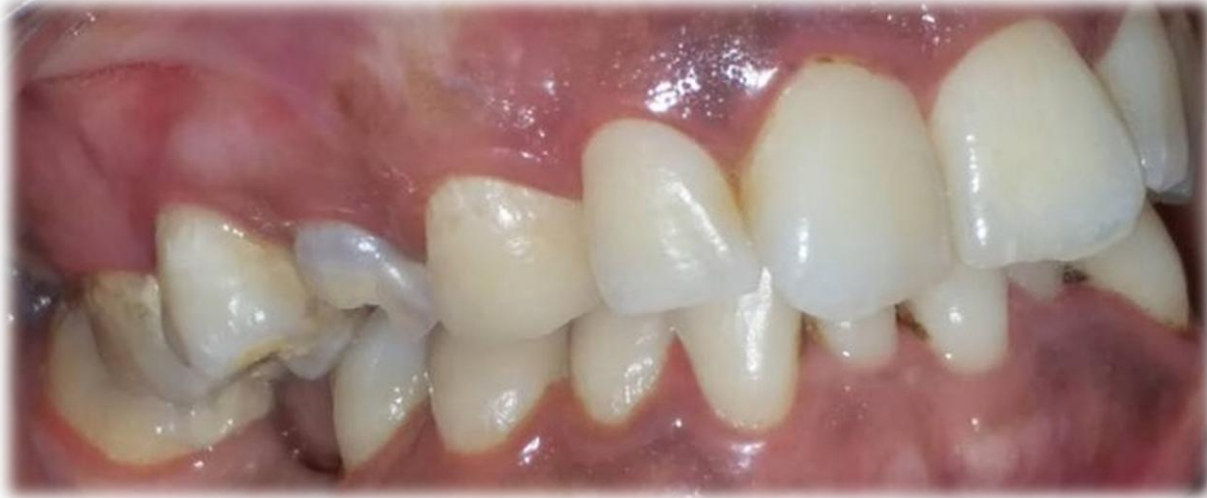Lip seal: **Competent**

Examination

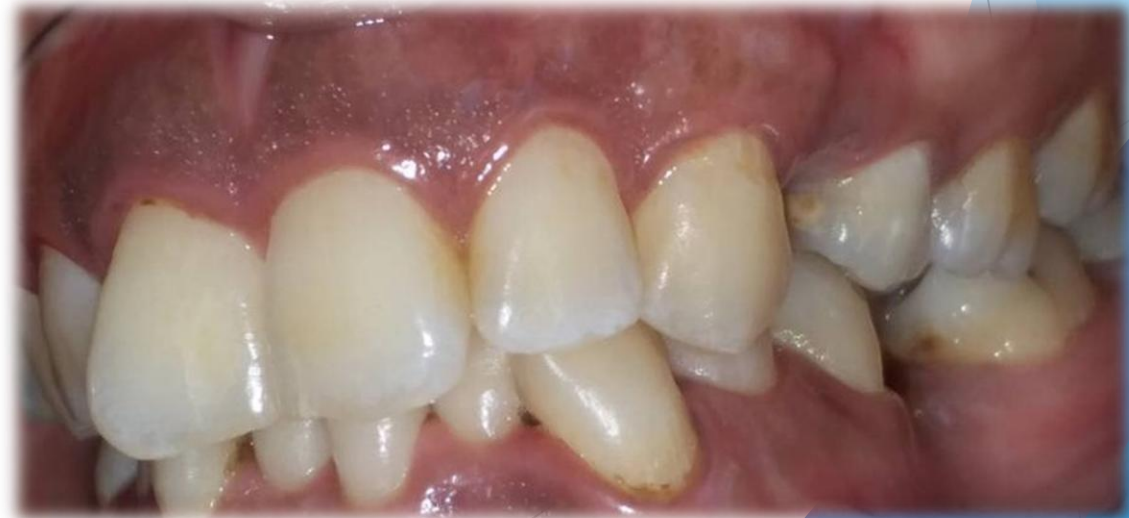Soft tissue examination:

- ▶ **Oral mucosa:** redness of gingiva related to (16) (15) (14)
- ▶ **Palate:** N.A.D
- ▶ **Tongue:** N.A.D
- ▶ **Halitosis:** present 'mild'
- ▶ **Ulcer:** Absent

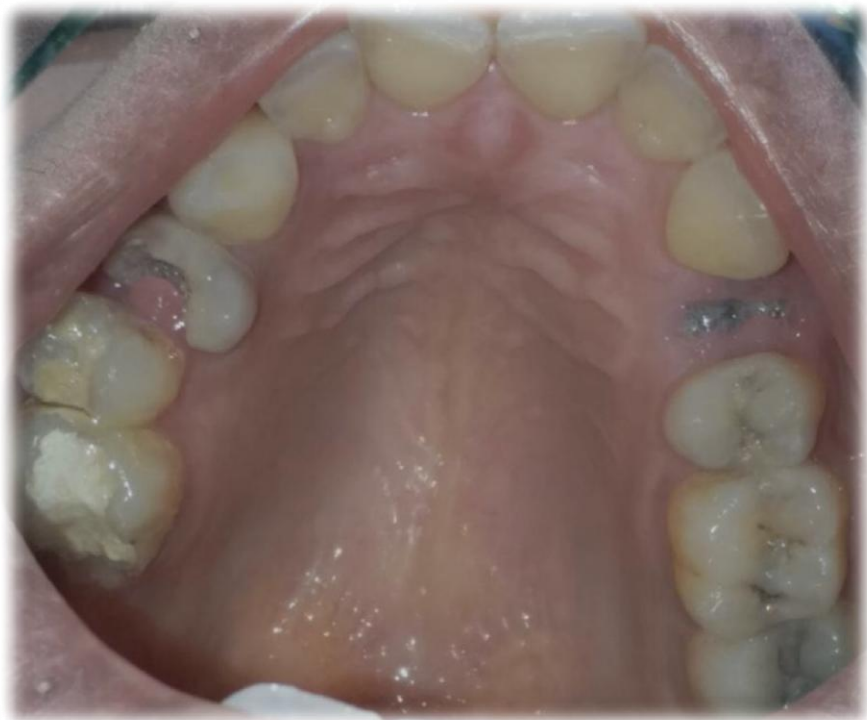Intra-oral photographs



Right Side

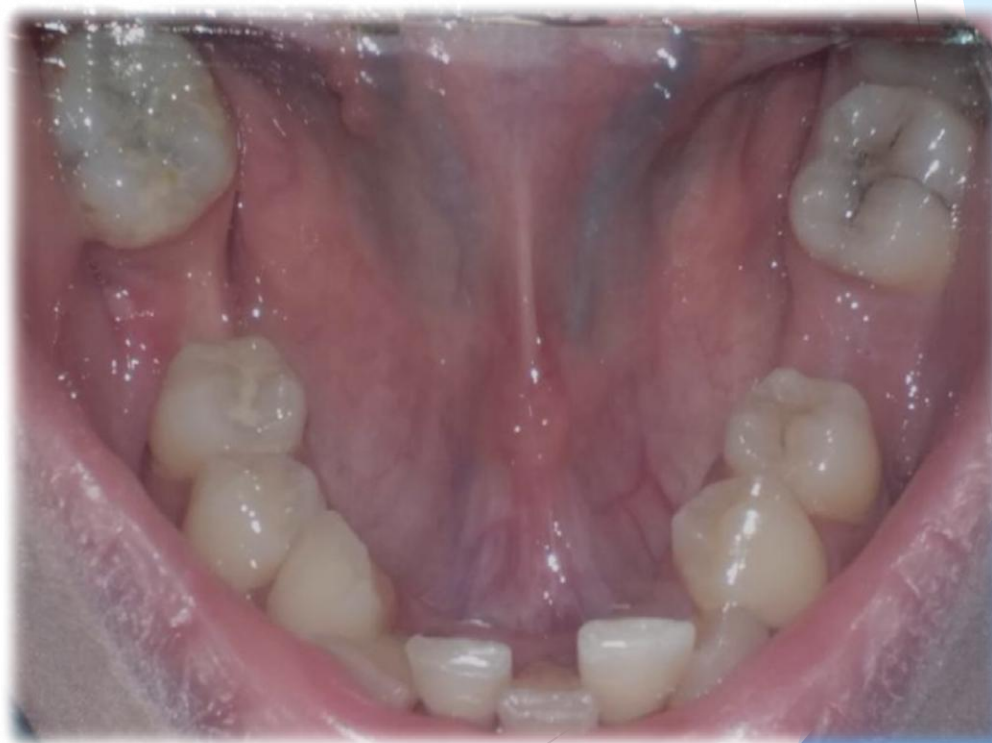

Left Side



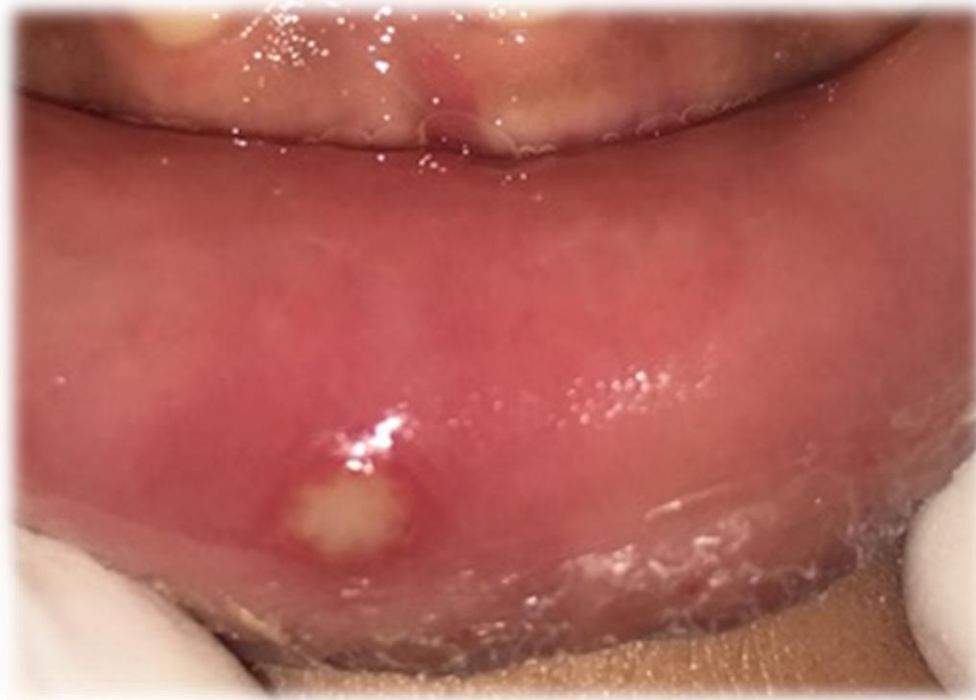Upper Arch

Lower Arch



Ulcer

- ▶ **Chief Complaint: Patient came to the clinic complaining of a history of oral ulceration**



Investigations

▶ The following investigations were requested:

- 1) **CBC**
- 2) **Serrum Ferritin**
- 3) **Serum Folate**
- 4) **Serum B12**
- 5) **ESR**
- 6) **CRP**
- 7) **U&E**

Treatment:

- ▶ **Start taking Vitamin C and multi-vitamin supplements**
- ▶ **Betamethasone 500mg (4x1x7) to be dissolved (10ml) in water used as mouthwash (3-4 mins)**

Follow up



الجامعة الليبية الدولية للعلوم الطبية
Libyan International Medical University



كلية طب وجراحة الفم والأسنان
Faculty of dentistry

Medical Consultation

Patient Name: Na [REDACTED]
File No:.....

Age: 32 Gender: F
Date:.....

REASON FOR CONSULTATION:

Dear Dr.

Ms. Nada is a 32-year-old female Libyan patient who is seen in the Oral Medicine department at LIMU Dental Clinic for routine dental treatment. Ms. Nada is also suffering from oral recurrent aphthous ulcers that started 4 years ago. She is receiving treatment for her ulcers by an Oral Medicine specialist. However, her ulcers became more severe recently. Ms. Nada has provided us a history of an irregular menstrual cycle. Moreover, she has undergone haematology investigations showing iron deficiency anaemia. Both conditions are well known conditions that affect oral ulcers.

Therefore, we would be happy if you could see her regarding her anaemia and period. Meanwhile, we will continue following her in the dental clinic.

Kind regards,

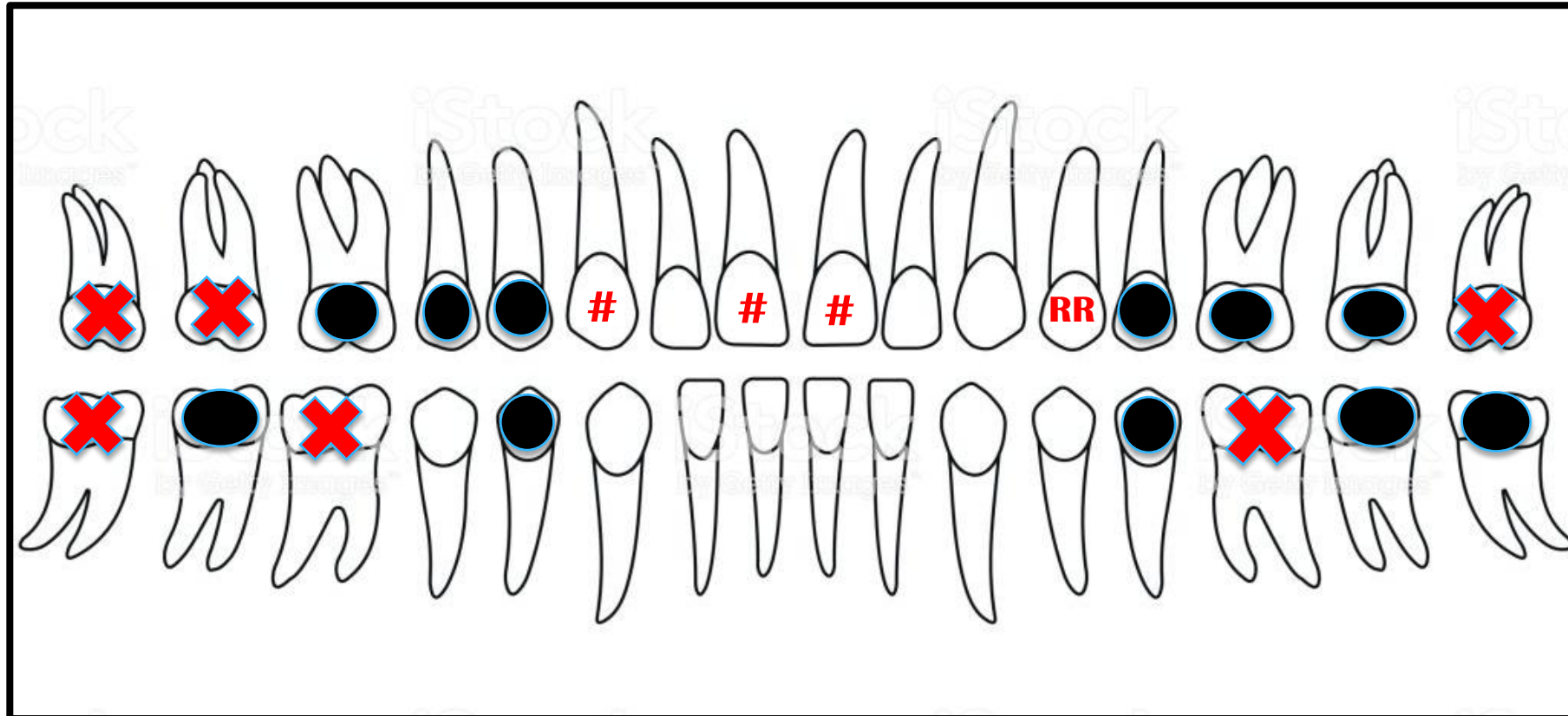
Aisha Bader

STAFF NAME: DR Asma El Howati

STAFF SIGNATURE: 

- ▶ **After having examined blood tests, the patient was referred to a physician for iron deficiency anemia and irregular menstrual cycle**

Hard Tissue Examination



● = Decayed

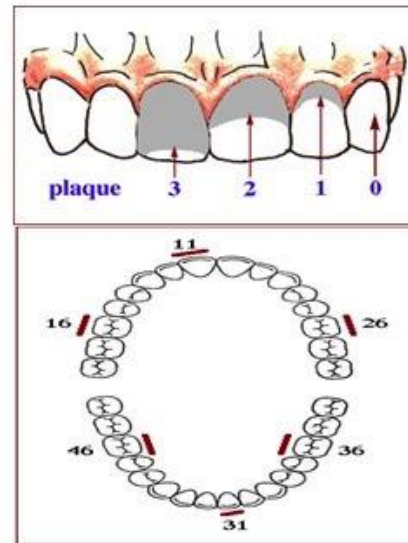
✗ = Missing

= Fractured

RR = Remaining root

Oral Hygiene Index Simplified:

16	11	26
1	0	1
1	0	1
46	31	36



16	11	26
2	1	1
3	1	1
46	31	36

Plaque Index = $\frac{4}{6} = \dots 0.67$

Calculus Index = $\frac{9}{6} = \dots 1.5$

OHI-S = $0.67 + 1.5 = 2.17$

Good (0-1.2),

Fair (1.3-3),

Poor (3.1-6)

Gingival Status

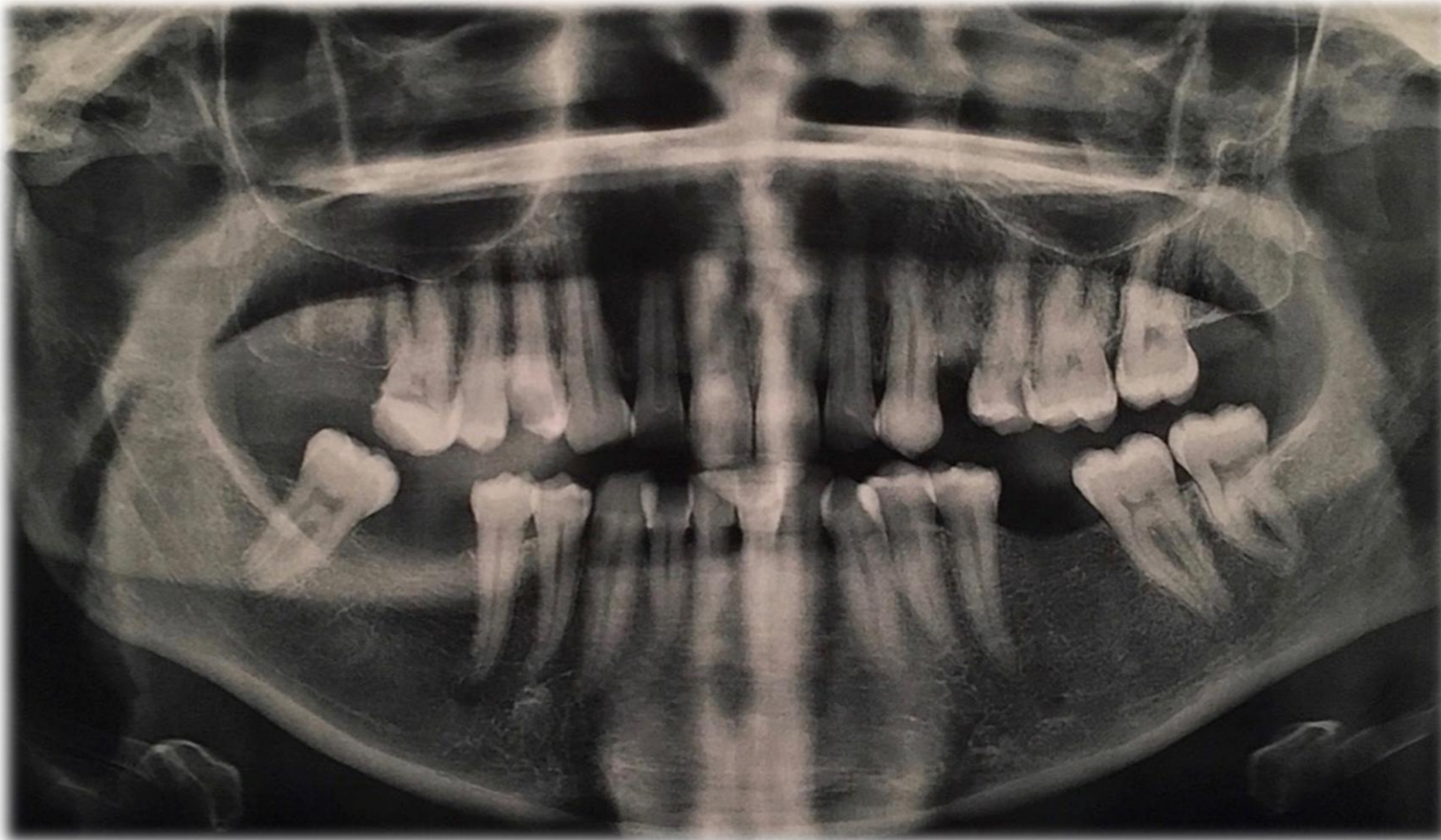
- ▶ **Colour:** Reddish-pink with melanin pigmentation
- ▶ **Contour:** Round margin, blunt IDP
- ▶ **Size:** Normal
- ▶ **Consistency:** Firm
- ▶ **Stippling:** Present in upper anterior area
- ▶ **Position:** Coronal to CEJ
- ▶ **Bleeding on probing:** Present
- ▶ **Exudation:** Absent

Differential diagnosis of Chief complaint:

- 1) **Acute exacerbation of chronic periapical periodontitis (16)**
- 2) **Acute periapical periodontitis (16)**

Investigations:

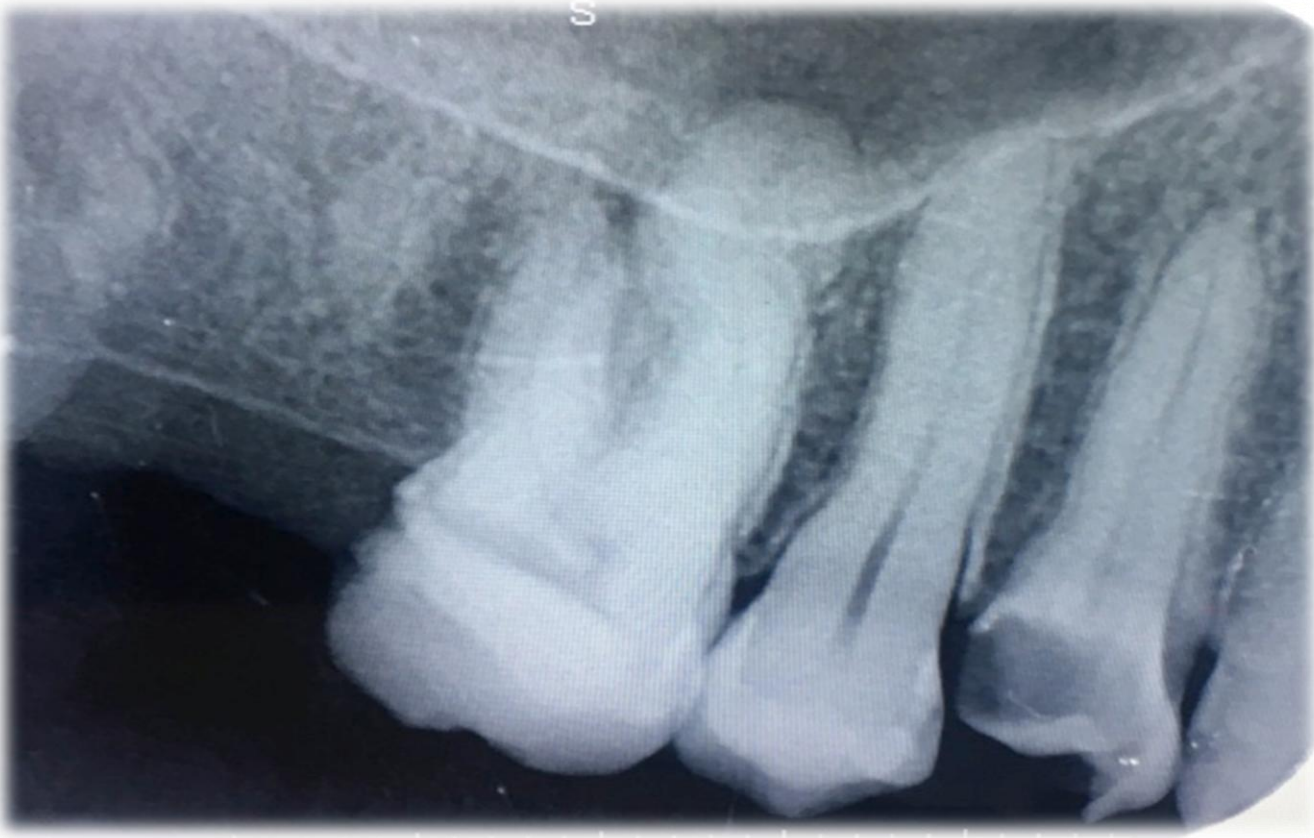- 1) **Intra-oral periapical radiograph (IOPA)**
- 2) **Orthopantomogram (OPG)**



OPG showing:

- **Maxillary and mandibular teeth with generalised mild bone loss**
- **Radiopacity related to (16) indicating the presence of temporary restoration**
- **Remaining root (24)**
- **Radiolucency related to the coronal portion of (14)**
- **Radiolucency related to the distal aspect of (25)**
- **Roots left in-situ (17)**
- **Missing teeth (36) (46)**

Intra-oral periapical



- **IOPA showing (14) (15) (16)**
- **(16) shows a large radiopacity (temporary restoration) in the distal aspect of the coronal portion of the tooth and periapical radiolucency related to the palatal root.**
- **NB: IOPA shows remaining roots of (17) which are asymptomatic and covered by approx. 3-4mm of bone, therefore, they will be left in situ.**

Final Diagnosis:

- 1) **Acute exacerbation of chronic periapical periodontitis (16)**
- 2) **Caries (14) (15) (25) (26) (27) (35) (37) (38) (45) (47)**
- 3) **Remaining root (24)**
- 4) **Fractured teeth (11) (13) (21)**
- 5) **Generalised mild chronic periodontitis**
- 6) **Kennedy Class III modification 1 (lower arch)**
- 7) **Crowding of lower anterior area**
- 8) **Deep bite**

Treatment plan

▶ **Emergency Phase:**

- **Pulp extirpation (16)**

▶ **Phase I**

- **Patient education and motivation on the importance of plaque control**
- **Diet control**
- **Supra and sub-gingival scaling**

➤ **Re-evaluation of Phase I**

Treatment Plan

▶ Phase II

- **Extraction of remaining root (24)**

▶ Phase III

- **RCT (16) (14) (25)**
- **Restoration (11) (13) (15) (21) (26) (27) (35) (37) (38) (45) (47)**
- **Custom-made cast post&core and PFM crown (14)**
- **Ready-made fiber post and composite core (25)**
- **Ready-made metal post with composite core and PFM crown (16)**
- **Replacement of missing (24) with a PFM bridge**
- **Replacement of missing (36) (46)**

➤ Phase IV- Maintenance and Recall

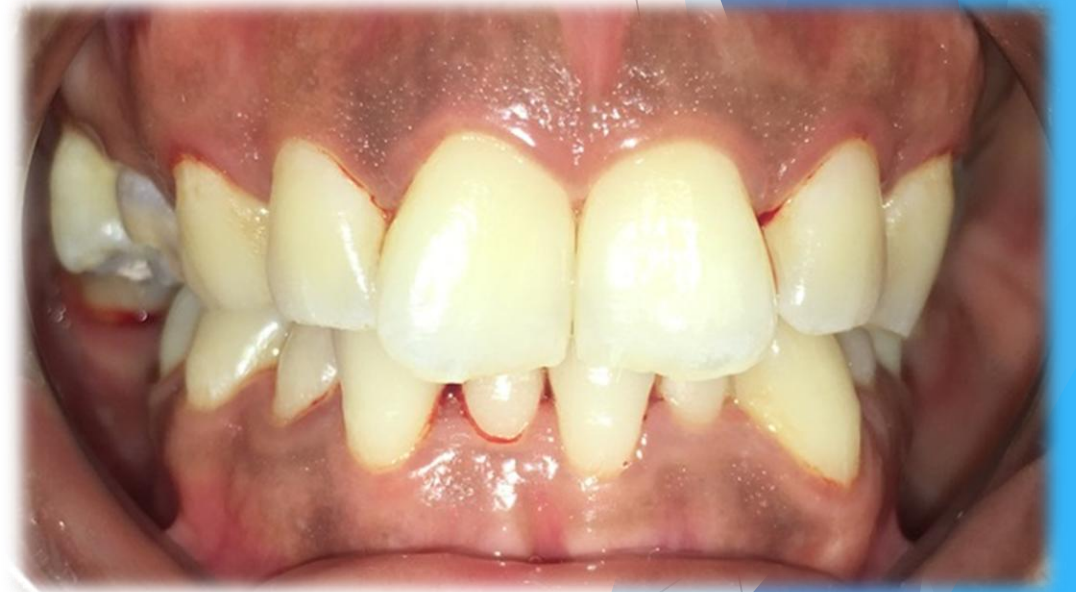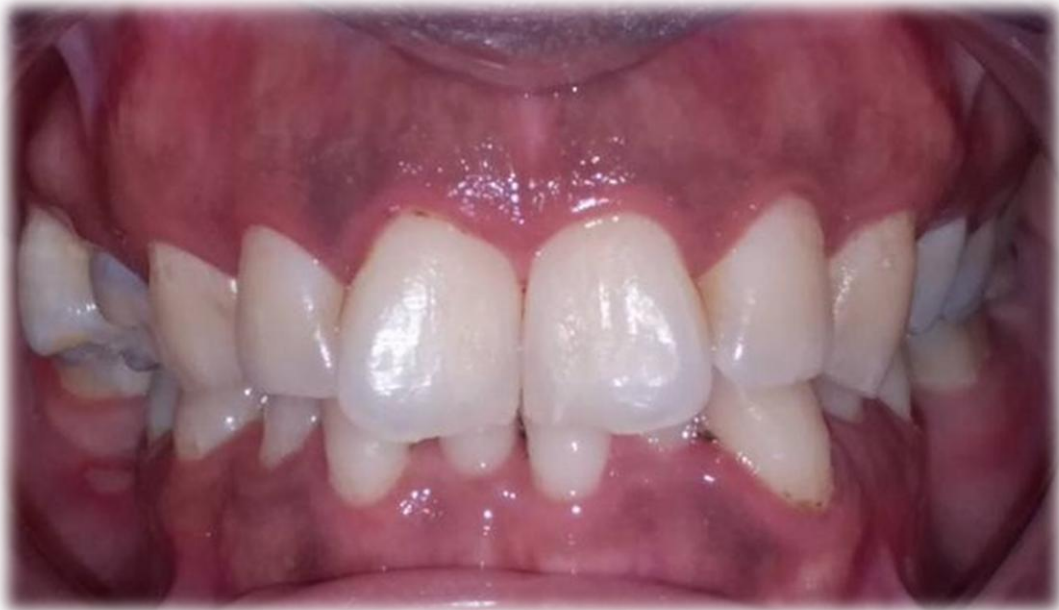- **Periodic recall after 3 months then every 6 months**

Emergency Phase

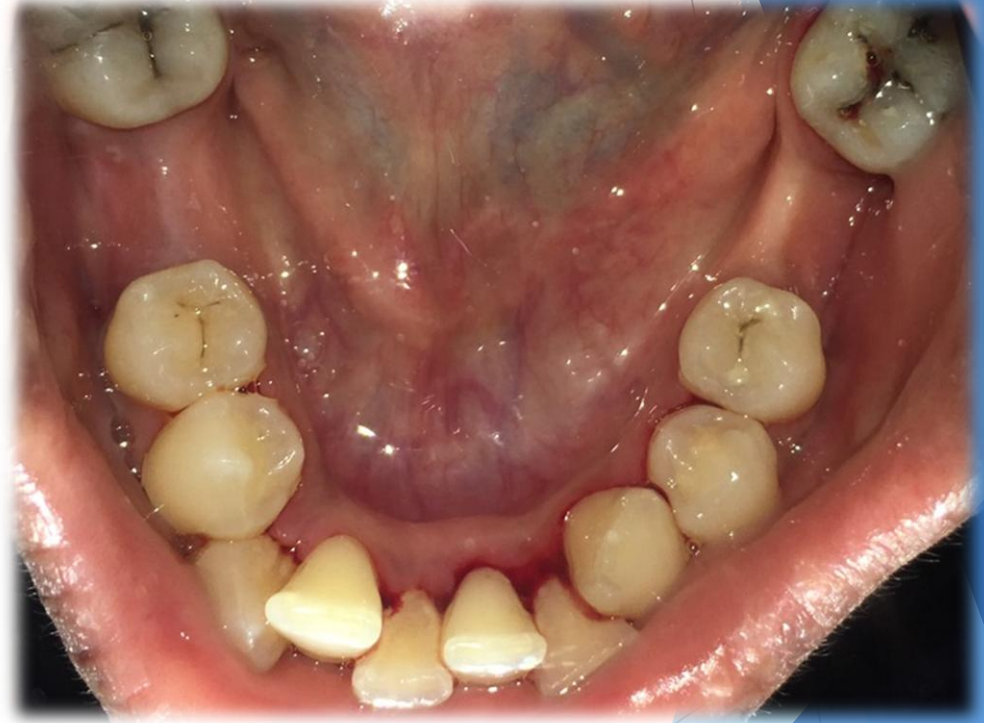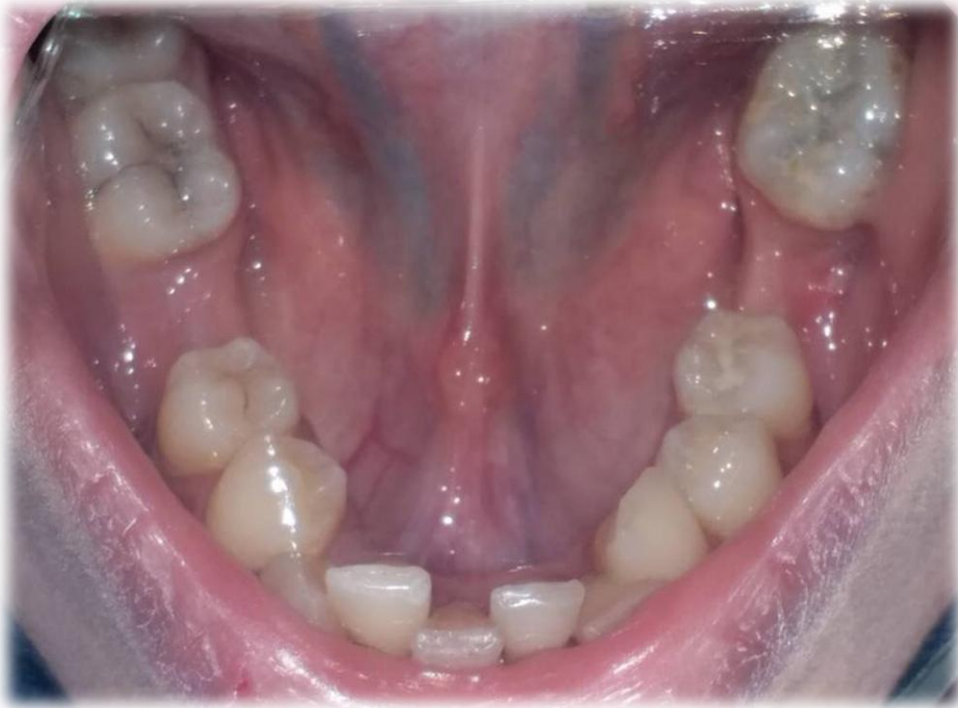- ▶ **Pulp extirpation of (16) was done by an intern**

Phase I Therapy

Supra and Subgingival Scaling



Supra and Subgingival Scaling



Diet Sheet Analysis

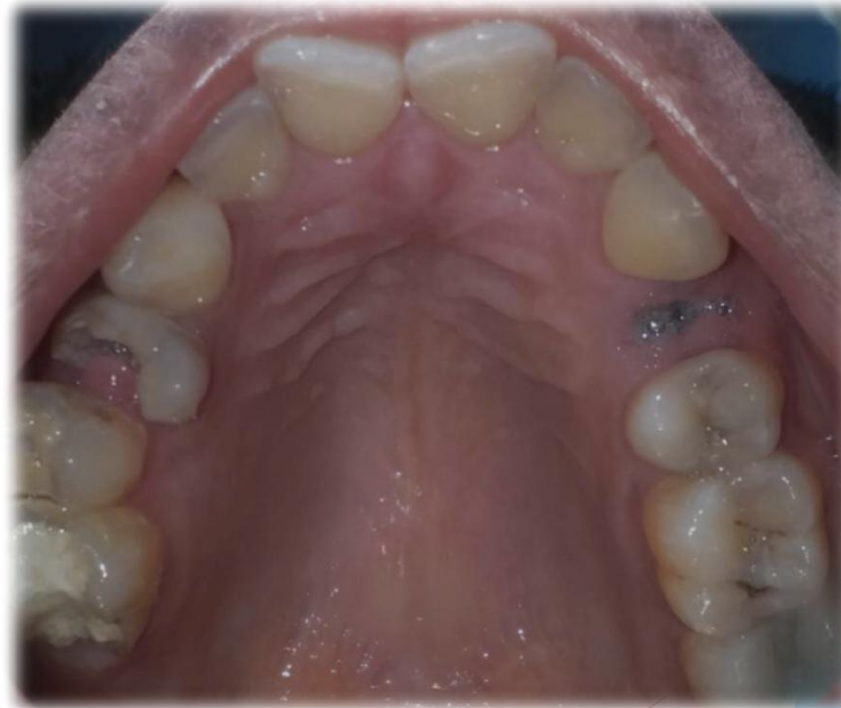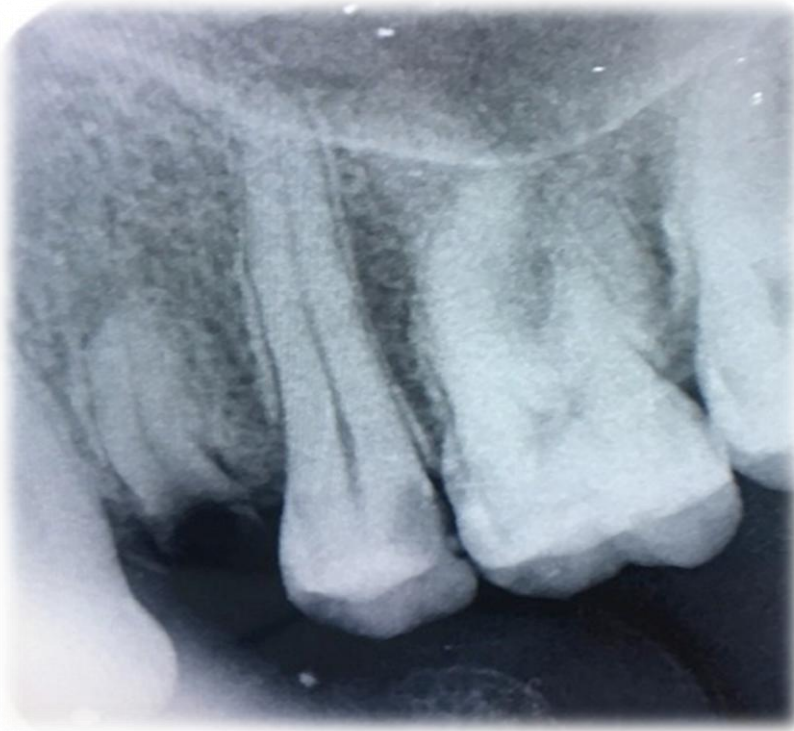نوع الوجبة	المأكولات والمشروبات	الساعة	الأيام
فطور غداء	سندوتش دحي + تفاحة + عصير بامية + رز + بوريك + سلطة + قازوزه	9 ص 3	الخميس
عشاء	قهوة + شوكلاتة سندوتش تن + بيضة مطبوخة	5 10 م	
فطور غداء	حليب + دحي + كيكة	9 ص	الجمعة
عشاء	كسكسو + محشي + سلطة + قازوزه قهوة + كيكة سندوتش كبده + عصير + زبادي	2:30 4 9 م	
فطور غداء	حليب + بريوش مكرونه + شربة خضار + سلطة + قازوزه	8 ص 4	السبت
عشاء	بطاطا مقلية + جبنة + عصير	9:30 م	

Re-evaluation

- ✓ **Patient showed improvement in oral hygiene**
- ✓ **Improved gingival status**
- ✓ **Reduction of pocket depths**

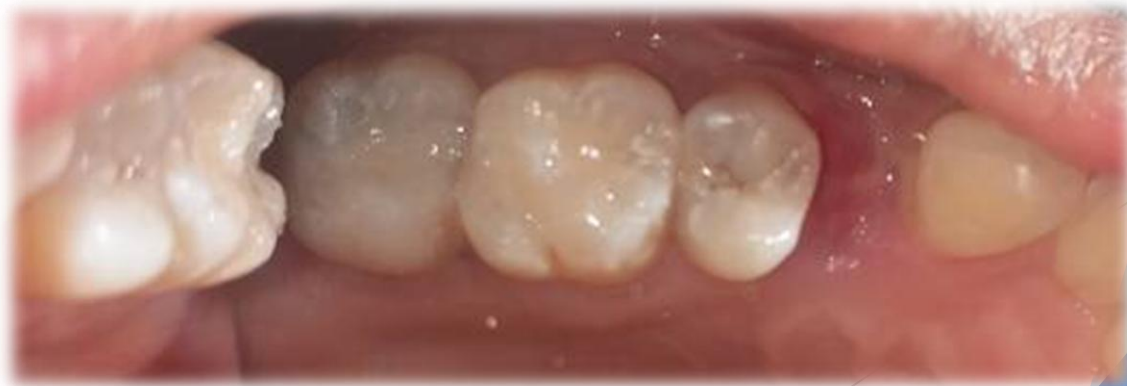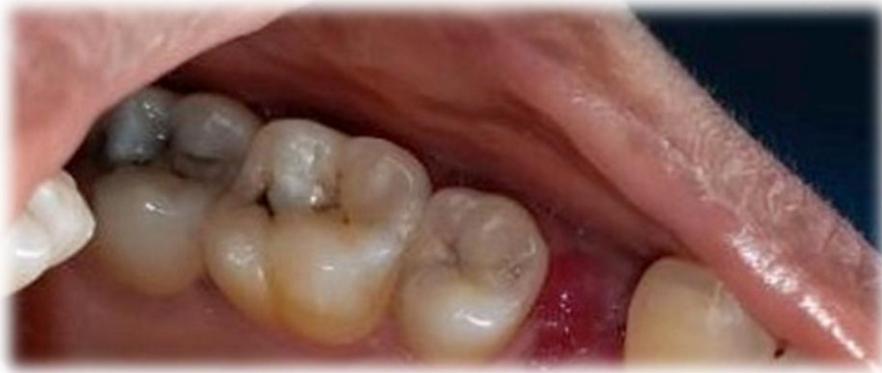Phase II Therapy

Atraumatic extraction of non-restorable remaining root



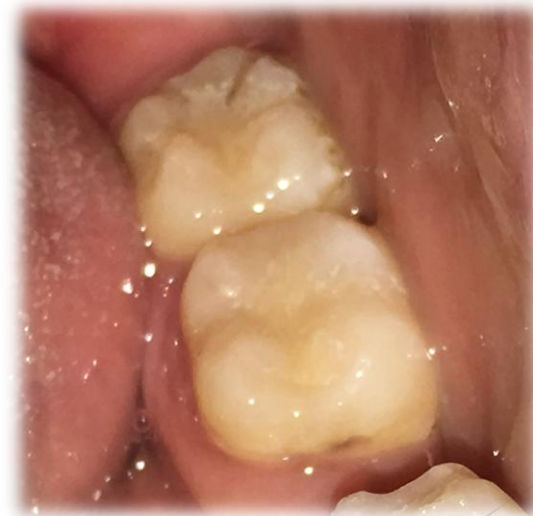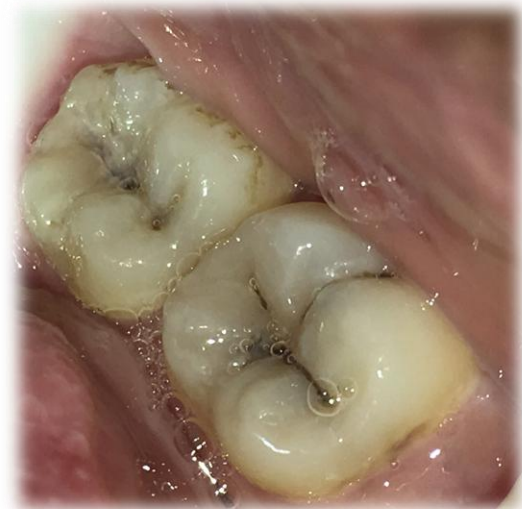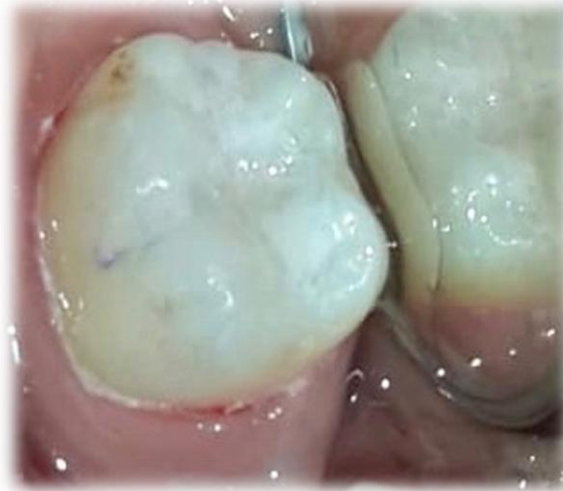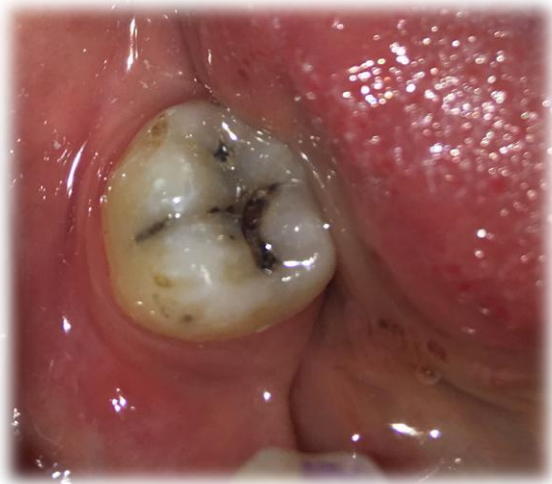Phase III Therapy

Class I cavity (26) (27) restored with occlusal composite (A2)

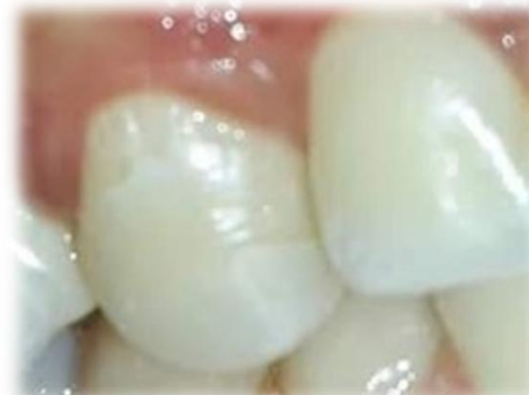
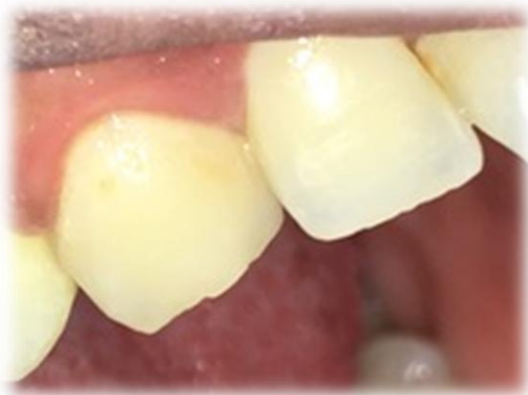
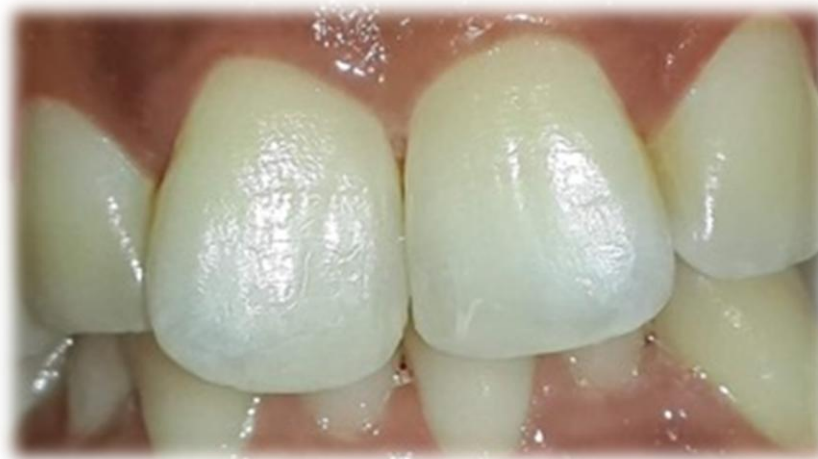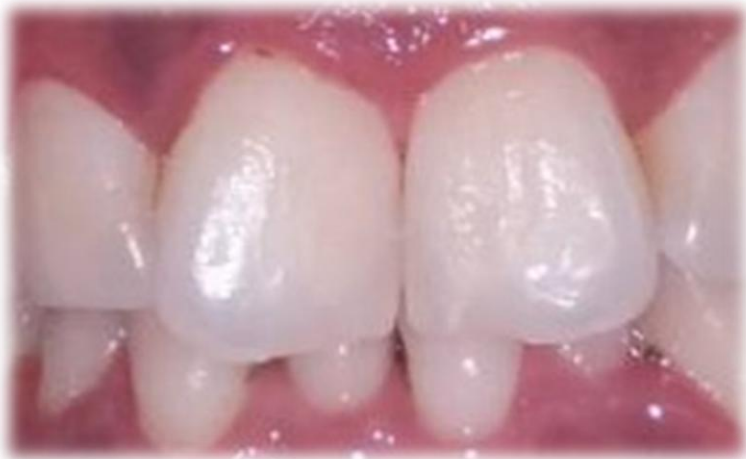Phase III Therapy

Composite restoration of (37) (38) and (47)

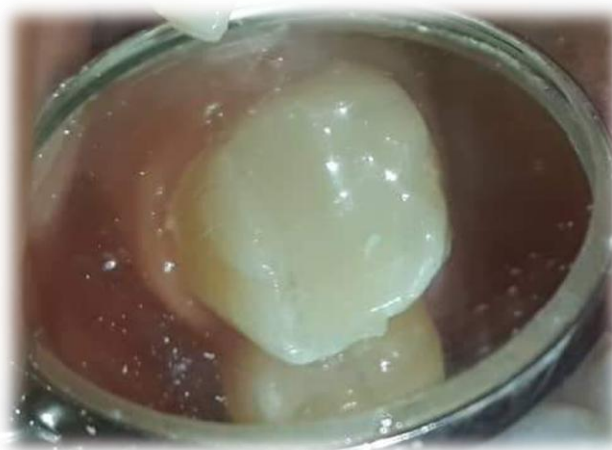
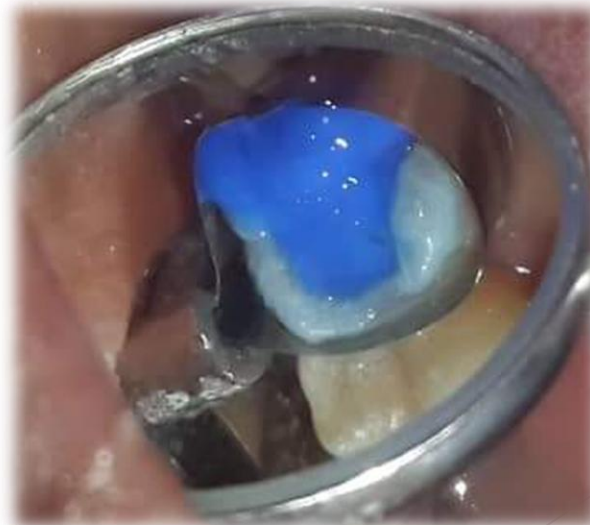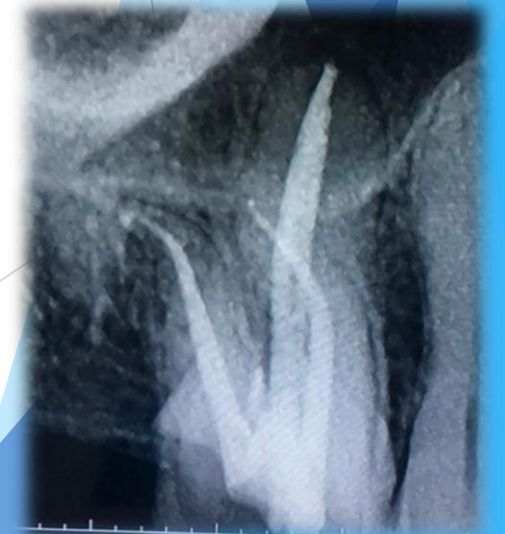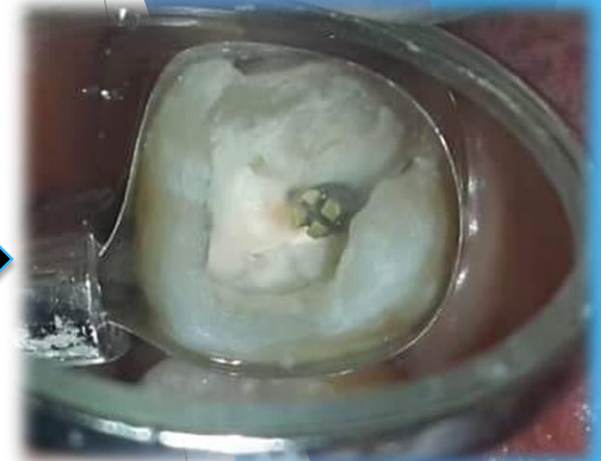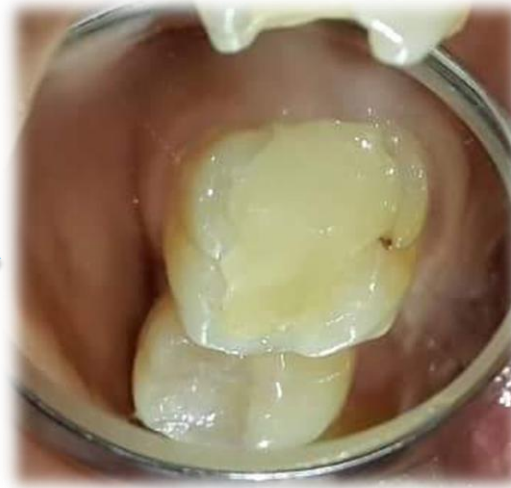


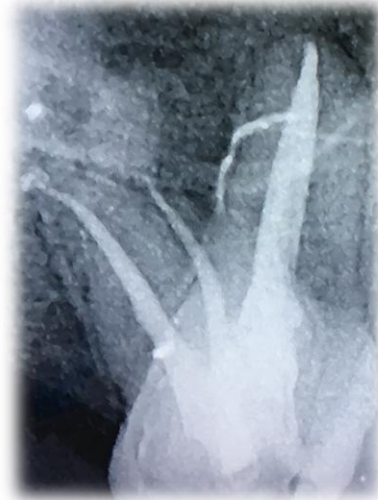Composite Restoration



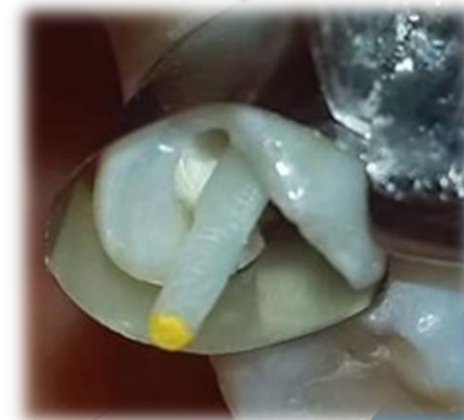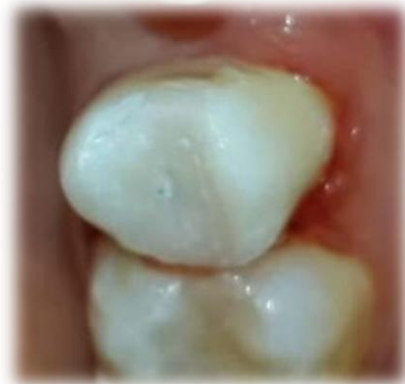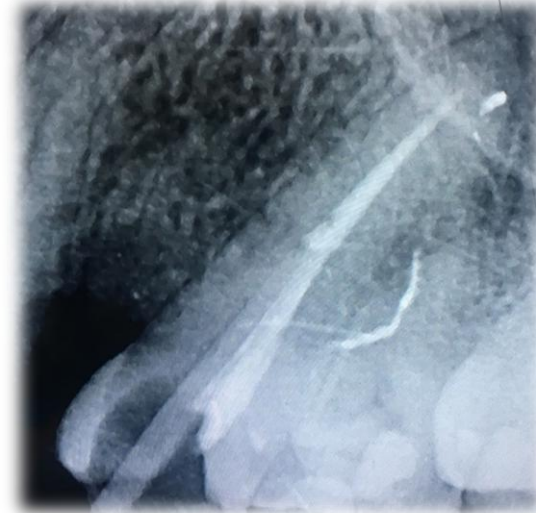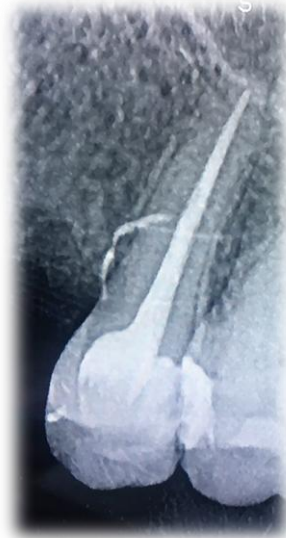RCT and Post&Core

- RCT (16) using Protaper rotary system
- Ready-made metal post and composite core build-up
- Cementation of post using resin cement

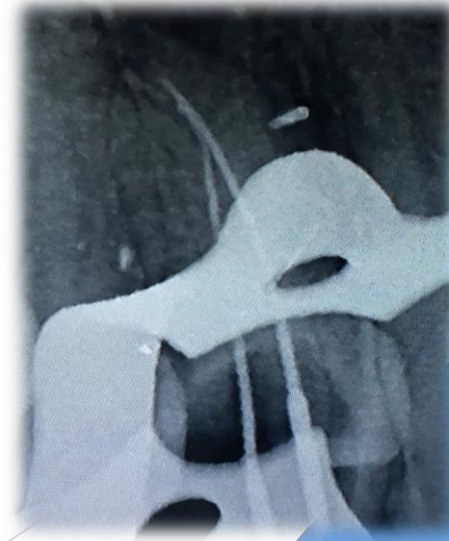
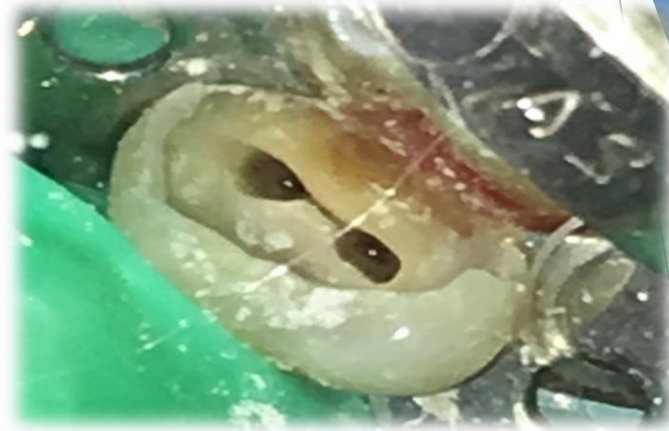
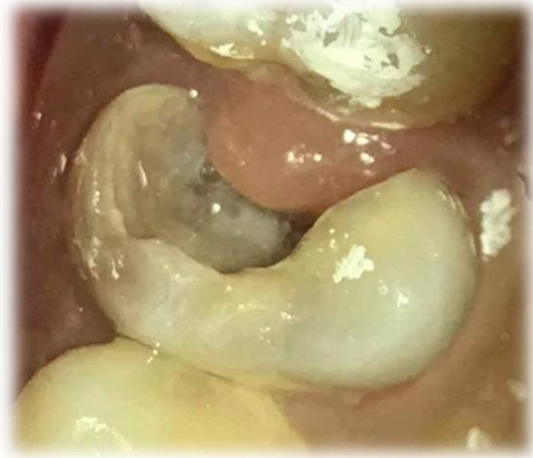


RCT and Post&Core

- **Elective RCT (25)**
- **Fibre post and composite core placement**
- **Cementation of post using resin cement**

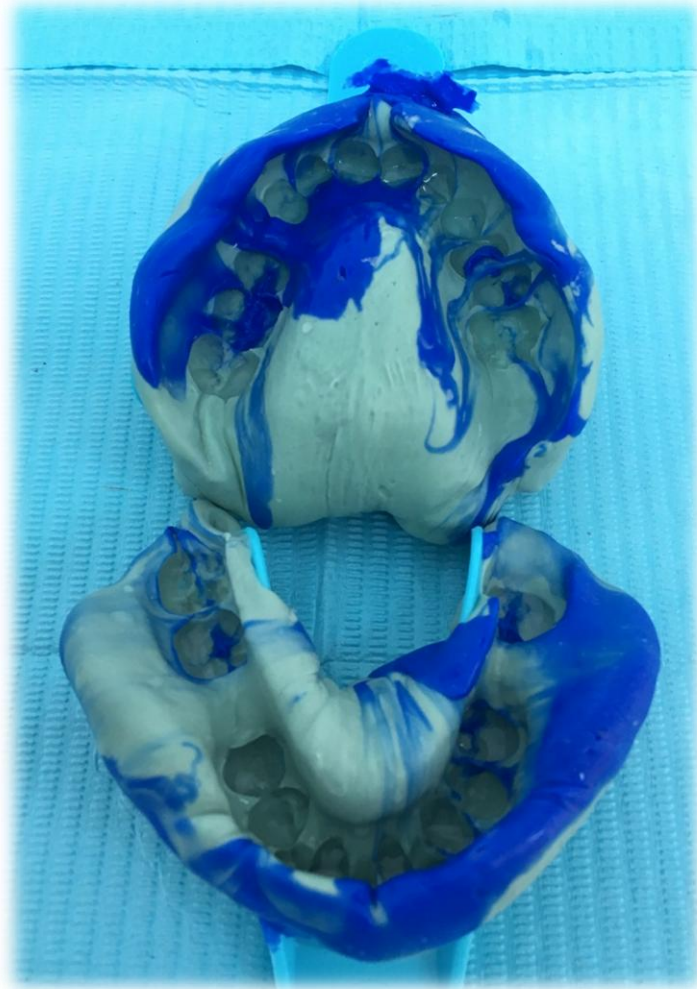


Endodontic treatment

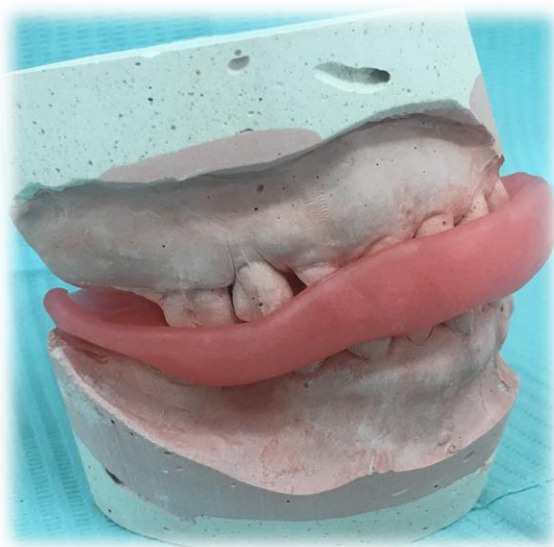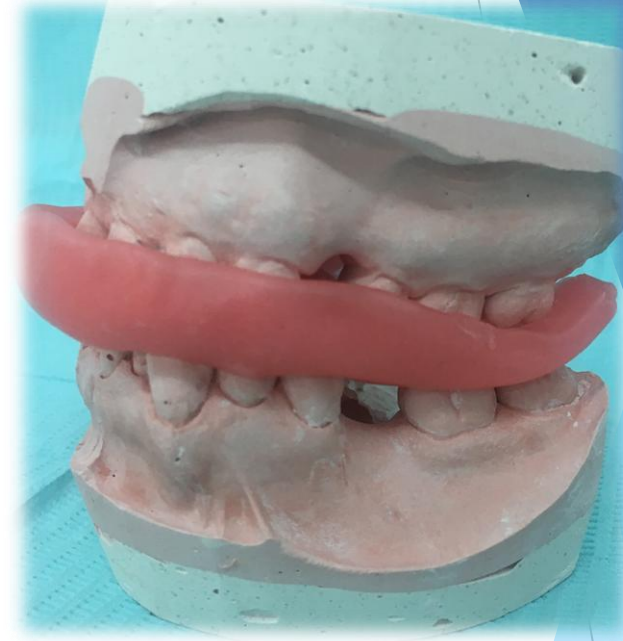

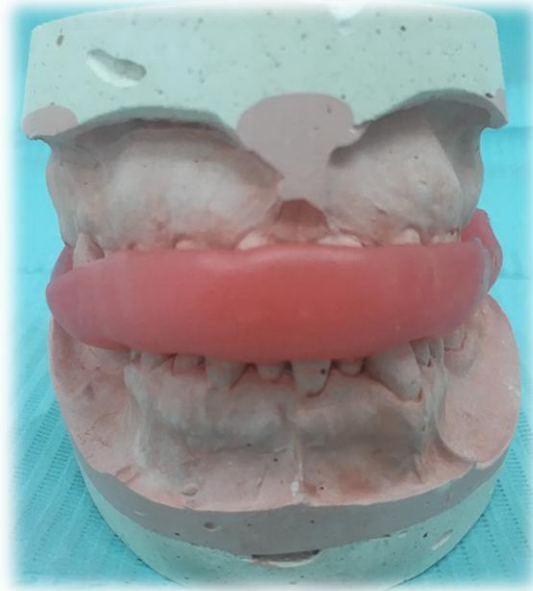
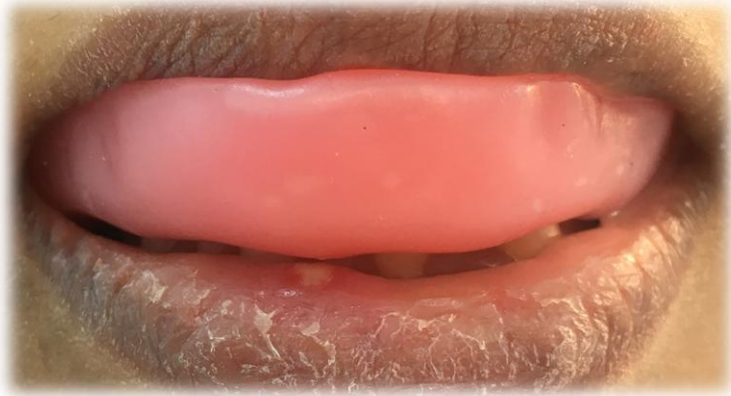Replacement of missing (24)

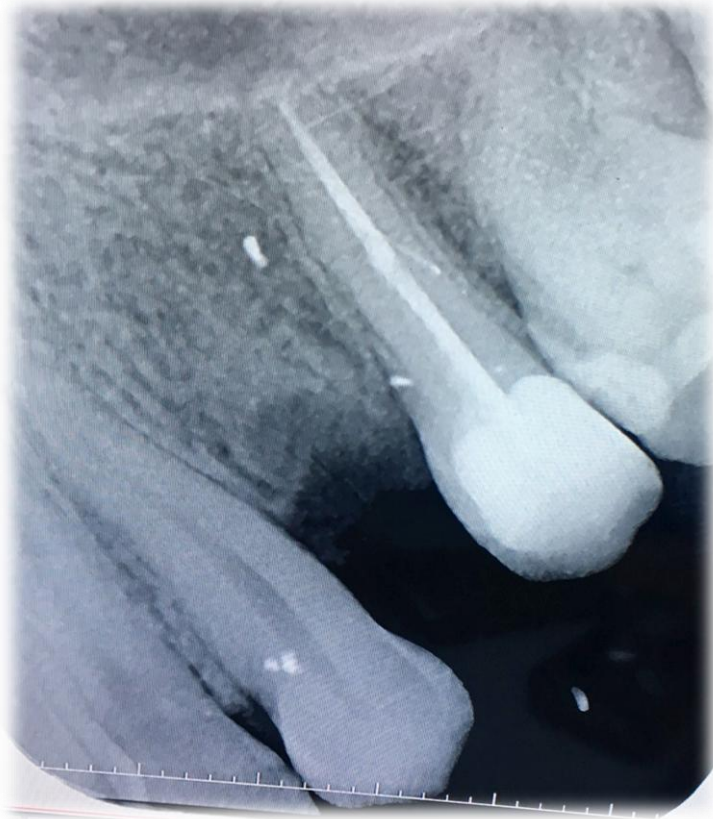
Primary Impression



Bite Registration



Periodontal consultation



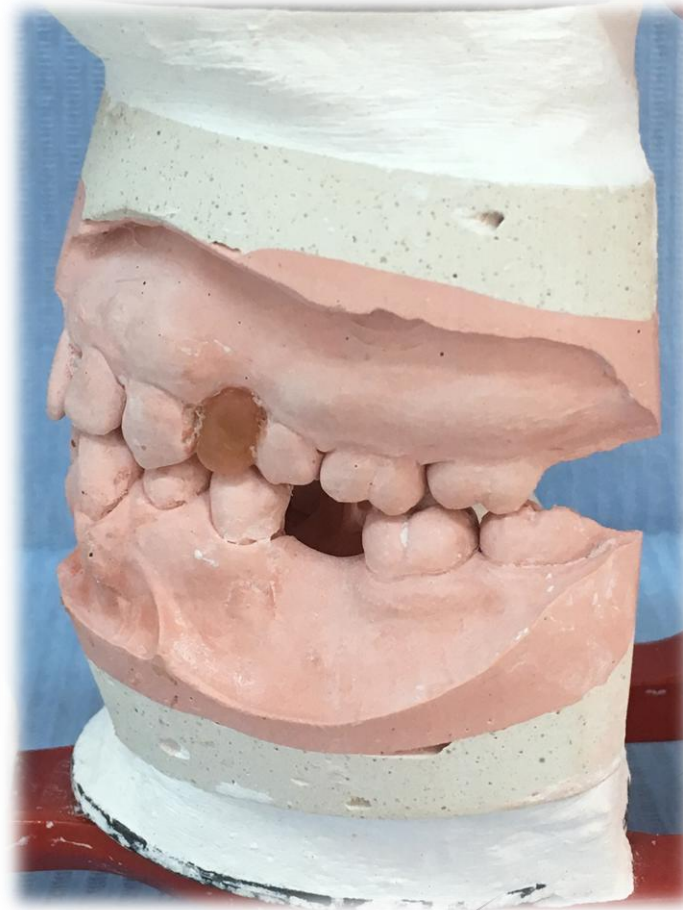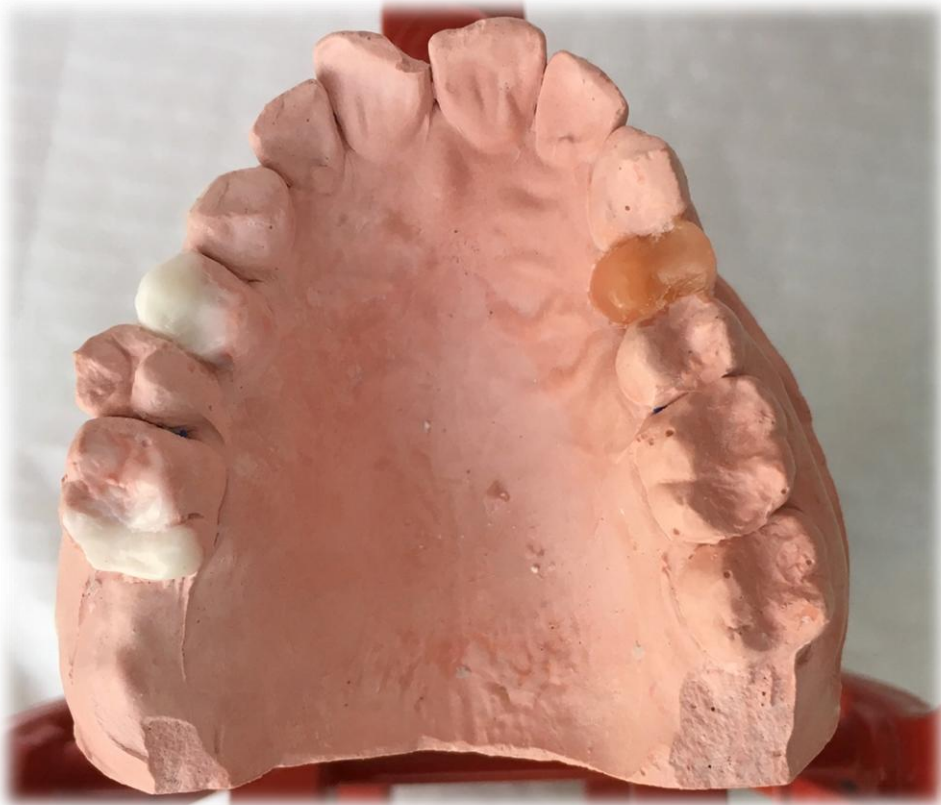Periodontal consultation regarding the status of the canine as an abutment for the bridge

On examination:

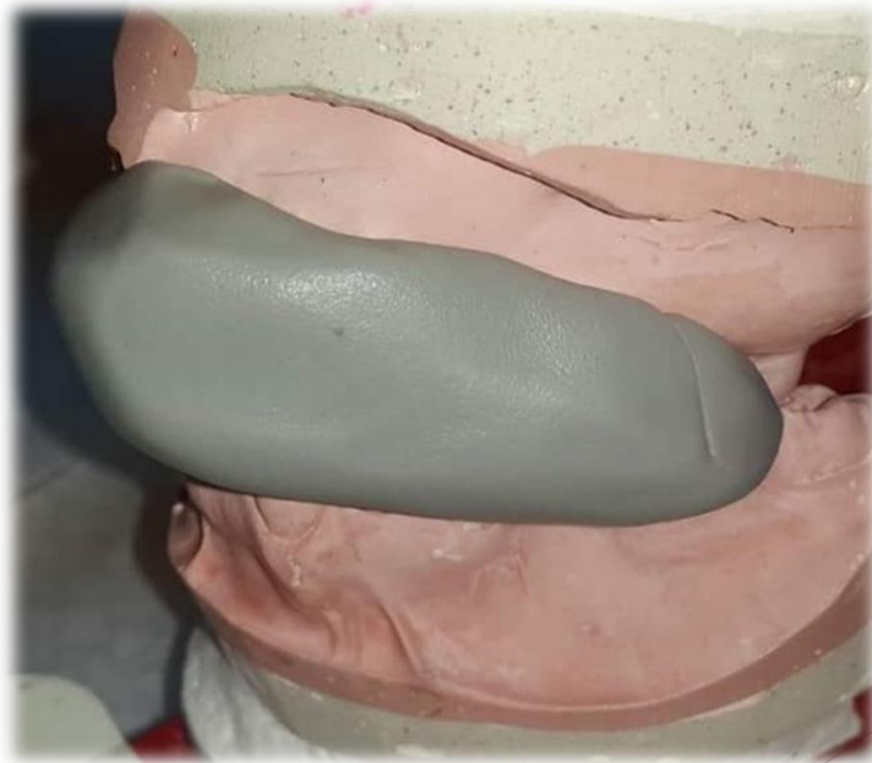- 1) No mobility**
- 2) No clinical attachment loss**
- 3) Normal probing depths**

Conclusion: bone loss due to extraction

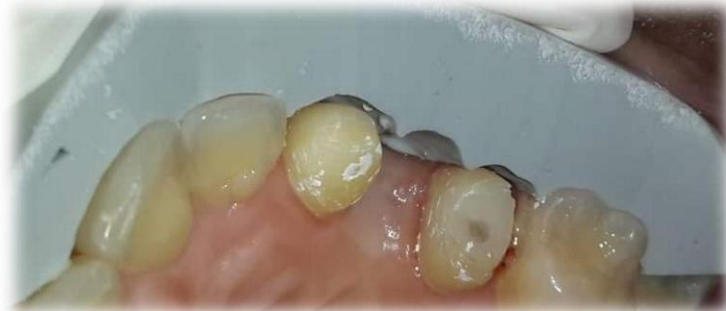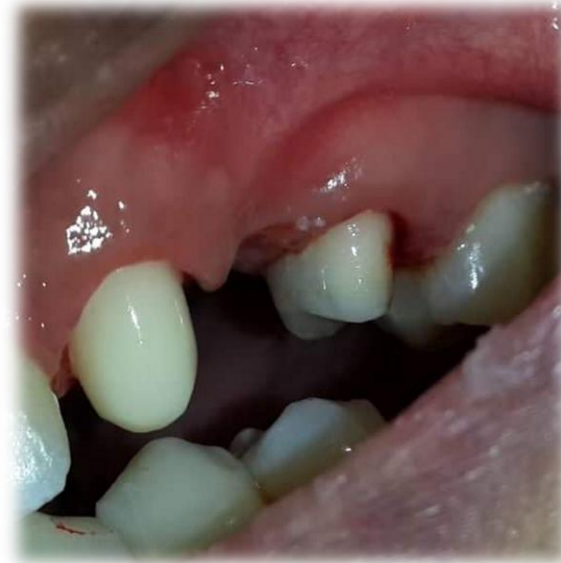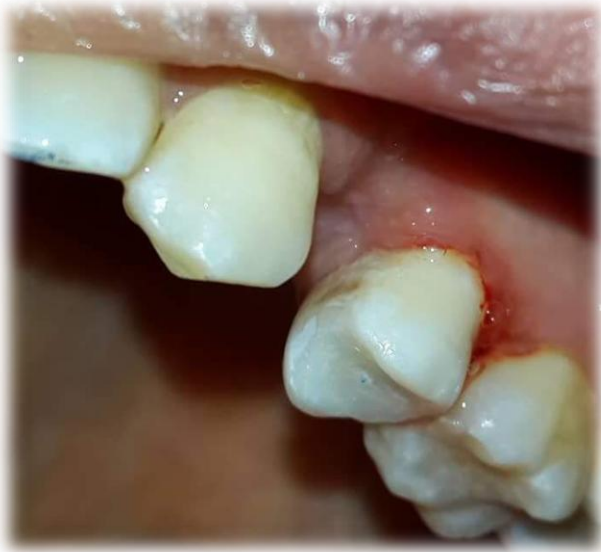Diagnostic wax up



Putty Index



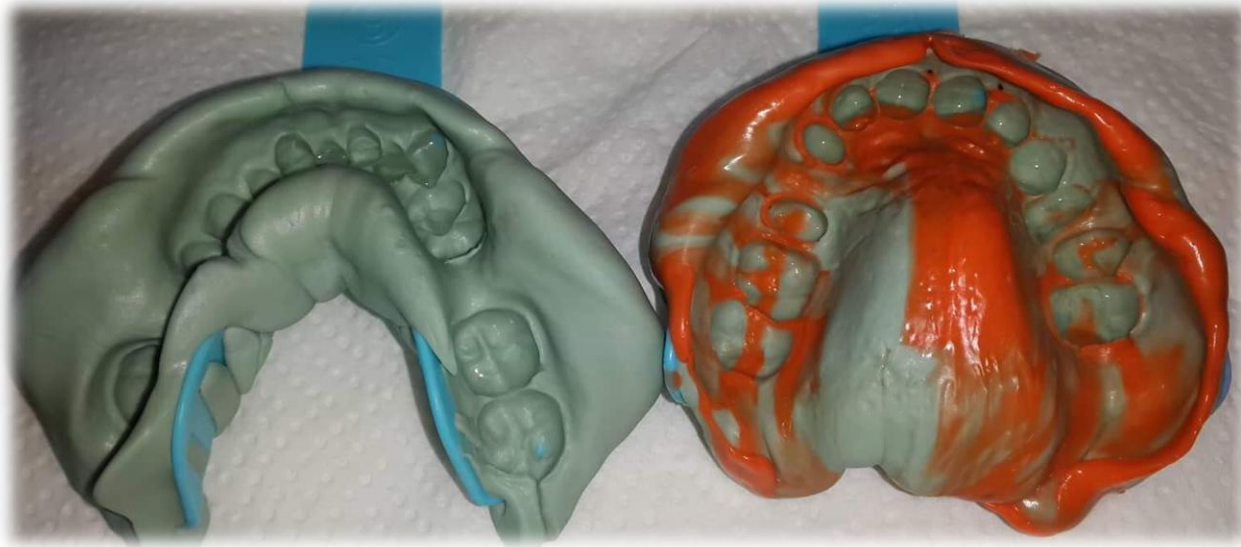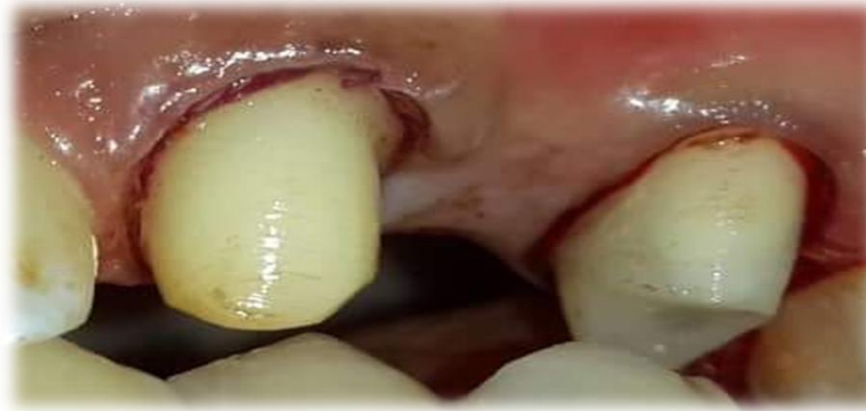Tooth Preparation



Evaluation of the amount of preparation using putty

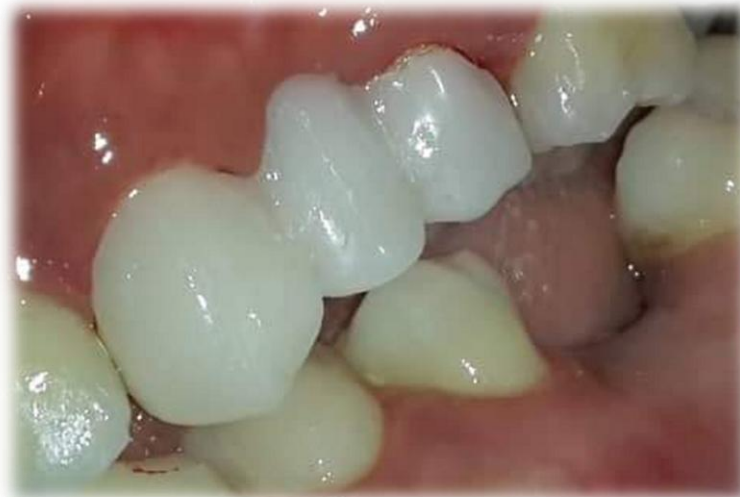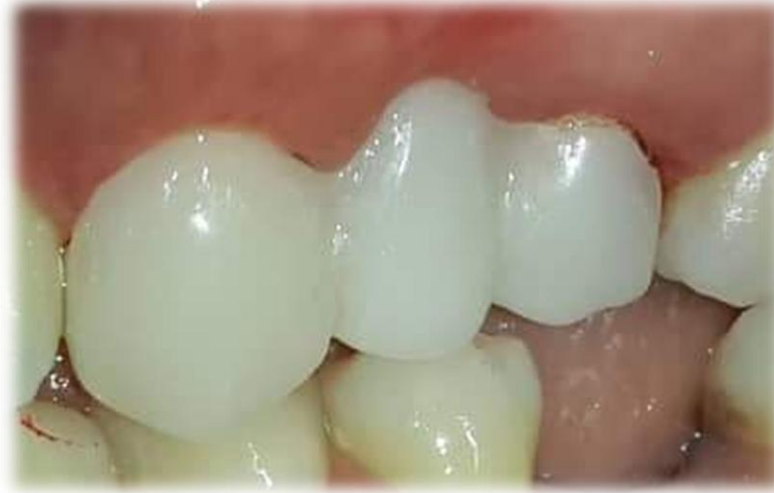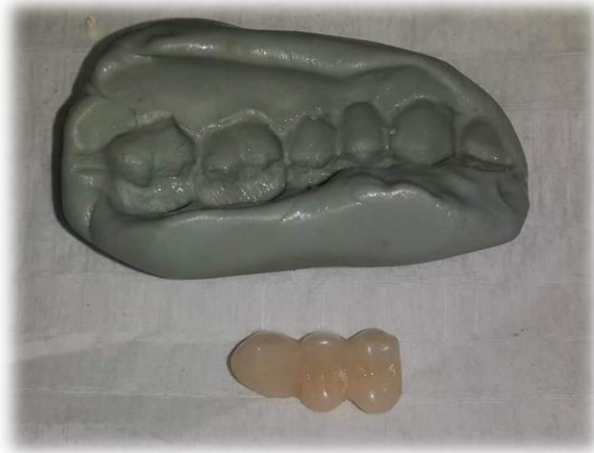Final Impression

Gingival retraction before final impression

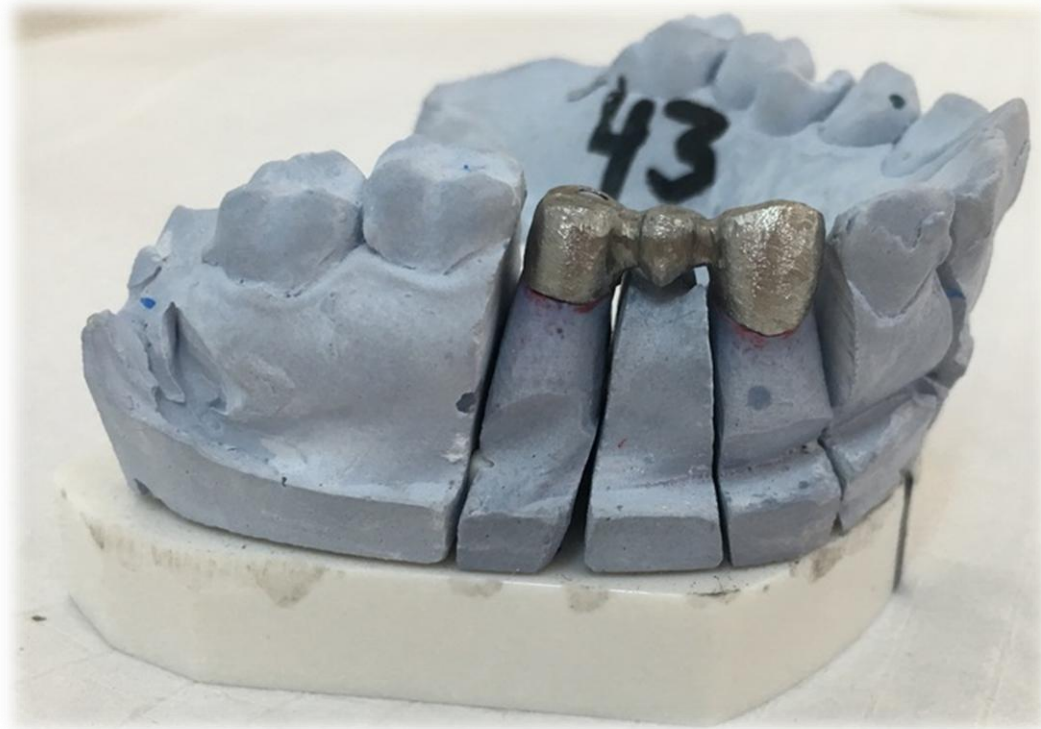

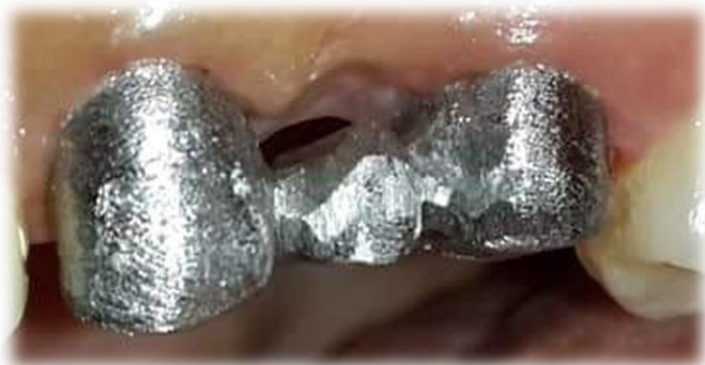Upper final impression and lower impression

Provisional Bridge



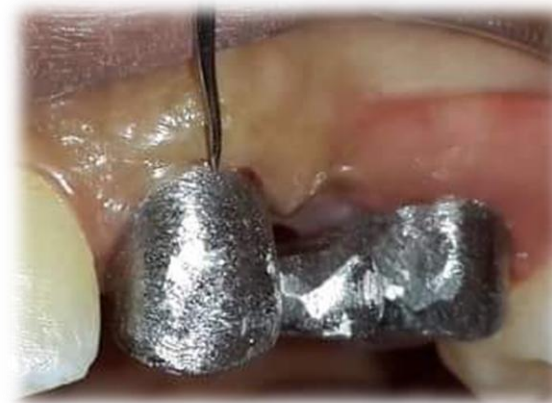Metal Try-in



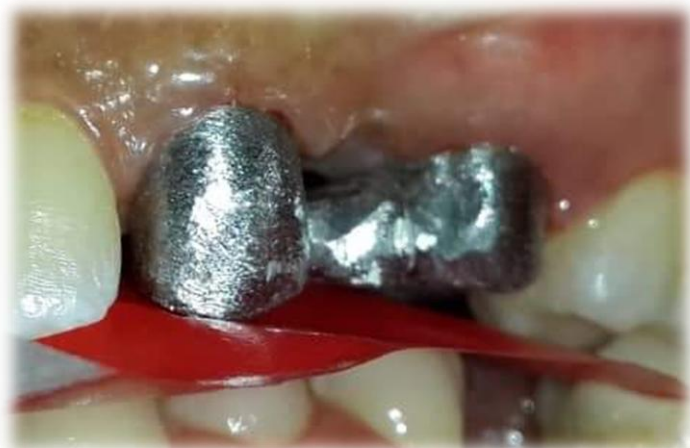

✓ **Complete seating**

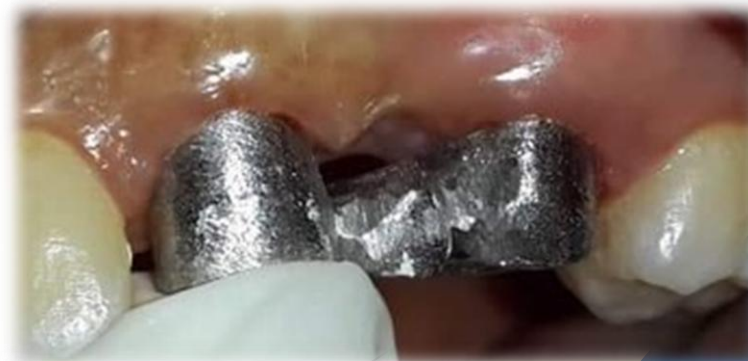✓ **Marginal integrity**



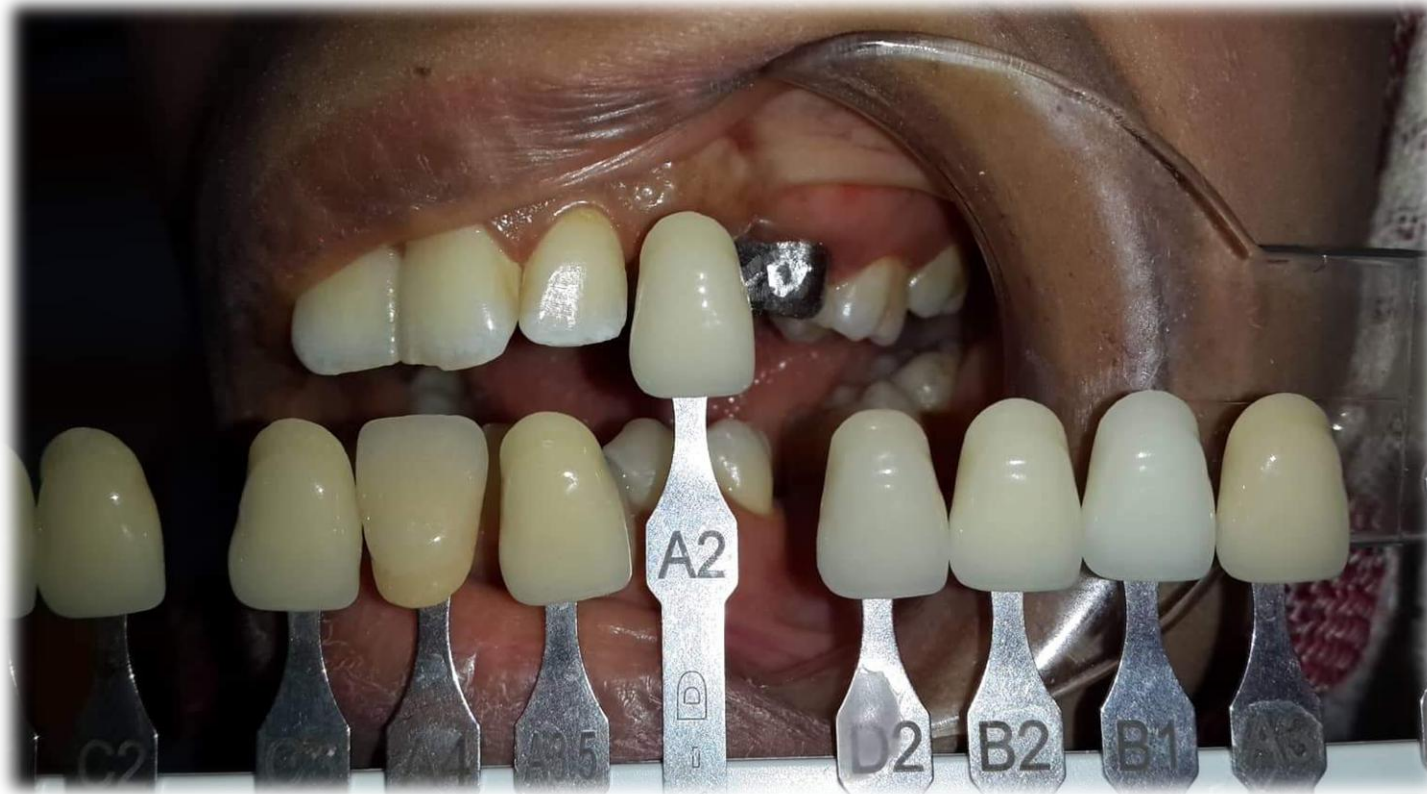✓ **Occlusion**



✓ **Stability**

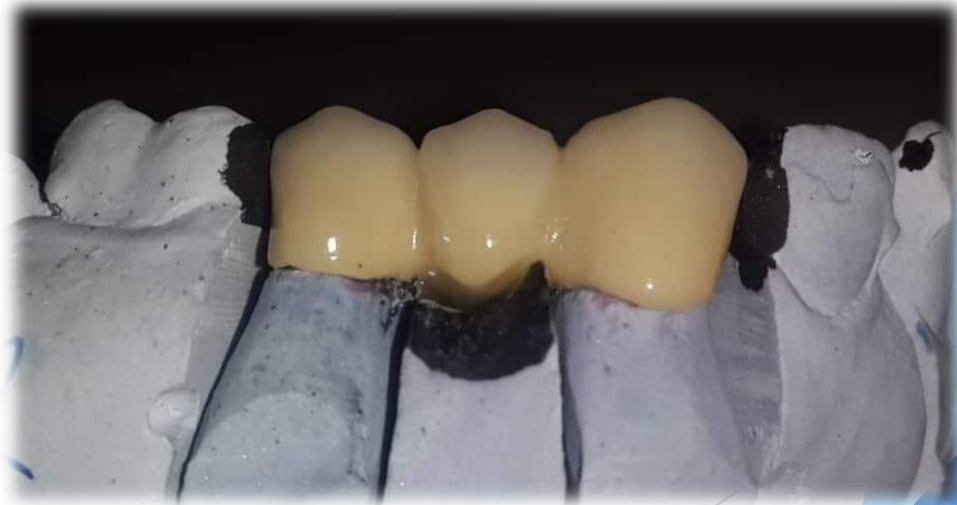
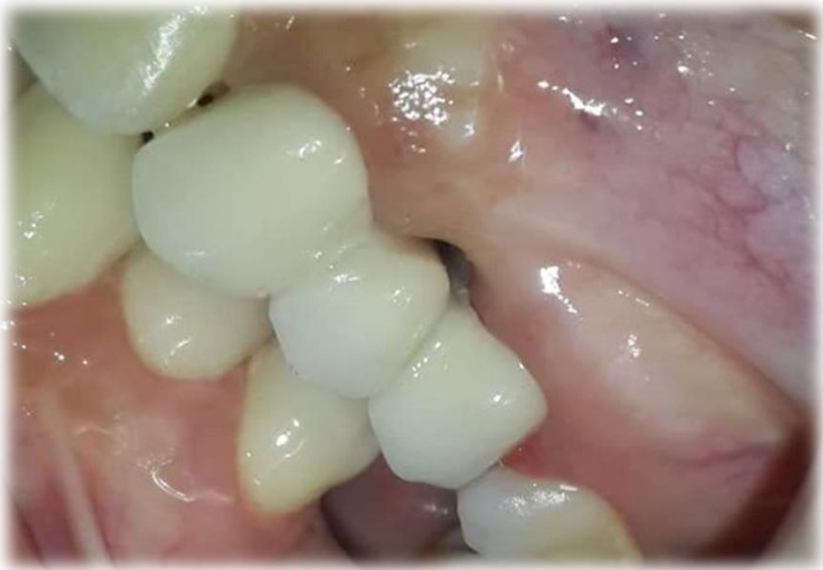
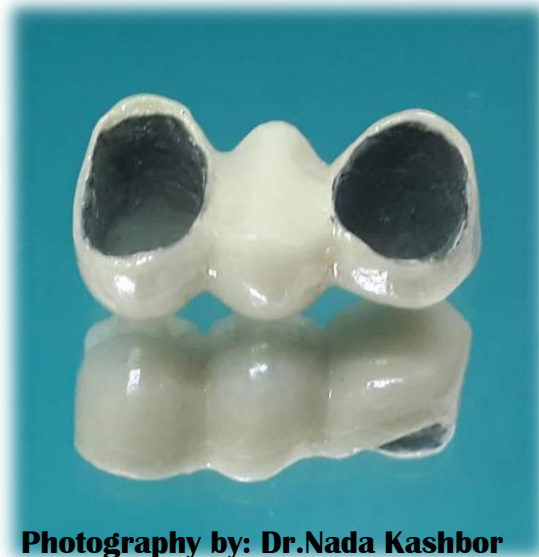
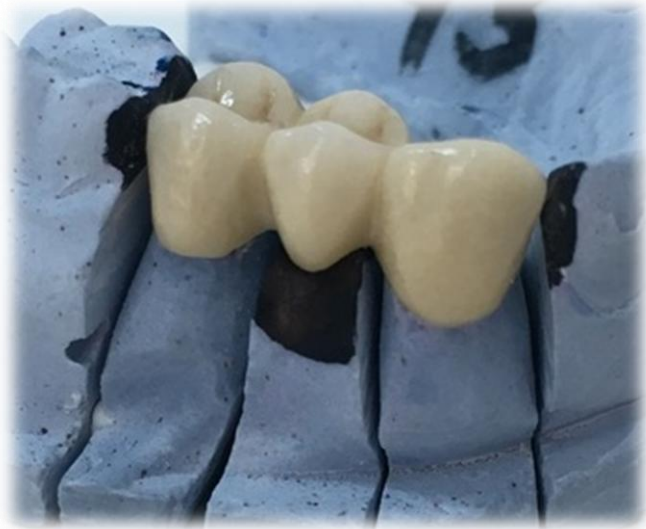Shade Selection



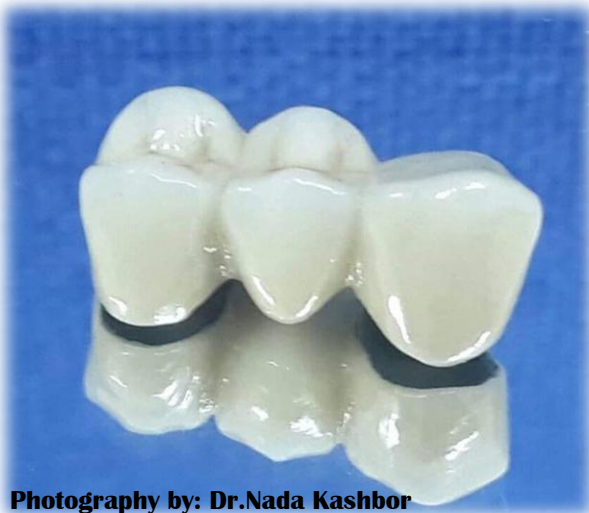Shade: A2

Porcelain Try-in

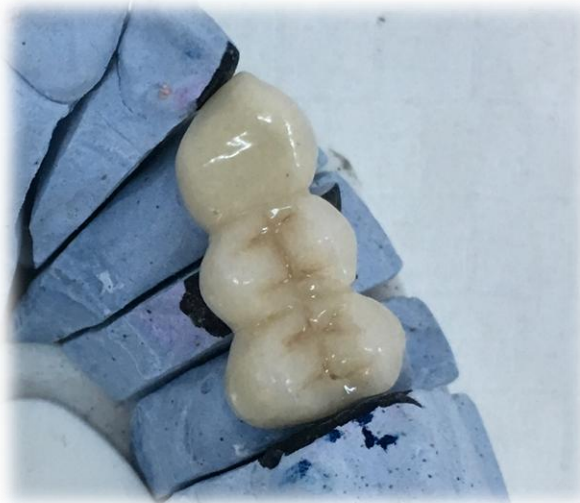




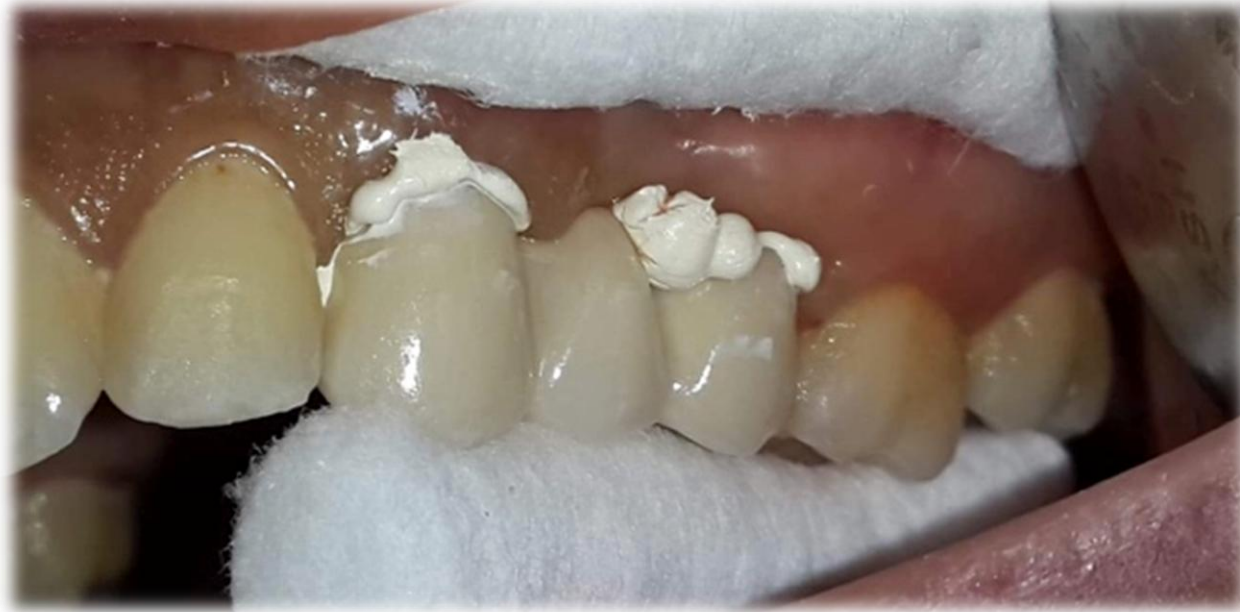Photography by: Dr.Nada Kashbor



Photography by: Dr.Nada Kashbor

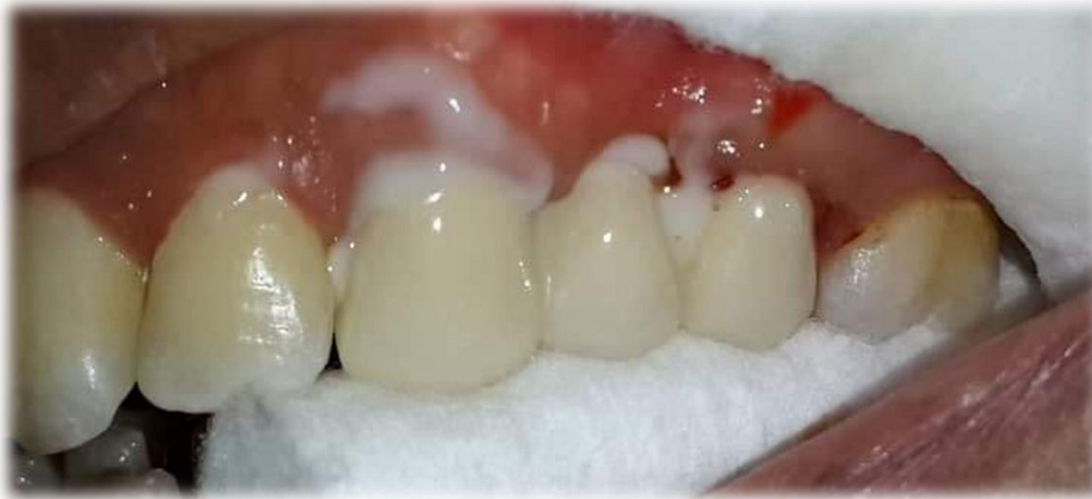

Trial cementation



**Trial cementation using temporary cement
for one week**

Final Cementation



**Final cementation after one week using
Glass-ionomer cement**

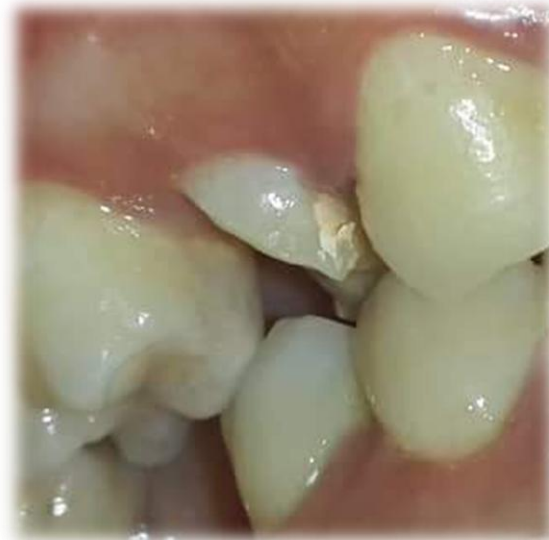Custom-made Post&Core and PFM Crown (14)

Pre-operative evaluation

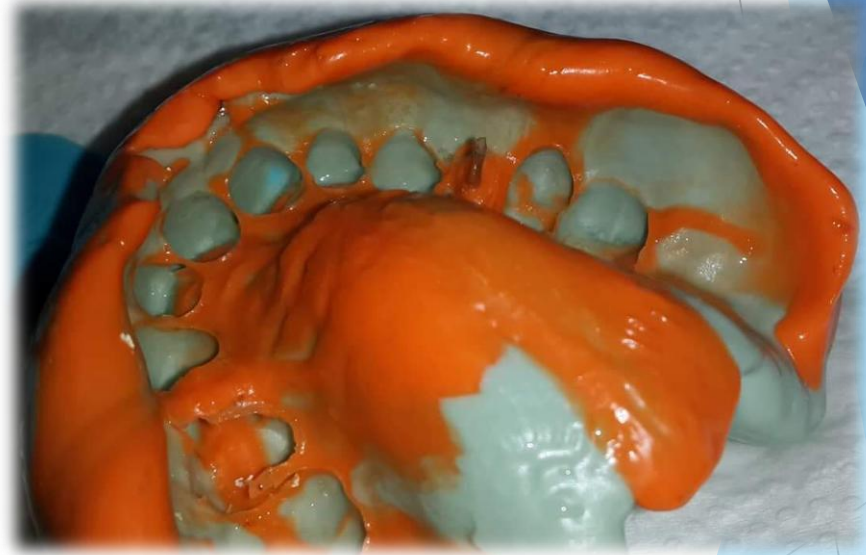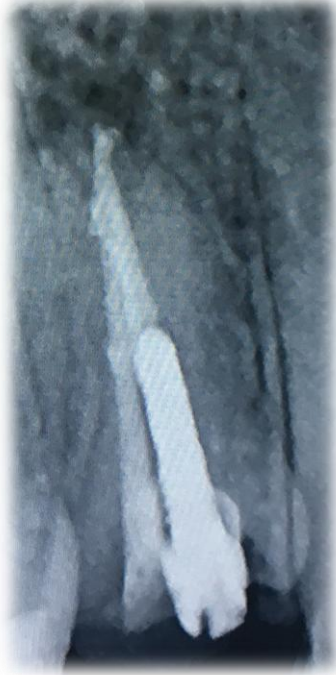
Evaluation of obturation



Pre-operative

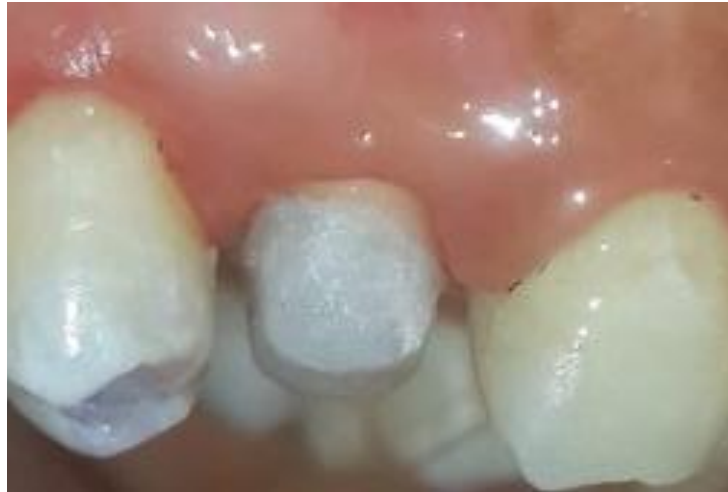
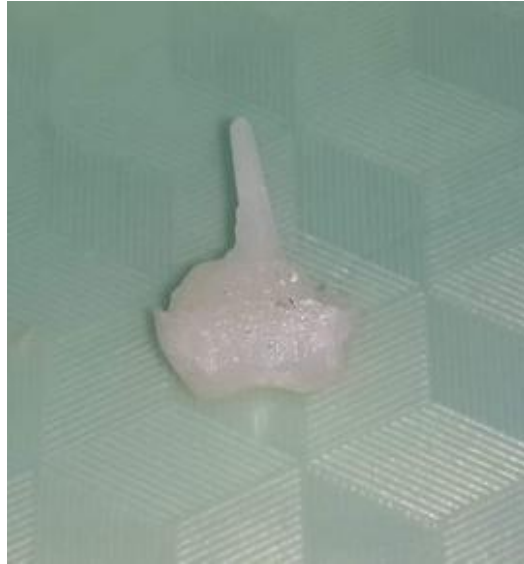
Post-space preparation



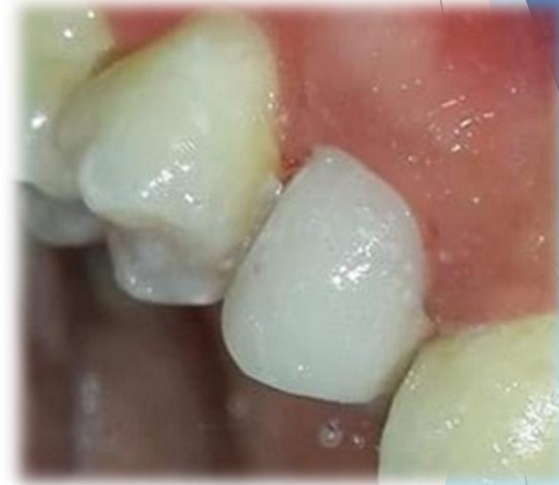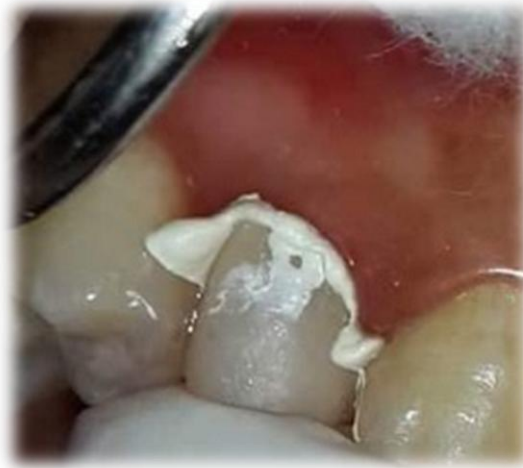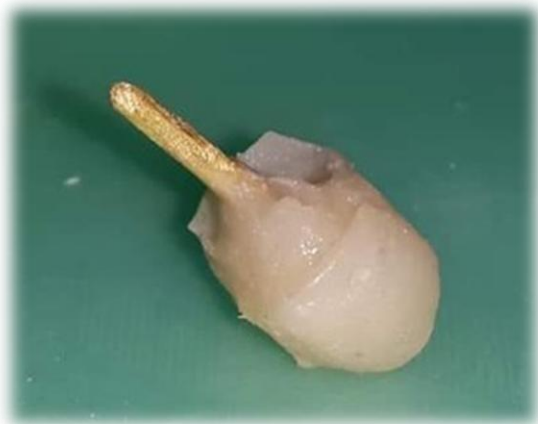Final impression using indirect technique

Direct Technique



Fabrication of custom-made post and core using Self-cure acrylic resin

Provisional Restoration

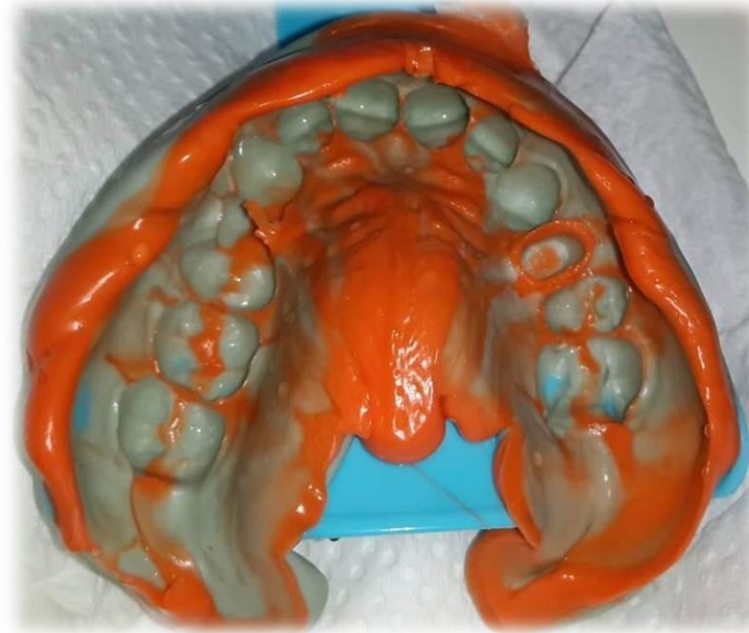
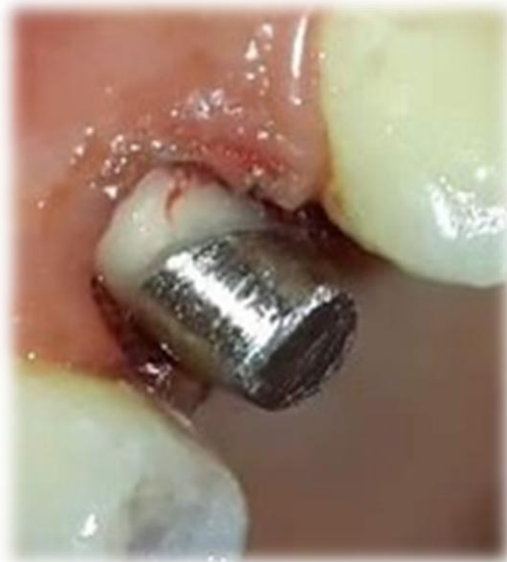
Cementation of post and final impression



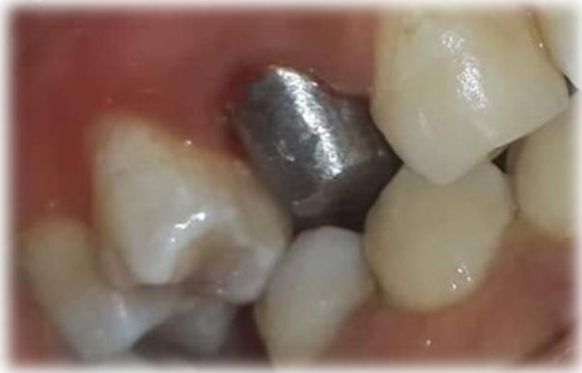Cementation of custom-made cast post and core using adhesive resin cement

Retraction cord

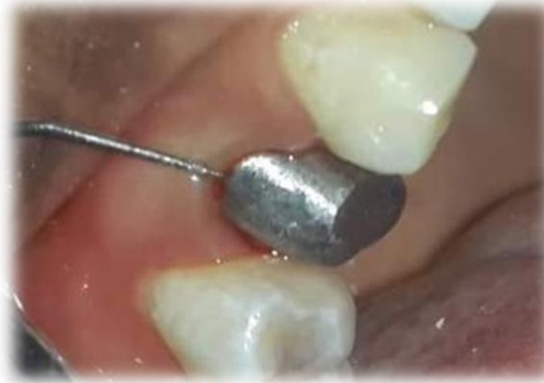

Final impression

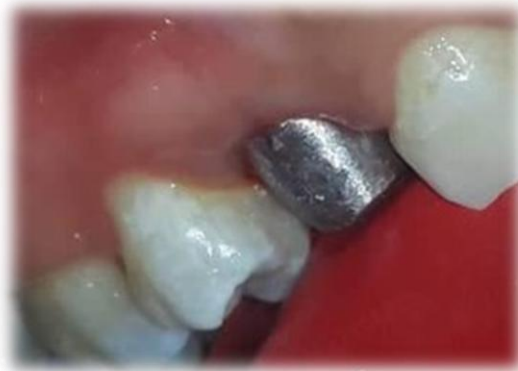Metal try-in



✓ **Complete seating**

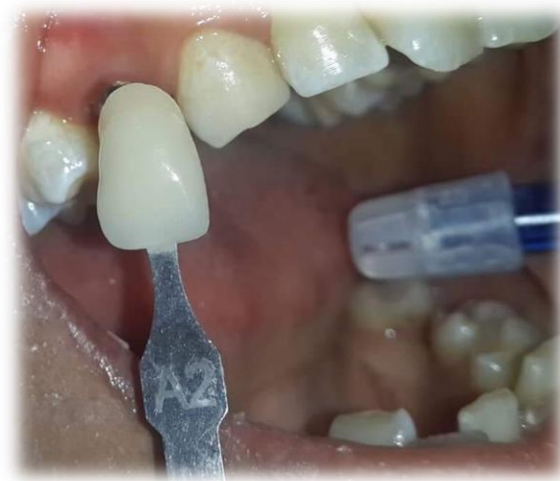

✓ **Marginal Integrity**



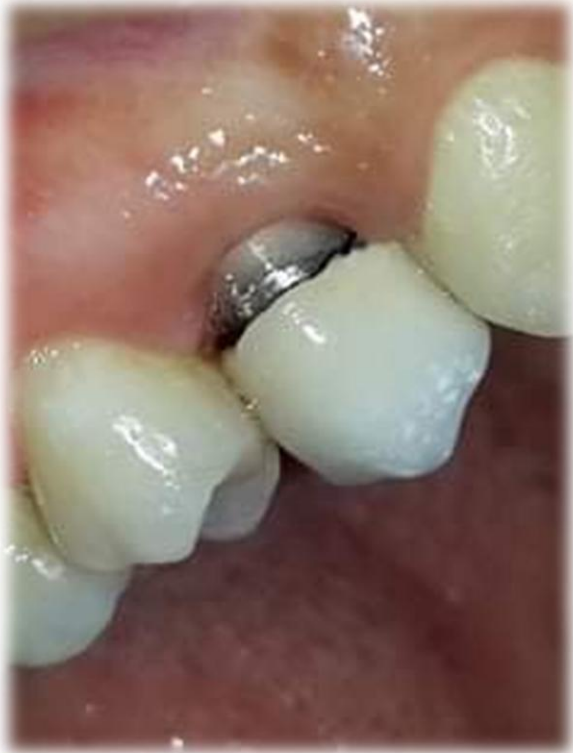✓ **Occlusion**

Shade Selection

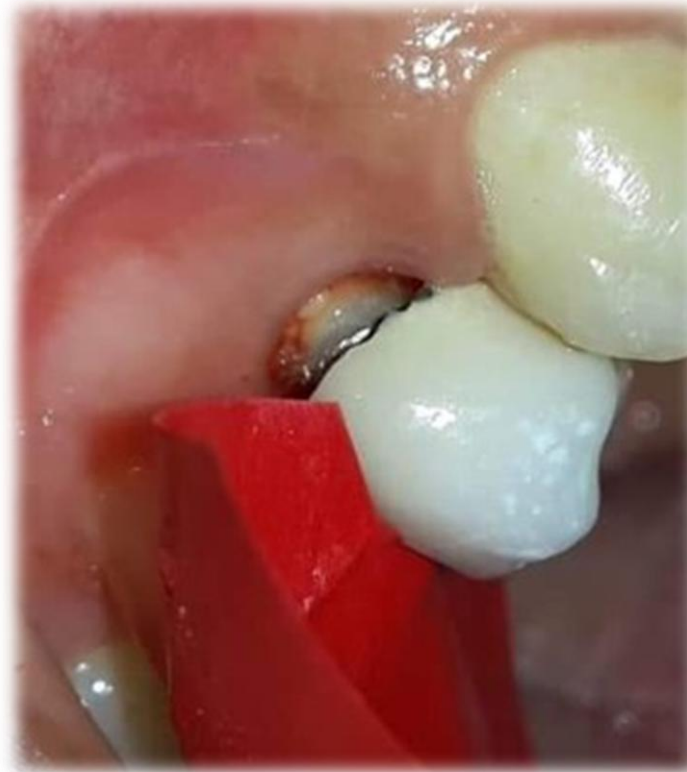

Shade: A2

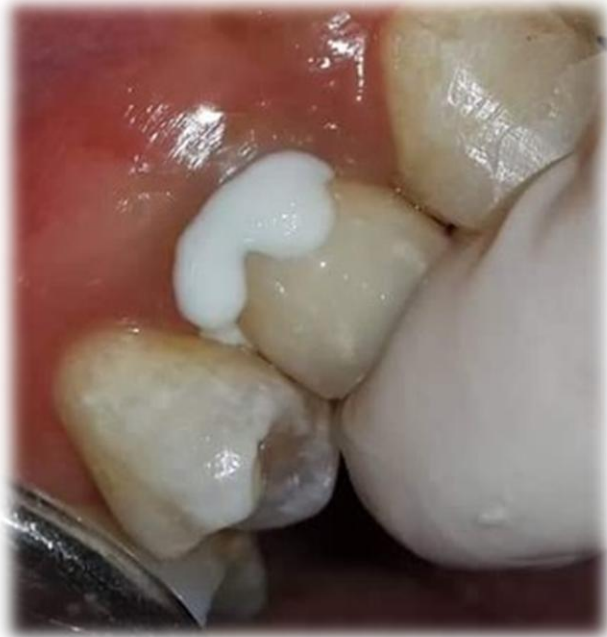Porcelain Try-in



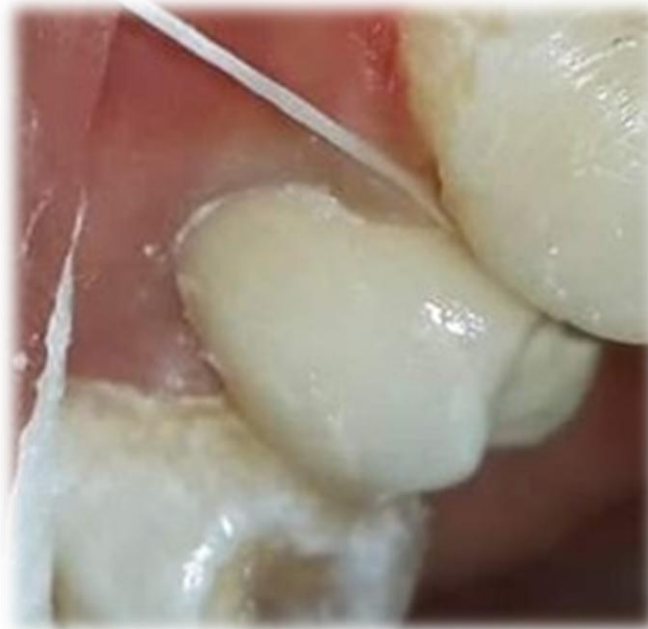- **Incomplete seating of the restoration**



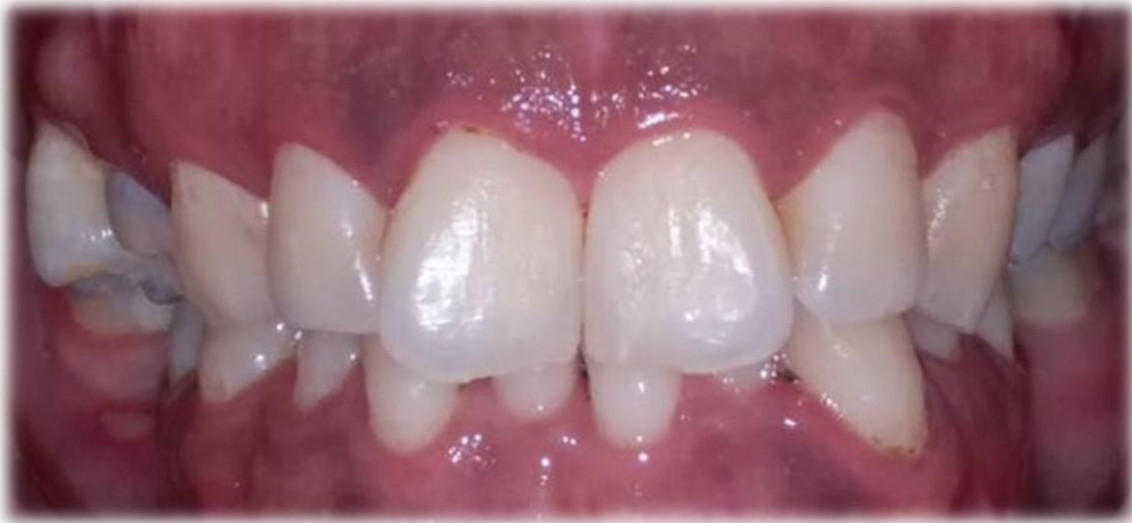Insertion



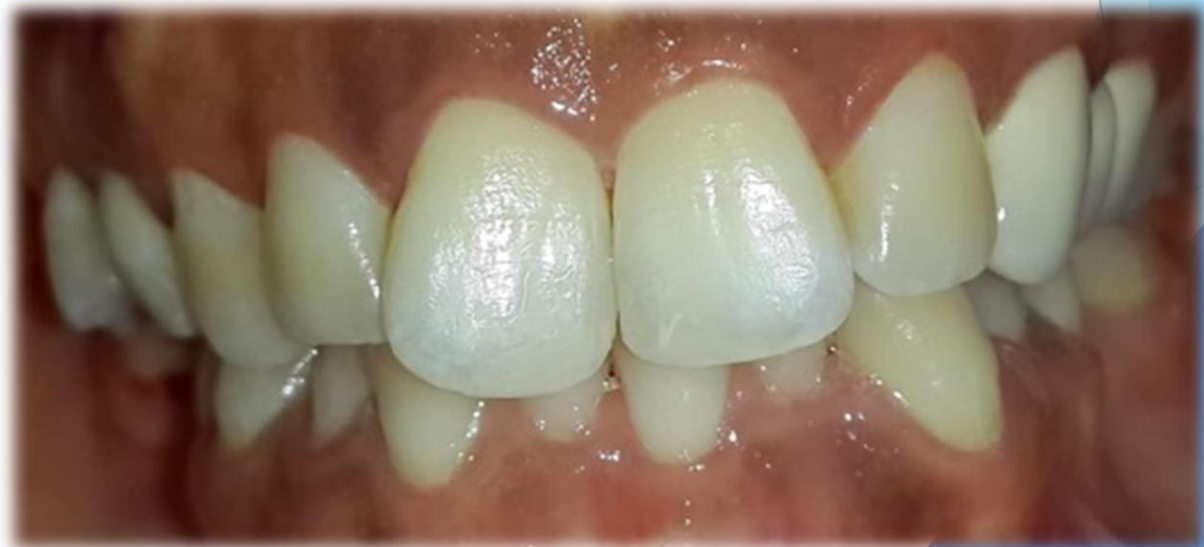**Cementation of PFM crown
using adhesive resin cement**



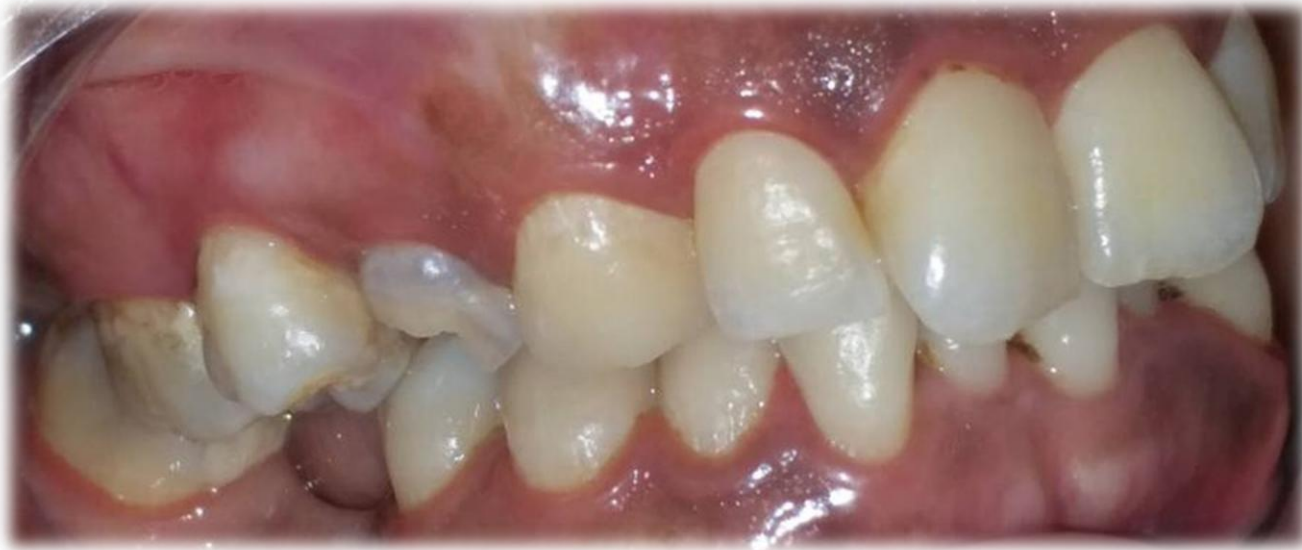Before



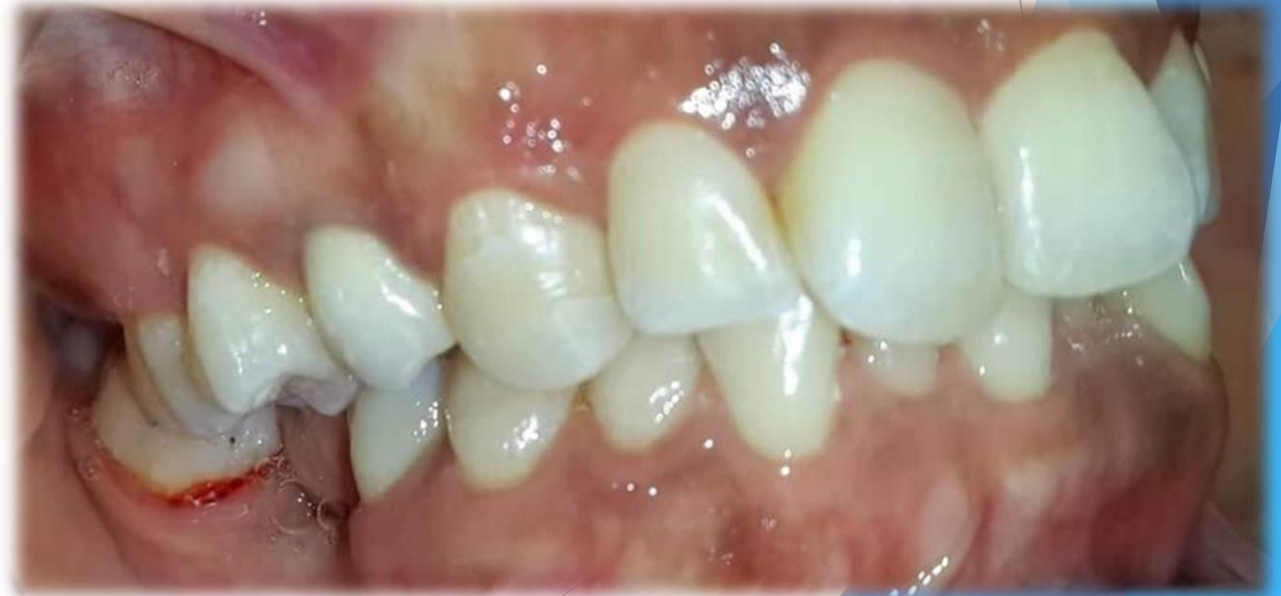After



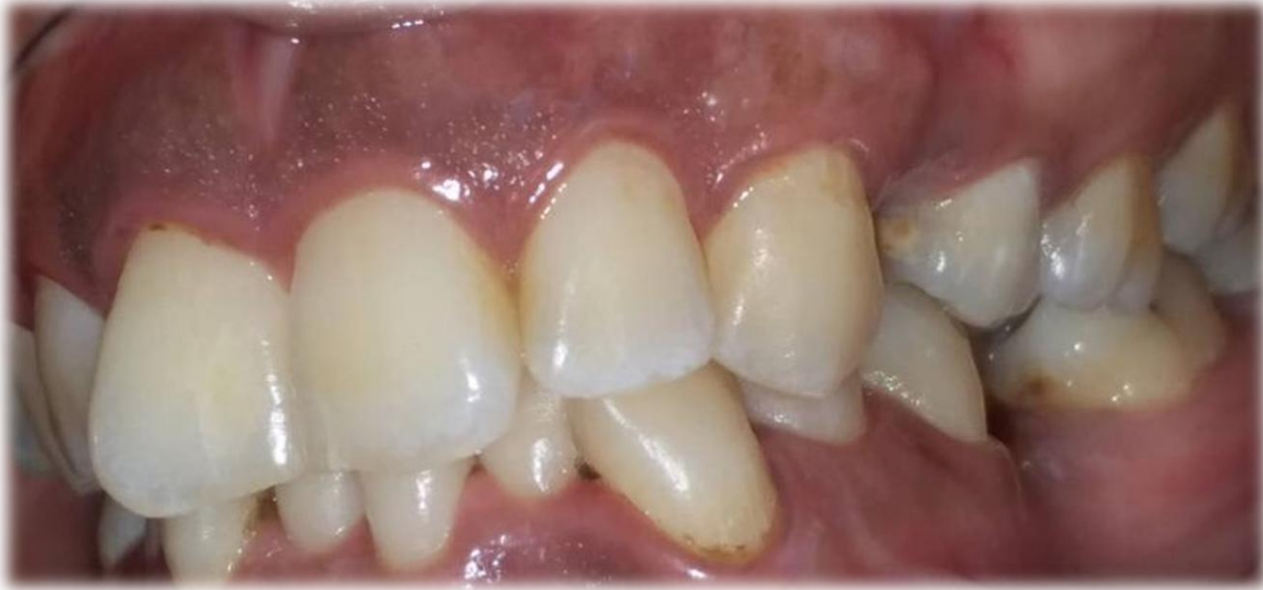Before



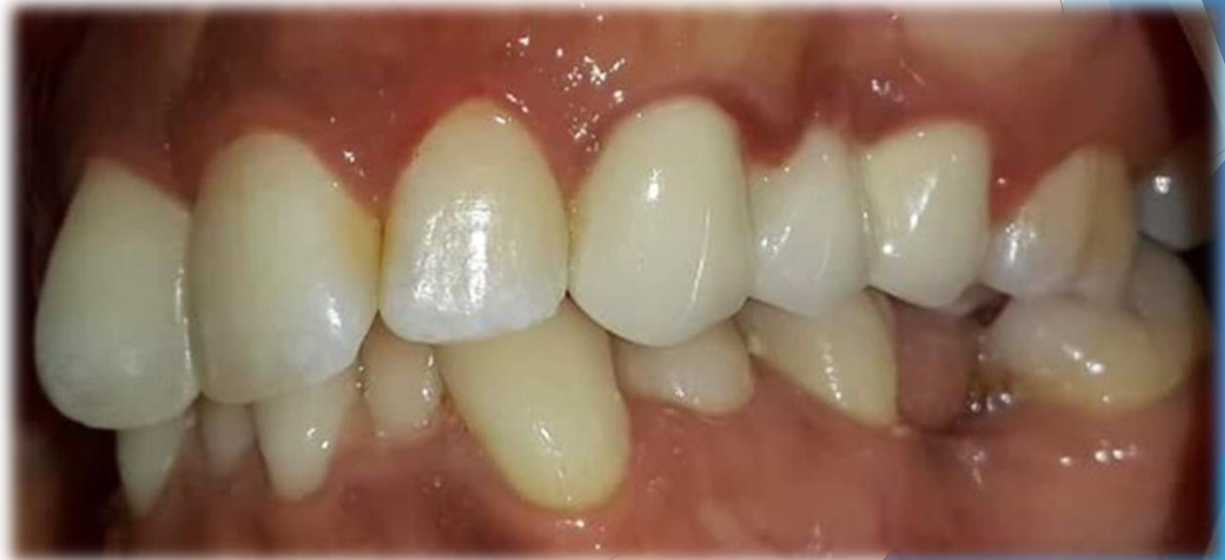After



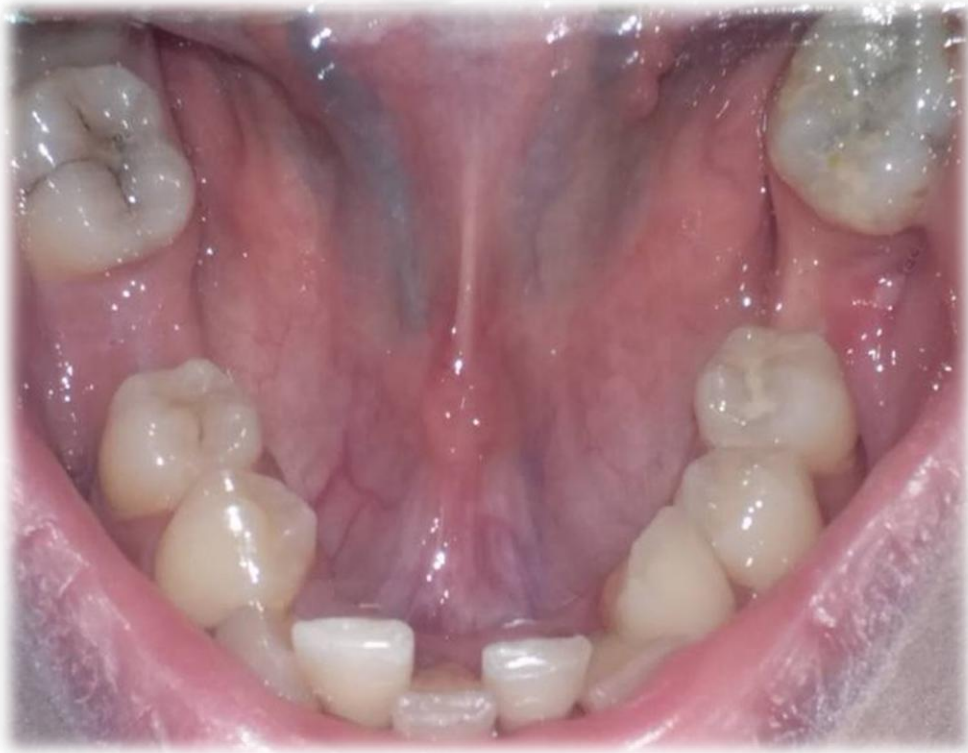Before



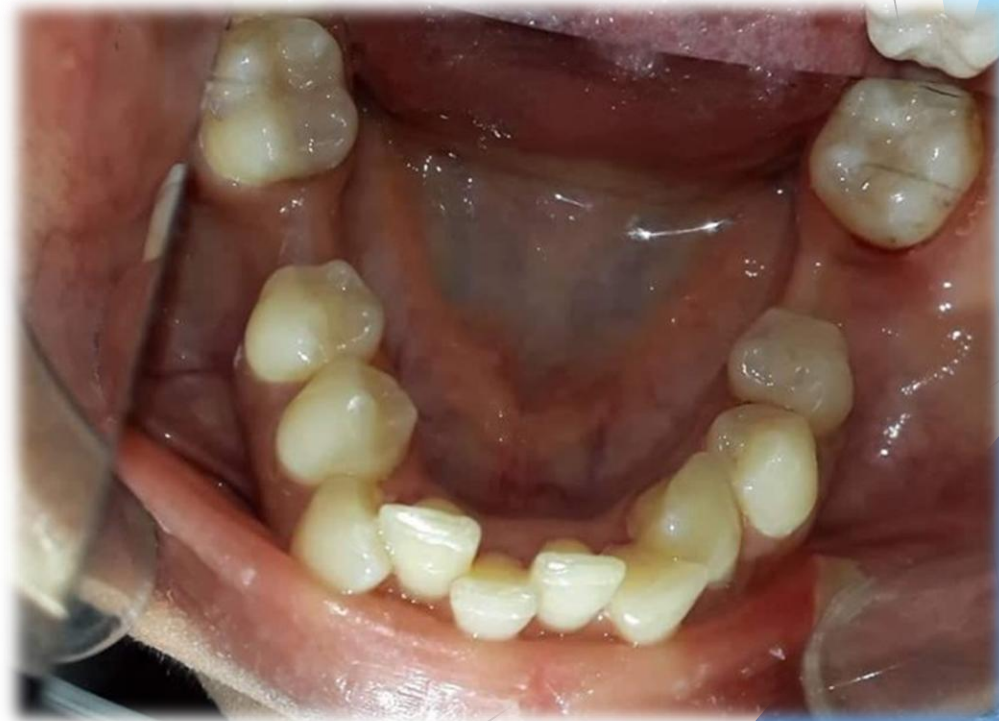After



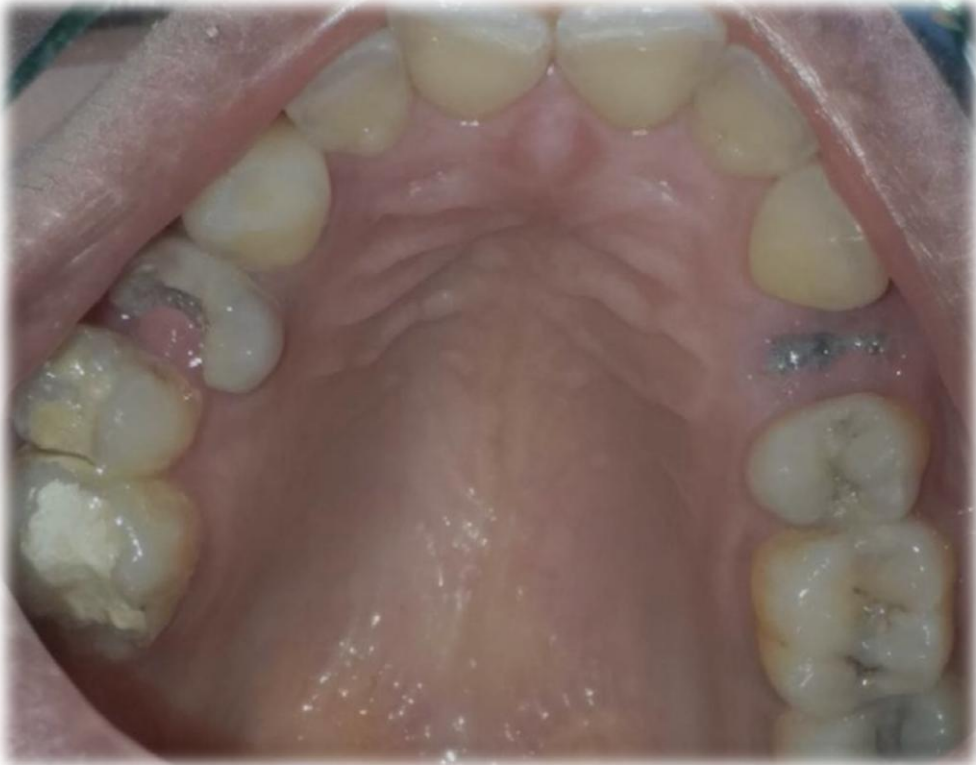Before



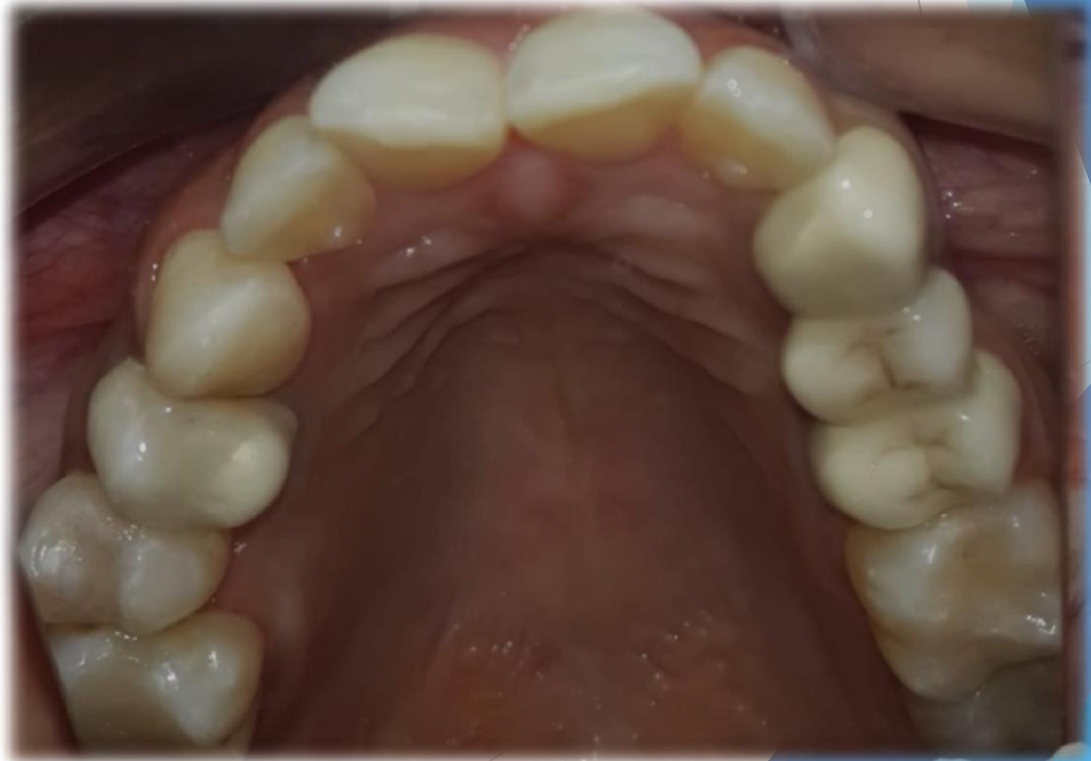After



Before



After



Thank you

The background features abstract, overlapping geometric shapes in various shades of blue, ranging from light sky blue to deep navy blue. These shapes are primarily located on the right side of the frame, creating a modern, layered effect against the white background.